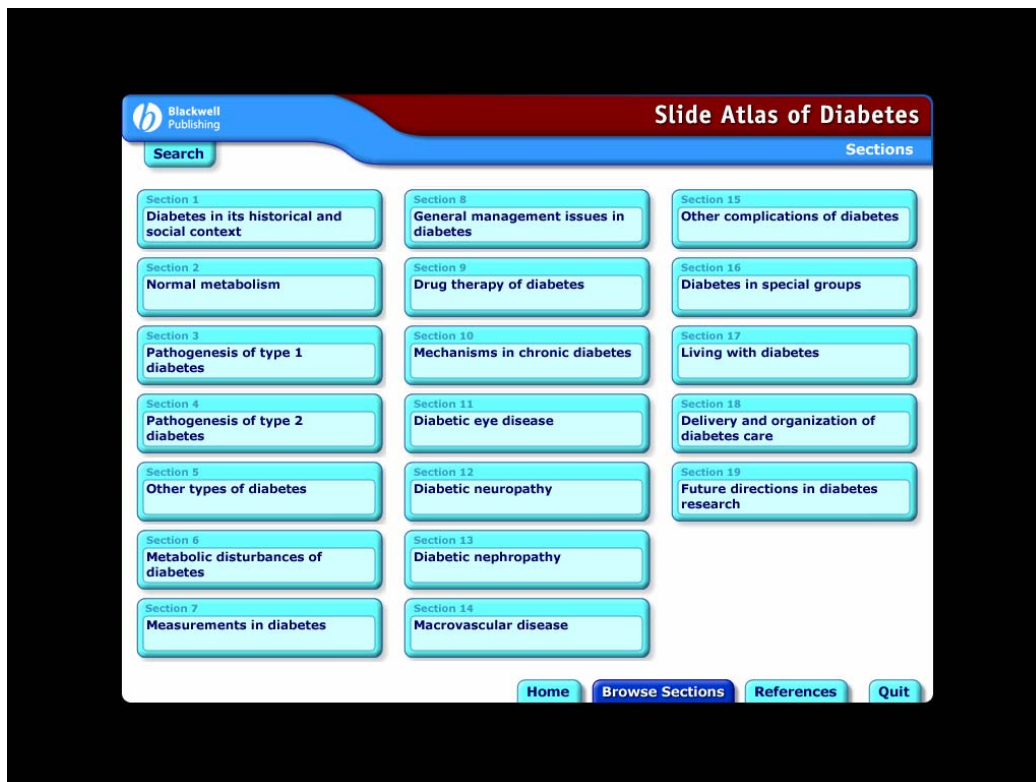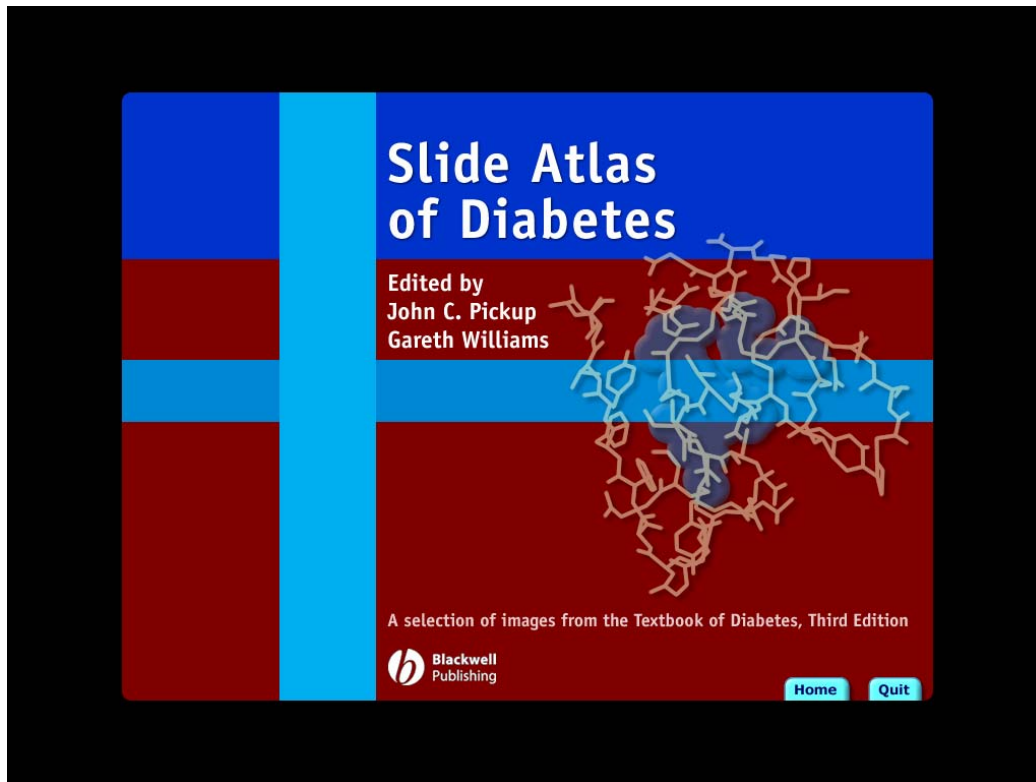


## Sample Screen Shots from the Slide Atlas of Diabetes



Blackwell Publishing

**Slide Atlas of Diabetes**

Other complications of diabetes

Search

- Foot problems in diabetes
- Sexual function in diabetic men and women
- Gastrointestinal disorders in diabetes
- Skin disorders in diabetes
- Rheumatic disorders and bone problems in diabetes mellitus
- The central nervous system and diabetes mellitus
- Psychological factors and diabetes mellitus

- Necrobiosis lipoidica diabetorum
- Histological features of Necrobiosis lipoidica diabetorum: histology
- Diabetic dermopathy
- Diabetic bullae
- Diabetic hand syndrome
- Skin infections in diabetes
- Acanthosis nigricans
- Acanthosis nigricans in insulin resistance
- Eruptive xanthoma
- Necrolytic migratory erythema
- Erythema multiforme

The section of NLD shows degeneration of the collagen ('necrobiosis'), associated with fibrosis and a histiocytic infiltrate. Haematoxylin and eosin stain, original magnification X 40.

View Image

Home Browse Sections References Quit

