

---

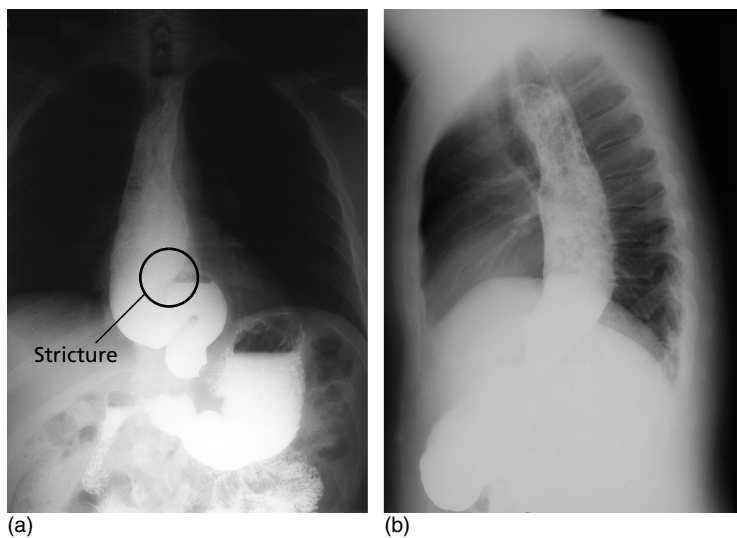
# **CONDITIONS**



- D:** An abscess is a collection of pus walled off by an area of inflammation.
- A:** Pyogenic abscesses are caused by infection that the body's defenses have failed to completely overcome. Common bacteria include *Staphylococcus aureus*, streptococci (especially *S. pyogenes*), enteric organisms (e.g. *Escherichia coli*), other coliforms and anaerobes (e.g. *Bacteroides* spp.). TB classically causes 'cold' abscesses.
- A/R:** **Local:** Tissue necrosis, a closed underperfused space or foreign body that provides a focus for infection, e.g. a tooth or root fragment, splinters, mesh of hernia repairs, embedded hair, malignancy.  
**Systemic:** Diabetes, immunosuppression (although may interfere with pus formation).
- E:** Common in all ages.
- H:** The patient may complain of local effects of pain, swelling, heat, redness and impaired function of the area where the abscess is present (*dolor, tumor, calor, rubor and functio laesa*, respectively, the Celsian features of acute inflammation) and/or systemic effects such as fever and feeling unwell.
- E:** The above features of acute inflammation are evident at the site of the abscess. If present within an organ (e.g. liver or lung, or body cavity), localising signs may be absent, the only sign being a swinging pyrexia (caused by periodic release of microbes or inflammatory mediators into the systemic circulation), which should initiate a search for an infected collection. One old adage is that if pus is somewhere and pus is nowhere, then pus is under the diaphragm (subphrenic abscess).
- P:** Bacteria incite an intense acute inflammatory response with formation of pus, a collection of dead and dying neutrophils, cellular debris and bacteria, if there is resistance to phagocytosis and killing. An abscess forms as it becomes surrounded by a fibrinous exudate and granulation tissue (macrophages and fibroblasts), with subsequent collagen deposition and walling off. Cold abscesses are collections of caseating necrosis containing mycobacterium; 'cold' because there is no associated acute inflammatory response.
- I:** **Bloods:** FBC (↑↑ neutrophils).  
**Imaging:** Ultrasound, CT or MRI scanning, or even <sup>67</sup>Ga white cell scanning may be used in the search for the site of a collection or abscess.  
**Aspiration:** Pus is low in glucose and acidic. Culture of pus for organisms and sensitivity to antibiotics.
- M:** **Prevention:** Prophylactic antibiotics (e.g. during operations), or if given early during an infection. Often not effective once an abscess has formed.  
**General:** Principles involved include drainage of pus, removal of necrotic and foreign material, antimicrobial cover, and correction of the predisposing cause.  
**Surgery:** Drainage of pus is carried out by incision and drainage, with debridement of the cavity and subsequent free drainage by packing of the cavity (if superficial) or by drains (if deep).  
**Interventional radiology:** Ultrasound or CT guidance can be used to localise and aspirate the contents of an abscess.
- C:** Spread may result in cellulitis (in skin) or bacteraemia with systemic sepsis. If the focus of infection is not removed, a chronic abscess or discharging sinus or fistula may form. Occasionally, antibiotics may penetrate and result in the formation of a sterile collection or antibiome. If constrained by strong facial planes, slow expansion can cause pressure necrosis of surrounding tissues.
- P:** Good if adequately drained and predisposing factor removed. If left untreated, abscesses tend to 'point' to the nearest epithelial surface and may spontaneously discharge their contents. Deep abscesses may become chronic, undergoing dystrophic calcification.

## Achalasia

- D:** A motor disorder of the oesophagus with aperistalsis and failure of lower oesophageal sphincter relaxation while swallowing.
- A:** Degeneration of ganglionic cells of myenteric plexus of the oesophageal sphincter disrupts the peristaltic coordination. Cause of the degeneration is unknown. Infection with *Trypanosome cruzi* may produce a similar syndrome, but this is only common in South America.
- A/R:** Rare association with alacrimation and Addison's disease (Triple A syndrome).
- E:** Annual UK incidence is 1/100 000. All age groups but rare in childhood.
- H:** Intermittent dysphagia involving solids and liquids, food may be regurgitated (particularly at night), atypical/cramping retrosternal chest pain, weight loss.
- E:** Look for signs of complications.
- P:** **Micro:** Degeneration of intramural ganglionic cells of the myenteric plexus at the oesophageal sphincter. Degeneration of dorsal vagal nucleus in the brain-stem medulla may also be seen.  
**Macro:** Oesophagus can become severely dilated and elongated (see Figs 1a & 1b).
- I:** **CXR:** May show dilated oesophagus (double right heart border) and fluid level behind heart shadow.  
**Barium swallow:** Dilated body of oesophagus, which smoothly tapers down to the sphincter (beak-shaped), lack of peristalsis.  
**Oesophagoscopy:** Excludes malignancy.  
**Manometry:** Oesophageal and sphincter pressures. Abnormal sphincter-resting pressure is > 30 mmHg.  
**Bloods:** Exclude Chagas' disease (serology for antibodies against *Trypanosome cruzi*), blood film might detect parasites.
- M:** **Medical:** Nifedipine or verapamil (calcium channel antagonists) or isosorbide mononitrate as needed (for short-term relief). Endoscopic balloon dilatation of lower oesophageal sphincter (80% success rate, but small risk of perforation). Endoscopic injection of botulinum toxin may be promising.  
**Surgery:** Heller's cardiomyotomy of lower oesophageal sphincter via an abdominal or thoracic approach to relieve obstruction. This can cause future reflux oesophagitis, so it may be combined with a fundoplication procedure.
- C:** If untreated, aspiration pneumonia, malnutrition and weight loss may result. 5% risk of oesophageal malignancy regardless of treatment (on average ~25 years after diagnosis).
- P:** Good if treated. If untreated, oesophageal dilation worsens, causing pressure on mediastinal structures.



**Fig. 1** Achalasia: (a) AP; (b) lateral – food particles in the oesophagus.

## Acoustic neuroma

- D:** Benign fibroma of the vestibulocochlear (VIII) nerve sheath. Schwannomas are often included as well.
- A:** The vestibulocochlear (VIII) cranial nerve sheath develops a space-occupying fibroma expanding out of the internal acoustic meatus into the cerebellopontine angle, causing compression of structures (other cranial roots and brainstem) in that region.
- A/R:** In type II neurofibromatosis, bilateral acoustic neuromas are associated with meningiomas, gliomas, peripheral and spinal schwannomas. There have been reports of acoustic neuroma associated with acoustic trauma, e.g. chronic exposure to loud noise.
- E:** Incidence is 1/100 000 per year. Occurs at all ages, more common in 40–50 years (unilateral) or 20–30 years (bilateral). Female > male. Represents 8% of all intracranial tumours in adults and 80–90% of cerebellopontine angle tumours.
- H:** Unilateral hearing loss, vertigo.
- E:** Progressive unilateral sensorineural hearing loss.  
Nystagmus to the side opposite to tumour.  
Larger tumours compress trigeminal (V) nerve (unilateral facial numbness), and then facial (VII) nerve (unilateral LMN facial palsy).  
Look for neurofibromas at other sites.
- P:** Fibromas and schwannomas are the commonest growths, virtually always benign but local growth can cause serious consequences.
- I:** **Auditory evoked potentials:** This will show waveform delays, excluding lesions in the cochlea or the ear.  
**MRI:** This will show the size and extent of the tumour. Gadolinium enhancement is particularly helpful to highlight the tumour clearly.
- M:** **Medical:** None.  
**Surgical:** Curative treatment; however, hearing is often permanently impaired. Morbidity depends on size of tumour. Radiosurgery (stereotactic radiotherapy) may be considered for neuromas < 3 cm and in patients unfit for conventional surgery.  
**Advice:** Patients with bilateral tumours need to learn how to lip-read and use sign language, and should start practising before curative surgery is attempted.
- C:** Progressive compression of brainstem, pyramidal tracts and the fourth ventricle can result from large tumours (presenting with bulbar cranial nerve palsies, reversal of the nystagmus, ipsilateral ataxia, obstruction at the level of the fourth ventricle, hydrocephalus, ↑ ICP, occipital headaches).
- P:** Hearing loss is often permanent. Treatment merely prevents further damage.

## Amputation, Above knee

7

CONDITIONS

- I:** **Ischaemia, infarction or gangrene:** Acute or chronic lower limb ischaemia or caused by severe trauma or burns.  
**Malignancy:** Certain tumours (e.g. osteosarcoma, malignant melanoma).  
**Severe infection:** Gas gangrene (*Clostridium perfringens*) or necrotising fasciitis.  
**Rare:** Intractable ulceration or painful paralysed limbs.
- A:** **Above-knee amputation (AKA):** At the level of 15 cm above the tibial plateau is optimal.  
**Through-knee amputation:** Sometimes indicated (e.g. if there has been prior orthopaedic fixation of femur), but the disadvantage is unpredictable healing of skin flaps and a bulbous stump with difficult prosthesis fitting.  
**Gritti-Stokes amputation:** Involves femur division at the supracondylar level, leaving a longer stump than AKA and ↑ stability for the patient while sitting.  
**Others** (e.g. disarticulation of hip, hindquarter amputation): These are rarely performed, and mainly for severe infection or malignancy.
- I:** **Pre-op:** Ideally, multidisciplinary assessment including surgical, anaesthetic, prosthetic specialists. Assessment of the level of amputation given severity of disease and patient factors (e.g. rehabilitation prospects). Insulin sliding scale if diabetic, appropriate blood tests and crossmatch blood, urinary catheterisation if appropriate.  
**Post-op:** DVT prophylaxis. Rehabilitation with early physiotherapy, early walking aids (e.g. pneumatic post-amputation mobility aid) or prosthesis fitting.
- P:** Only AKA is discussed.  
**Access:** Two equal fish mouth-shaped skin flaps are marked on the skin, with their upper ends at the level of femur transaction. This is 15 cm above the tibial plateau.  
**Muscle and vessel ligation:** During skin incision, the long saphenous vein is ligated and the muscles of the anterior and posterior thigh compartments divided by diathermy. Vastus lateralis is sutured to the adductors, and quadriceps to the hamstrings. Arteries and veins are ligated and nerves divided cleanly under gentle traction.  
**Bone amputation:** The femur is stripped of periosteum and divided, with filing of bone ends to create a smooth surface.  
**Closure:** Once haemostasis is achieved, the two myoplastic flaps are brought together and the skin closed with interrupted sutures. A suction vacuum drain may be left in situ.
- C:** **Early:** Pain, DVT, flap ischaemia, stump haematoma, neuroma or infection, stump length too long or short, bony spurs, psychological problems.  
**Late:** 'Phantom' limb pain (reduced by strong analgesia post-op), neuroma formation, erosion of bone through skin, ischaemia, osteomyelitis, ulceration.  
 For diagrammatic review on general amputations see Figs 2a & 2c.

## Amputation, Below knee

- I:** **Ischaemia, infarction or gangrene:** Acute or chronic lower limb ischaemia or caused by severe trauma or burns.  
**Malignancy:** Certain tumours (e.g. osteosarcoma, malignant melanoma).  
**Severe infection:** Gas gangrene (*Clostridium perfringens*) or necrotising fasciitis.  
**Rare:** Intractable ulceration or painful paralysed limbs.
- A:** **Below-knee:** Two techniques for transtibial amputation: Burgess long posterior flap and Robinson's skew flap techniques.  
**Ankle level:** Seldom performed due to difficulty attaching prosthesis.  
**Midfoot:** Lisfranc's involving disarticulation between tarsal and metatarsal bones or Chopart's disarticulation of the talonavicular and calcaneocuboid joints.  
**Ray:** Involves excision of a toe by division through the metatarsal bone.  
**Toe:** Division is through the proximal phalanx, as cutting through a joint exposes avascular cartilage that does not heal well.
- I:** **Pre-op:** Ideally, multidisciplinary assessment including surgical, anaesthetic, prosthetic specialists, physiotherapists, psychologists, etc. Assessment of the level of amputation given, severity of disease and patient factors (e.g. rehabilitation prospects). Insulin sliding scale if diabetic, appropriate blood tests and crossmatch blood, urinary catheterisation if appropriate.  
**Post-op:** DVT prophylaxis. Rehabilitation with early physiotherapy, early walking aids (e.g. pneumatic post-amputation mobility aid), prosthesis fitting.
- P:** Only below-knee amputation is discussed.  
**Access:** Skin flaps are marked on the skin prior to incision with a longer posterior flap (Burgess) or skew anteromedial and posterolateral flaps. The level of tibial transaction is 14 cm below knee joint or 10–12 cm below tibial tuberosity.  
**Ligation of muscle and vessels:** During skin incision the long saphenous vein is ligated and the muscle of the anterior and peroneal compartments divided by diathermy. Arteries and veins are ligated and, following diathermy of accompanying vasa nervorum, the tibial nerve divided cleanly under gentle traction. This incision is extended posteriorly and distally.  
**Bone amputation:** The fibula is divided 2 cm proximally following stripping of periosteum. The tibia is also stripped and divided, with filing of bone ends to a smooth surface.  
**Closure:** The posterior flap includes some gastrocnemius muscle to cover the cut tibia, forming a cylindrical stump. After haemostasis is achieved the skin is closed with interrupted sutures. A suction vacuum drain may be left in situ.
- C:** **Early:** Pain, DVT, flap ischaemia, stump haematoma, neuroma or infection, stump length too long or short, bony spurs, psychological problems.  
**Late:** 'Phantom' limb pain (reduced by strong analgesia post-op), neuroma formation, erosion of bone through skin, ischaemia, osteomyelitis, ulceration.
- P:** Amputations are most often carried out in those with concomitant severe atherosclerotic disease and there is major risk of other vascular problems with survival only 30% at 5-year post-amputation.  
 For diagrammatic review on general amputations see Fig. 2.



# Amputation continued

CONDITIONS

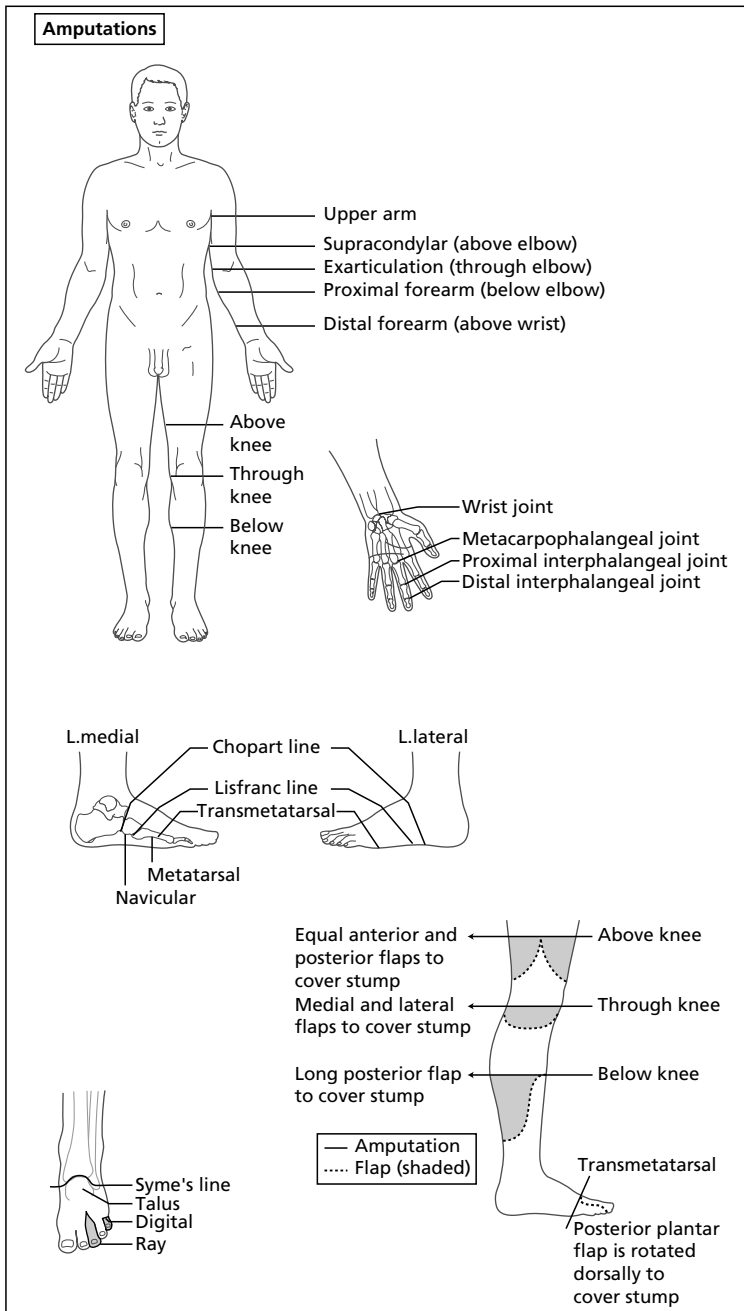


Fig. 2

## Anal carcinoma

- D:** Malignancy arising in the anal canal
- A:** Linked to oncogenic types of human papilloma virus (e.g. 16, 18).
- A/R:** Genital warts, homosexual men and those engaging in anoreceptive intercourse may be at higher risk, HIV, chronic fistulae and previous pelvic irradiation may also ↑ risk.
- E:** Uncommon, 3–4% of large bowel carcinomas, females > males (but anal margin tumours more common in men), mean age 50–70 years.
- H:** Rectal bleeding, pruritus ani, anal discomfort, pain or discharge, tenesmus. If there is sphincter involvement, faecal incontinence will occur.
- E:** An ulcer or proliferative growth may be seen on inspection of the anal margin or an area of induration or mass felt on PR examination. 15–30% will have palpable inguinal lymph nodes at presentation (but only ~50% will contain tumour).
- P:** **Micro:** Most common type is squamous cell carcinoma (80%), remainder are adenocarcinoma or more rarely, malignant melanoma (most common site after skin and eye), and are usually unpigmented. Anal intraepithelial neoplasia describes dysplasia in the squamous epithelium with nuclear hyperchromatism, cellular and nuclear pleomorphism and abnormal mitoses and is thought to be premalignant.  
**Macro:** Anal carcinoma is classified into two groups based on location: anal canal (tends to be poorly differentiated non-keratinising) and anal margin tumours (15–30%, tend to be well differentiated producing keratin). Tumours above the dentate line spread to pelvic lymph nodes, while those below spread to inguinal nodes.  
**TNM staging system:** **0:** carcinoma in situ; **I:** ≤ 2 cm, no sphincter involvement; **II:** ≥ 2 cm, but nodes or adjacent organs not involved; **IIIA:** spread to perirectal nodes or adjacent organs; **IIIB:** spread to iliac or inguinal nodes or adjacent organs and perirectal nodes; **IV:** spread to distant nodes/organs.
- I:** **Proctoscopy and biopsy:** For histology. Examination under anaesthesia may be necessary.  
**Bloods:** FBC (for anaemia), LFT.  
**Imaging:** Endoanal ultrasound to assess muscle invasion, MRI or CT scanning for staging. CXR to look for metastasis.
- M:** Combined modalities of chemotherapy and radiotherapy are used in the management of anal carcinoma, with outcomes comparable to radical surgery with preservation of the anal sphincter. Agents (e.g. 5-fluorouracil and mitomycin C or cisplatin) are used in combination with local radiotherapy to the anal area and inguinal nodes.  
**Surgery:** Local excision of small epidermoid carcinomas of the anal margin may be curative. In the past, abdomino-perineal resection was carried out for carcinomas of the anal canal; however, with advances in chemoradiotherapy, this is now usually reserved for residual disease, recurrence post radiotherapy, those with obstructive cancers or other malignancies of the anal canal (e.g. adenocarcinoma).
- C:** **Local:** Pain, bleeding, incontinence, rectovaginal fistula if neglected.  
**From radiotherapy:** Radiation-induced dermatitis, perineal irritation, proctitis and diarrhoea.
- P:** Important factors are histological type, site, differentiation and stage. 5 years survival for early stage squamous carcinomas treated by radical chemo/radiotherapy is 80%; if inguinal nodes are involved, this is reduced to 30%. Melanoma in this region has a poor prognosis, with only a 10% cure rate by surgery.

- D:** A longitudinal tear in the squamous epithelium of the distal anal canal.
- A:** Commonly caused by passage of a large hard stool, resulting in pain and sphincter spasm that interferes with local blood supply and hence, healing. A self-perpetuating cycle of pain, spasm and re-injury results.
- A/R:** Constipation.
- E:** Common, occurs at any age, especially 30–50 years and in children, males slightly more commonly than females.
- H:** Severe acute pain at the anus on defecation that may last from a few minutes to hours, often with a small amount of bleeding (seen as bright red blood streaked on the toilet paper, not mixed with stool). There is subsequent fear of defecation and constipation.
- E:** On inspection, the fissure is visible as a small linear cut, but is often concealed by sphincter spasm. A chronic fissure is often associated with a 'sentinel pile', which is a small skin tag present on the anal verge. Rectal examination may be aided by application of local anaesthetic but is usually not possible due to the severity of the pain.
- P:** The anal fissure is nearly always in the midline of the posterior anal margin extending from the anal margin to a point below the dentate line, probably because this region is a vascular watershed and susceptible to poor healing. The fissure is of variable depth with granulation tissue or fibres of the external anal sphincter visible. 10% in women and 1% in men are anterior.
- I:** Diagnosis is usually made on history and examination (under anaesthesia if necessary). Fissures that are not in the midline (rare) should be treated with caution and biopsied as may be due to infection (syphilitic chancre, herpes simplex, TB), IBD or malignancy.
- M:** **Medical:** Chemical sphincterotomy by the topical application of 0.2% glyceryl trinitrate ointment. This releases local nitric oxide that mediates smooth muscle relaxation, reducing spasm and allowing healing (major side-effect is headache). Other agents that have been shown to be effective are topical calcium channel blocker, diltiazem and injections of botulinum toxin. Pain relief is given in the form of local anaesthetic gel (1% lignocaine) applied before defecation. Laxatives may be necessary (stool softeners or bulk laxatives) to relieve straining. General advice on the avoidance of constipation should be given (e.g. a high-fibre diet, ↑ water intake and appropriate exercise).  
**Surgical:** When there is failure of conservative treatment. Lateral submucous (internal) sphincterotomy involves division of fibres of the internal sphincter, at the 3 o'clock position, distal to the line of the anal valves. This is an effective procedure, but the patient needs to be warned about the risk of incontinence or flatus for a variable period afterwards. Anal stretches are no longer performed as it has often produced irreparable damage to the anal sphincter.
- C:** An abscess or a subsequent fistula may develop (see Fig. 25b). Up to 15% of those undergoing surgery will experience incontinence of flatus.
- P:** Generally good with glyceryl trinitrate, which is said to cure up to 60% of anal fissures, may become chronic if left untreated.

## Angiodysplasia

- D:** Angiodysplasias are GI mucosal vascular ectasias (dilatations) that develop with ageing, most commonly occurring in the colon.
- A:** Exact unknown but thought to be acquired as a degenerative process, possibly resulting from chronic, low-grade obstruction of submucosal veins.
- A/R:** Distinction from diverticular disease can be difficult as 50% of those with bleeds secondary to angiodysplasia also have diverticular disease; has also been associated with aortic stenosis and von Willebrand's disease.
- E:** Present in ~6% of those undergoing colonoscopy for variable indications and more common in elderly (~25% in >60 years, most remaining asymptomatic).
- H:** Presents with bleeding PR, can be acute and rapid, characteristically intermittent with spontaneous cessation. Re-bleeding is common. The type of bleeding and volume of blood loss should be estimated.
- E:** Signs of shock if significant blood loss (hypotension, tachycardia). No characteristic signs on abdominal examination.
- P:** **Macro:** Angiodysplasias often occur in the caecum and ascending colon, although the left colon can also be affected. On colonoscopy the lesions are visible as small, raised or flat 'cherry-red' areas. 25% of cases are multiple.  
**Micro:** Consist of dilated tortuous thin-walled submucosal vessels that contain only small amount of muscle in their walls.
- I:** **Bloods:** FBC, U&Es, clotting, crossmatch (6 units if significant bleed).  
**Endoscopy:** Proctosigmoidoscopy as part of initial assessment, upper GI endoscopy should be carried out in cases of massive haemorrhage when source unknown. Once stable and can tolerate bowel preparation, colonoscopy.  
**Imaging:** Angiography of superior or inferior mesenteric arteries shows vascular tufts in the capillary phase and early filling of dilated veins (> 1 ml/min blood loss required to visualise bleeding source). Radionuclide scanning: <sup>99m</sup>Tc-labelled RBCs can detect bleeding of < 0.5 ml/min, but lacks spatial discrimination.
- M:** **Emergency:** Assessment of haemodynamic status and resuscitation, O<sub>2</sub>, IV access and fluids, blood transfusion if required. In elderly with significant bleeds, invasive monitoring may be necessary (CVP monitoring and urinary catheter).  
**Endoscopic:** Angiodysplasias may be treated by diathermy or photocoagulation during colonoscopy.  
**Surgery:** Need is dictated by rate and severity of blood loss. Following antegrade colon lavage by placement of a catheter in the appendix stump; on-table colonoscopy can be used to confirm the location of the bleeding and a segmental resection and primary anastomosis or a subtotal colectomy performed. If the source of bleeding is unclear, a rectal source is again excluded and on-table enteroscopy undertaken to examine for distal small bowel lesions.  
**Interventional radiology:** Angiography and transcatheter embolisation of bleeding vessels can be used (can have serious complications, e.g. bowel ischaemia).
- C:** Haemorrhage, hypovolaemic shock, complications of investigations and treatment.
- P:** Bleeding is usually self-limiting. ~50% of those with bleeding episodes treated conservatively with observation and transfusion will continue to have episodes during the next few years.

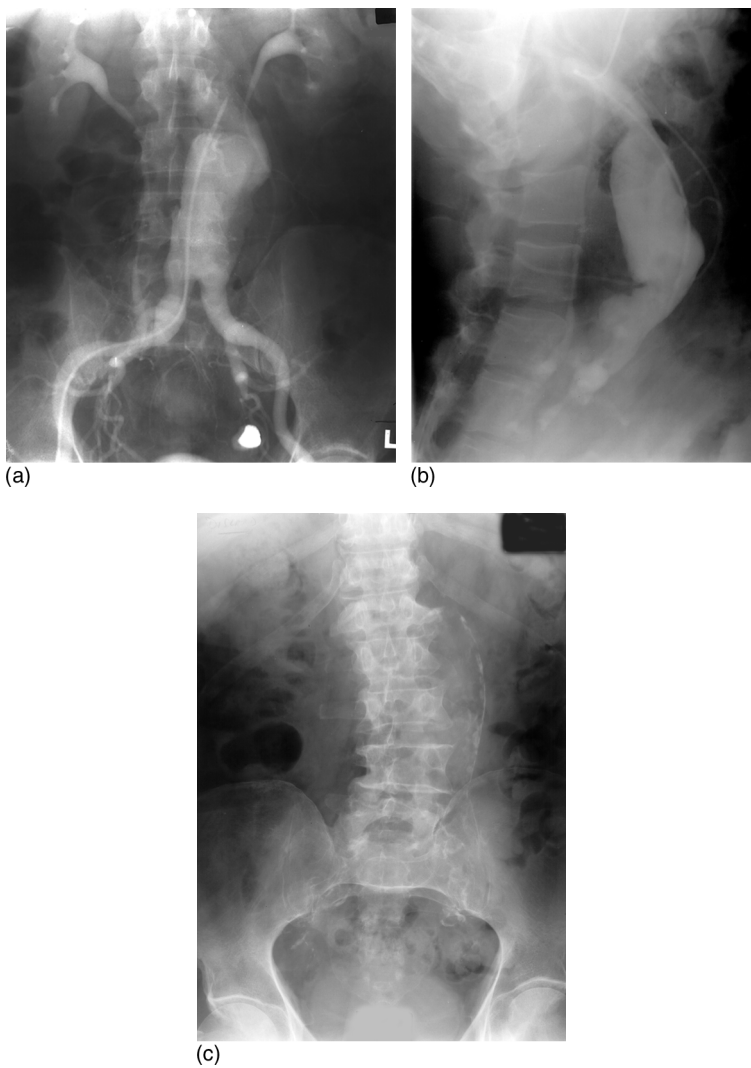
## Aortic aneurysm, Abdominal

13

- D:** Permanent localised dilatation of the abdominal aorta greater than 3 cm.
- A:** 95% of AAAs are due to atherosclerosis. Other aetiologies are inflammatory (variant of atherosclerotic aneurysms), traumatic, infective (mycotic) and connective tissue diseases, Marfan's syndrome and Ehlers–Danlos type IV.
- A/R:** Hypertension, smoking and family history.
- E:** 5% of the population > 60 years and 15% > 80 years will have an AAA. Male : female is 4–6 : 1.
- H:** The majority are asymptomatic, may be found incidentally. Symptoms may be related to vertebral body erosion, distal embolisation, thrombosis or rupture.  
**Emergency presentation:** May have epigastric or back pain ranging from vague discomfort to excruciating pain, or collapse associated with leakage or rupture. Rarely, present with GI bleeding due to erosion into the duodenum or high output cardiac failure due to aortocaval fistula.
- E:** A pulsatile mass is felt above the umbilicus. If leaking or rupture, abdominal and back tenderness with pallor, tachycardia, hypotension and hypovolaemic shock.
- P:** Atherosclerosis leads to thinning of the media, loss of smooth muscle cells and elastic fibres with progressive replacement by noncontractile inelastic collagen leading to generalised dilatation of the vessel. Most commonly involve the infrarenal aorta, with iliac involvement in 30% cases (see Fig. 3). Risk of rupture is related to diameter (Laplace's law: tension proportional to radius and pressure): > 5.5 cm risk 10–15% per year, if 7 cm risk is > 75%. Patients with rupture surviving until arrival in hospital have a leak tamponaded within the retroperitoneum.
- I:** **Bloods:** FBC, U&Es, clotting, crossmatch blood in acute presentation.  
**Imaging: CT scan or ultrasound:** Confirms presence and size of the aneurysm.  
**Arteriography or MRA:** May be necessary to measure involvement of the renal arteries prior to treatment.
- M:** **Conservative:** Small asymptomatic aneurysms (less than 5.5 cm) are followed up with regular ultrasound and treatment for cardiovascular risk factors.  
**Radiological:** Endovascular treatment by stent placement is increasing with trials underway to compare with standard open repairs, e.g. EVAR trials.  
**Surgical:** AAA surgery with tube or bifurcation grafts (see Procedures).  
**Indications:** Leaking or ruptured aneurysm – if high suspicion should be taken straight to theatre.  
 Asymptomatic aneurysms more than 5.5 cm in diameter.  
 Symptomatic aneurysms.  
 Expanding aneurysms (> 0.5 cm in 1 year).
- C:** **From disease:** Rupture (most frequent), distal embolus, sudden complete thrombosis, infection (gram-negative organisms or *staphylococci*), chronic consumptive coagulopathy, renal failure (from RAS), gut ischaemia, aortic-intestinal fistula, arteriovenous fistula from aneurysm eroding into the IVC.  
**From surgery:** Haemorrhage, embolism, graft thrombosis, graft infection.
- P:** Risk of rupture related to size of aneurysm.  
 < 50% of patients with a ruptured AAA reach hospital alive and only about 50% of these survive (overall 80% mortality).  
 Elective surgery, however, have a mortality of < 5% with a 5-year survival of 72%.

14 **Aortic aneurysm, Abdominal** continued

---



**Fig. 3** Abdominal aortic aneurysm: (a) AP; (b) lateral; (c) with obvious calcification in the walls.

## Aortic aneurysm repair, Abdominal

- I:** **Elective:** Large asymptomatic aneurysms (> 5.5 cm in diameter). Expanding aneurysms (> 0.5 cm in 1 year). Symptomatic aneurysms.  
**Emergency:** Leaking or ruptured aneurysms.
- A:** The abdominal aorta is a retroperitoneal structure entering the abdomen in front of the 12th thoracic vertebra. It descends anterior to the lumbar vertebra, dividing in front of the 4th lumbar vertebra to form the right and left common iliac arteries. The IVC, cisterna chili and the azygos vein lies on its right while the left sympathetic trunk runs close to its left margin.
- I:** In elective repairs, aneurysm size and anatomy is assessed by ultrasound or CT/MRA scanning.  
**Pre-op:** FBC, clotting, U&Es, crossmatch (6–8 units of blood).  
**Post-op:** Urinary catheter and close monitoring of fluid balance. Inspect lower limbs for emboli. DVT prophylaxis.
- P:** **Open AAA repair: Access:** A vertical midline laparotomy incision is made from the xiphoid to the pubis followed by abdominal exploration.  
**Exposure:** The small bowel is displaced upwards to the right, exposing the retroperitoneum over the aorta, which is incised slightly to the right to prevent damage to the left sympathetic chain. Dissection is carried out to expose the aorta from the infrarenal aorta to the bifurcation, with care taken to avoid injury to the left renal vein, which crosses in front of the aorta. The inferior mesenteric artery is identified, ligated and transected. Systemic heparin is administered and clamps are placed at the proximal and distal ends of the aneurysm.  
**Opening the aneurysm:** The aneurysm is opened longitudinally, exposing the contents. Thrombus within the aneurysm is removed, and any bleeding from lumbar arteries in the back wall controlled with sutures.  
**Insertion of graft:** The walls of the distal aorta and bifurcation are inspected. In an aneurysm confined to the aorta, a tube graft is used. If the distal aorta or proximal iliacs are diseased, an aorto-iliac or more rarely, aorto-bifemoral trouser graft is used. The grafts are sutured in place with Prolene sutures and flushed to remove air or debris.  
**Assessment of graft:** The aortic clamp is gradually released ensuring haemostasis, followed by gradual opening of the distal end with close monitoring due to the risk of hypotension and arrhythmias. The aneurysm sac is then closed around the graft and sutured to prevent adhesions with the anastomosis suture line.  
**Closure:** 3-layer closure with one continuous suture for all deep layers, one continuous suture for subcuticular fat, and staples, subcuticular or interrupted sutures for the skin.  
Post-op care is usually within an ITU or HDU setting with close monitoring. In emergency setting of aneurysm rupture, the patient is rushed to theatre, maintaining systolic BP of ~80–100 mmHg. Following 'crash' induction of anaesthesia, the patient is rapidly draped, prepared with aim for rapid clamping and control of the bleeding vessel.
- C:** Haemorrhage, myocardial ischaemia, MI or arrhythmias, CVA, respiratory complications: atelectasis, infection, ARDS, colonic ischaemia, spinal ischaemia, atheromatous embolisation, renal failure, graft thrombosis, endoleak. Late: graft infection, aorto-enteric fistula, false aneurysm at anastomosis.
- P:** Elective operative mortality is now < 5% in most units. Emergency repair of a leaking or ruptured aortic aneurysm has a very high mortality.

## Aortic dissection

- D:** Aortic dissection occurs when a tear in the artery intima allows blood to enter the media, separating the inner and outer layers producing a false channel.  
**Stanford** classification: Type A involving the ascending (+/-descending) aorta; type B involving only the descending aorta.  
**De Bakey** classification: Type I: proximal tear, with dissection involving ascending and descending aorta; type II: ascending aorta only; type III: descending aorta only.
- A:** Caused by a defect in the artery intima and weakness of the media in association with risk factors mentioned below.
- A/R:** Hypertension, atherosclerosis, Marfan's syndrome, tertiary syphilis, rarely iatrogenic injury during arteriography.
- E:** Uncommon, but often lethal. Male > female, peak incidence in 50–70 years.
- H:** Sudden, very severe chest pain ('tearing' in quality) that radiates through to the back, no prodromal symptoms.
- E:** Hypertension (but if rupture occurs, shock develops); heart murmur (early diastolic) may be present due to the acute aortic regurgitation.  
 In some patients there are unequal limb pulses (measure BP in both arms) or signs of an acute CVA due to occlusion of the main vessels off the aortic arch.
- P:**  $\frac{2}{3}$  occur in the anterior wall above the aortic valve and  $\frac{1}{3}$  on the posterior wall of the proximal descending aorta (sites of maximal stress). Occasionally, the tract can re-enter the main lumen, creating a 'double-barrelled' aorta. In some cases there is cystic medial necrosis, a form of mucoid degeneration of the media with elastic fibre fragmentation; an exaggerated form of this is present in Marfan's disease.
- I:** **CXR:** Widened mediastinum (but normal in up to 50%), occasionally a left pleural effusion occurs with a contained rupture.  
**CT scan:** Can be used for rapid diagnosis.  
**MRA, echocardiography (transoesophageal):** Can give information about valve competence.  
**ECG:** As 10% will develop an MI due to retrograde dissection of the ascending aorta, resulting in occlusion of the right coronary artery.
- M:** **Medical:** Suitable for uncomplicated distal or stable arch dissection. Aggressive control of BP (e.g. with sodium nitroprusside or  $\beta$ -blockers) to prevent extension of the dissection. Close monitoring of vital signs.  
**Surgical:** Treatment of choice for proximal dissection and distal dissection with organ compromise, rupture or impending rupture. Involves resection of the ascending aorta and replacement with a synthetic graft. If the aortic root is involved, the aortic valve is replaced with reimplantation of the coronary ostia (Bentall procedure).
- C:** Acute aortic regurgitation, MI, cardiac tamponade, stroke, renal failure, spinal cord or bowel ischaemia. Initial diagnostic error, delay in referral for surgery or tear perpetuation by administration of thrombolytics for misdiagnosis of AMI is not uncommon.
- P:** **Type A:** > 80% mortality without surgery, falling to 20% with surgery.  
**Type B:** Mortality is lower, but up to 20% of survivors will develop an AAA and imaging surveillance is recommended.



**I:** Acute appendicitis.

**A:** The appendix, a vestigial organ, arises at the convergence of the taeniae coli on the posteromedial side of the caecum, 2.5 cm below the junction with the terminal ileum. The length varies from 1.2–22.0 cm and the appendix can lie in variable positions, retrocaecal (~70%), pelvic (20%), subcaecal (2%) and pre- or post-ileal (5%). It has a mesentery, the mesoappendix, in which runs the appendicular artery, a branch of the ileocolic artery. Lymphatics from the appendix traverse the mesoappendix to drain into ileocaecal nodes.

**I:** **Pre-op:** FBC, U&Es, LFT, amylase, CRP, urinalysis. In females of childbearing age, a pregnancy test should be performed. Antibiotic prophylaxis is given.

**Post-op:** Antibiotics may be continued if the appendix is inflamed.

**P:** **Access:** Lanz (transverse skin crease) incision is made 2 cm below the umbilicus, centred on the midclavicular–midinguinal line, the SC fat divided and external oblique aponeurosis exposed. A small slit is made in the direction of the fibres of the external oblique, then extended with scissors. Internal oblique muscle is split along the direction of its fibres by blunt dissection, as is transversus and the opening gently enlarged using retractors. Once the peritoneum is exposed, it is gently picked up with a clip. A second clip is then placed and the first clip repositioned. The length between the clips is palpated (for any bowel caught up between the clips) before a small cut is made, and then extended.

**Identification:** The caecum is identified and the taeniae followed to find the base of the appendix, freeing it from inflammatory adhesions by gentle blunt dissection. Babcock's forceps is used to pick up the appendix. If the appendix is found to be normal ('lily-white'), it should still be removed; however, the small bowel should be systematically inspected for terminal ileitis, a Meckel's diverticulum or mesenteric adenitis. In females, the right ovary and tube should be inspected.

**Resection:** The mesoappendix is clipped and divided after tying off, ensuring haemostasis. A crushing clamp is used to crush the base of the appendix and a tie placed around the base before removal. The appendix is sent for histological analysis. Usually the appendix stump is buried using a purse string suture. The cavity should be washed if there has been inflammatory fluid or pus.

**Closure:** The incision is then closed in layers. A continuous suture of the peritoneum, interrupted sutures to the muscle layers and then continuous sutures to the external oblique (the latter is very important in preventing subsequent hernias) are given. A subcuticular absorbable suture is usually used for the skin. Local anaesthetic infiltration reduces post-op pain.

**Laparoscopic appendicectomy:** An alternative technique, which is very useful in women where the diagnosis may be equivocal as it can be both diagnostic and therapeutic.

**C:** Relatively uncommon, but presence reflects the degree of inflammation or peritonitis (e.g. ileus, haemorrhage, wound infection, more rarely, local abscess or a pelvic abscess).

**P:** Usually good with mortality < 1% but this can be higher in elderly or if perforation occurs.

## Appendicitis

- D:** Acute inflammation and infection of the appendix.
- A:** Thought to be initiated by luminal obstruction by a faecolith (inspissated faeces), lymphoid hyperplasia or oedema.
- A/R:** May be associated with low dietary fibre intake.
- E:** Any age, but most common in < 40 years. Appendectomy is the most common emergency surgical operation, with about 1/6 lifetime risk.
- H:** **Classic presentation** (< 50% of cases): Abdominal pain (usually < 72 h), initially diffuse, periumbilical and colicky (visceral pain lasting a few hours). The pain becomes sharp and localised to the RIF (somatic pain as parietal peritoneum involved). Anorexia (the most constant symptom) and nausea are common. Vomiting may develop hours after onset of pain.  
**Alternative presentations:** Pain in the right flank (retrocaecal appendix), the right upper quadrant (long appendix) or lower abdomen (pelvic appendix). May be associated urinary frequency or loose stools due to bladder or bowel irritation by the inflamed appendix.
- E:** Mild pyrexia, facial flush, tachycardia.  
 Abdominal pain often maximal at McBurney's point (2/3 along a line from the umbilicus to the anterior superior iliac spine) with rebound tenderness (demonstrable on percussion) and guarding.  
 Signs of peritoneal inflammation: pain on coughing or while sucking in or blowing out the abdominal wall.  
 Rovsing's sign is pain in the RIF elicited by pressure over the LIF, but is unreliable.
- P:** Luminal obstruction results in proliferation of bowel flora and inflammation that extends transmurally. Swelling results in obstruction and thrombosis of end arteries and the appendix becomes gangrenous and necrotic. The inflammation may become localised by omentum or bowel loops to form an appendix mass or abscess, or perforation and spreading peritonitis may occur if not treated.
- I:** Appendicitis is a clinical diagnosis; there is no definitive test to confirm or exclude it.  
**Bloods:** † WCC and CRP (especially in later stages), amylase (to exclude pancreatitis), U&Es.  
**Urine:** For microscopy, culture and sensitivity (to exclude infection), pregnancy test in women of childbearing age.  
**Imaging:** AXR or ultrasound (not usually diagnostic).
- M:** **General:** Rehydration with IV fluids, broad-spectrum antibiotics are given pre-op (e.g. cefuroxime and metronidazole). If symptoms or signs are equivocal, observation with frequent re-examination.  
**Surgery:** Appendectomy (see Procedures). In young women, diagnostic laparoscopy may be necessary if diagnosis is not certain.  
 Post-op, antibiotics may be given for up to 48 h in early cases but for 7–10 days in cases of gangrenous or perforated appendix. If an **appendix abscess** is present, drainage must be performed, either percutaneously with ultrasound control or intra-operatively (with appendectomy if safe). Management of an **appendiceal mass** may be non-operative with antibiotics, parenteral fluids and frequent reassessment, with operation if clinical deterioration occurs. Interval appendectomy performed 6–8 weeks later (Ochsner–Sherren approach). If this is not performed in adults, imaging such as barium enema or colonoscopy should be done to exclude a local perforation, e.g. of carcinoma of the right colon.
- C:** Formation of an inflammatory mass, appendix abscess, perforation and peritonitis, rarely portal pyemia.

## Appendicitis continued

19

---

**Post-op:** Wound infection, wound abscess, abdominal abscess, adynamic ileus, rarely a faecal fistula from the appendix stump.

**P:** Appendicectomy is curative. If untreated, it can be life-threatening. Diagnosis is difficult in the very young, elderly and in pregnancy; morbidity and mortality in those groups are higher.

CONDITIONS

## Arteriovenous fistulae and malformations

- D:** An arteriovenous fistula or malformation is an abnormal communication between an artery and vein that bypasses the capillary bed.
- A:** **Congenital:** Fistulae can be divided into *haemangiomas*, e.g. strawberry naevi, and *malformations* (AVMs). The latter is divided into *low flow* or *high flow* (e.g. hepatic or pulmonary AVM).  
**Acquired:** Trauma, tumours (e.g. glomus tumour, hepatoma, hypernephroma and sarcomas), infection, inflammation (e.g. aortocaval fistula) or iatrogenic (e.g. Brescia–Cimino fistula for haemodialysis or portocaval shunt in portal hypertension).
- A/R:** AVMs are associated with many different syndromes, e.g. Klippel–Trénaunay, Kasabach–Merritt, Sturge–Weber, von-Hippel–Lindau and Rendu–Osler–Weber syndrome (the latter is caused by a defect in the protein, endoglin, which carries a 30% risk of developing a pulmonary AVM).
- E:** AVMs such as cutaneous haemangiomas are common, the others less so.
- H:** Presentation is variable, depending on the site and size of the AVM and symptoms may be due to local, peripheral or systemic effects (see below). Congenital AVMs involving the skin are often visible from birth (haemangiomas appear ~4 weeks after birth). Malformations usually grow with age, often during puberty or pregnancy in women, and those within internal organs may only be detected once complications develop; e.g. brain AVMs may cause haemorrhage, epilepsy or a neurological deficit. Other presentations include varicose veins, limb swelling or pain.
- E:** Cutaneous haemangiomas are usually scarlet in colour, firm and cannot be emptied of blood on compression. Internal AVMs may be revealed by an overlying bruit, possibly with reduced distal pulses and an ↑ pulse pressure. There may be signs of cardiac failure in large AVMs. There may be focal neurological signs in cerebral AVMs, especially after a complication such as haemorrhage.
- P:** Congenital AVMs are thought to arise due to anomalous embryonic vascular development and can involve arteries, veins, capillaries or lymphatics. Haemangiomas result from endothelial hyperplasia and contain abundant mast cells, whereas endothelial cells in malformations demonstrate normal turnover.
- I:** **Imaging** of the AVM can be carried out by Duplex scanning, CT or MRI scanning or invasively, by angiography.  
**Other:** Quantification of AV shunting can be carried out using <sup>99m</sup>Tc-human albumin microspheres. These are introduced into an artery and are too large to pass through capillaries. Those passing through AVMs are trapped in the lungs and quantified using gamma camera.
- M:** **Conservative:** Cutaneous haemangiomas usually undergo spontaneous regression at the end of the first year of life.  
**Interventional radiology:** In the case of internal AVMs, using metal coils or tissue adhesive or particles to embolise the AVM.  
**Surgery:** Often difficult, but excision (after pre-op embolisation) may be possible in the case of small and accessible AVMs. Stereotactic radiosurgery using a gamma knife has been used on small brain AVMs, but takes 2 years for full effect.
- C:** Depends on size and location.  
**Local:** Cosmetic disfigurement, ulceration, bleeding, local pressure, hydrocephalus.  
**Distal:** Ischaemia of peripheral tissues,  
**Systemic:** High-output cardiac failure in the case of large AVMs.
- P:** Depends on site and aetiology. 90% of haemangiomas regress by 5–10 years. 1–4% annual risk of haemorrhage in cerebral AVMs.