

## 1

## CHAPTER 1

## The healthy heart

The human heart – about the size of a clenched fist – is the center of a complex system designed to help the body nourish its organs with life-giving oxygen and to remove waste products in the form of carbon dioxide from the body. Simple animals, such as insects, have an open circulatory system, in which the heart pumps blood through the body cavity, washing the organs directly. More complex animals, including all vertebrates, have a closed circulatory system, which requires the heart to pump blood throughout a network of vessels. No system of vessels is as complex as that of a human being, and it is so closely related to the heart's function that we frequently talk of the “cardiovascular” or CV system rather than the heart in isolation.

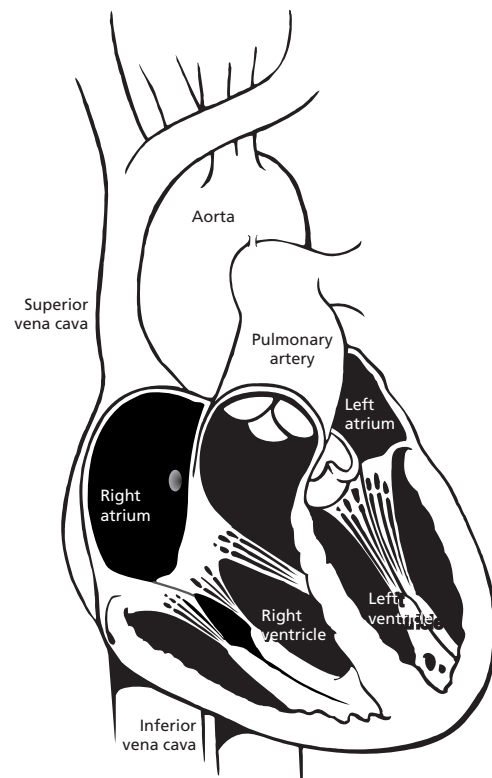
In the human CV system, blood stays in the vessels while oxygen and carbon dioxide are exchanged by diffusion through the vessel walls. So intricate is the human circulatory system that there are actually two complementary networks: a pulmonary circulatory system, designed to get deoxygenated blood to the lungs so it can be “revitalized” with oxygen, and a systemic circulatory system which pumps oxygen-rich blood throughout the body to nourish muscles, tissues, and organs.

At the heart of this elaborate circulatory system is, literally, the heart. At its most basic, the healthy human heart is an efficient and effective pump, beating about 70 times a minute without stopping over the course of a human lifespan. The circulatory system is designed to get oxygen-rich blood where it is needed when it is needed, so the heart regulates its own activities, beating more rapidly during times of increased oxygen consumption and more slowly during periods of decreased demand, such as rest and sleep.

The heart is a muscle with four hollow chambers: two upper and two lower (Fig. 1.1). On top are the atria (singular: atrium), thin-walled, small chambers that take their name from our architec-

tural word “atrium.” They are the ante-chambers or front lobby of the heart. The two lower chambers are large, thick-walled, heavily muscled chambers called ventricles. The ventricles are responsible for most of the pumping action of the heart.

While physicians can talk about the heart in terms of atria and ventricles, or upper and lower chambers, it is also possible to talk about the heart in terms of right side and left side. The right side of the



**Fig. 1.1** The four chambers of the heart with the largest vessels in the body: the superior and inferior vena cava (which feed deoxygenated blood to the heart) and the aorta (which carries oxygen-rich blood from the heart to the rest of the body).

heart consists of the right atrium and the right ventricle, which are connected to each other through the tricuspid valve. When deoxygenated blood flows back to the heart to become reoxygenated, it first enters the right side of the heart. This deoxygenated blood arrives at the right side of the heart through the body's largest veins: the superior vena cava and the inferior vena cava. (In this case, "superior" and "inferior" refer to physical locations of "above" and "below" the heart.) The right side of the heart pumps this oxygen-depleted blood back out through the pulmonary artery to the lungs, where it picks up much-needed oxygen. Once the blood has received oxygen, the venous system routes the blood back into the heart, this time to the left side.

Loaded with oxygen, the blood reenters the heart through the pulmonary veins into the left atrium and the left ventricle, connected by the mitral valve. The left side of the heart pumps the blood back out to the rest of the body (the systemic circulatory system) through the aorta and the arteries that branch off the aorta.

Cardiac pacing and defibrillation leads for conventional pacemaker and implantable cardioverter defibrillator (ICD) systems are implanted in the right side of the heart. A transvenous lead – i.e. a wire that goes through a patient's vein – can "go with the flow" of blood into the right atrium, through the tricuspid valve, and into the right ventricle. Conventional pacemakers and ICDs have found that pacing the right side of the heart is sufficient to cause a contraction of the entire heart. More recent cardiac resynchronization therapy (CRT) devices require a pacing lead to be implanted in both the right and the left sides of the heart. This poses some technical challenges as a transvenous lead cannot readily travel to this area without going through the heart and then *against* the heart's natural powerful pumping action. CRT therapy and lead placement falls outside the scope of this book, but it is mentioned to give the reader a more complete view of the therapies available.

## Myocardial cells

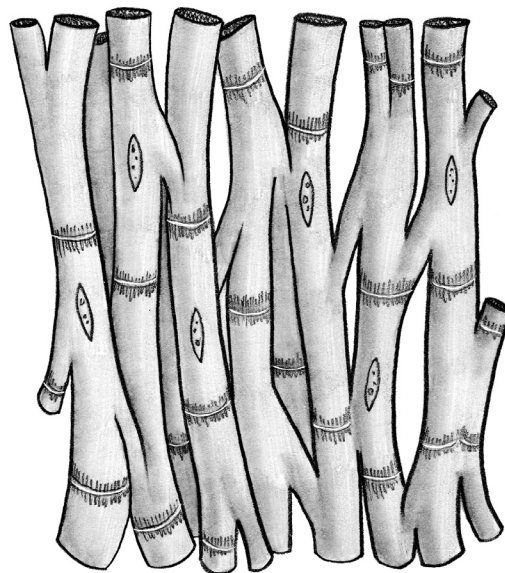
The heart pumps blood through rhythmic contractions or beats, also known as "depolarizations." Depolarization explains what happens to the heart at the cellular level, which is the best way to understand

how it beats. Unlike other muscles, which respond to the control of the brain, the heart regulates its own actions without specific input from the brain. To accomplish this, it relies on some of the body's most complex cellular constructions and interactions.

The healthy human heart has two main types of cells: myocardial cells (heart muscle cells) and conduction system cells (electrical cells). Myocardial cells are the ones that make the heart beat.

All heart cells are cylindrical and branch at their ends into one or more limbs. These cardiac cells are held together with intercalated disks sandwiched between them to form a network (Fig. 1.2). Think of myocardial cells as a dense forest of trunks and limbs and branches with intercalated disks forming connections. These intercalated disks help conduct electricity from cell to cell by relaying the impulse.

While myocardial cells do not conduct electricity as rapidly as the electrical cells of the heart, they do have the property of contractility, an ability to shorten and then return to their original length. Contractility allows myocardial cells to stretch and snap back into place. In this way, the myocardium



**Fig. 1.2** Myocardial cells are specialized cylindrical cells that relax and contract, changing the shape of the heart. Intercalated disks are membranes that include gap junctions for conducting electricity rapidly from one cell to another.

**Table 1.1** Common cardiac drugs

	<i>Increases myocardial contractility</i>	<i>Decreases myocardial contractility</i>
Sympathomimetics (digitalis, bretylium)	X	
Beta blockers		X
Quinidine		X
Procainamide		X
Excessive potassium		X
Hypovolemia	X	
Anemia	X	
Hypocalcemia		X
Hypothyroidism		X
Emotion	X	
Increased venous return to the heart	X	
Shock		X
Fever	X	
Exercise	X	
Emotion	X	

or heart muscle is able to expand to take in blood and then to contract powerfully to pump the blood back out.

Myocardial contractility responds to a variety of influences. Physical stimuli (including exercise, emotion, fever) and some drugs (sympathomimetics such as digitalis) can increase myocardial contractility, forcing the heart to beat more vigorously. Likewise, other stimuli (shock, hypothyroidism, and others) and some drugs (beta blockers, quinidine, procainamide, and excess potassium) can decrease myocardial contractility (Table 1.1).

## The heartbeat

An electrical impulse traveling through the heart causes the cardiac cells to depolarize and contract. The human heartbeat is not one single contraction, but is a precisely timed sequence of four specific events (Fig. 1.3).

Starting with the heart at rest, blood flows naturally into the heart. The valves are open and the heart gets a considerable amount of blood into it through a descriptively named process known as the passive filling of the ventricles. The atria are relaxed in a state known as atrial diastole. When an electrical impulse fires in the heart, the heart beat begins its four-part cycle.

The atria contract (atrial systole) while the ventricles remain relaxed (ventricular diastole). Since

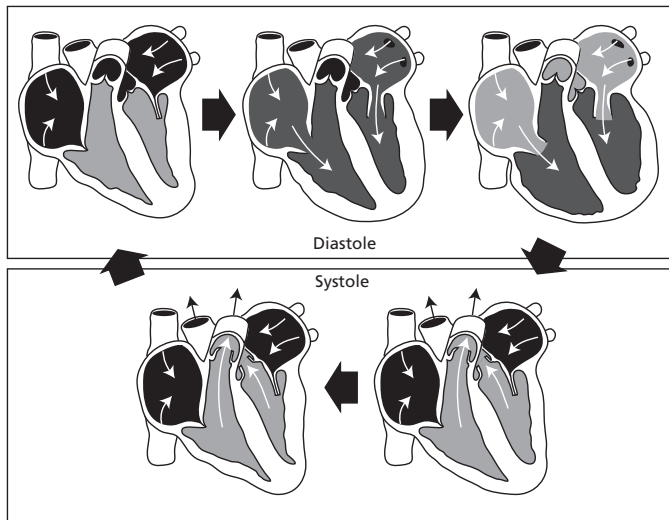
the ventricles are already passively filled with blood, this atrial contraction forces even more blood into the ventricles. Known as the atrial contribution to ventricle filling (or “atrial kick”) this atrial contraction ensures that the ventricles are filled to the point where they have to stretch to accommodate all of the blood within them. The valves joining atrial to ventricular chambers close, so the ventricles now contain a great deal of blood that cannot backflow into the atria.

There is a brief period of rest – measured in ms (thousandths of a second).

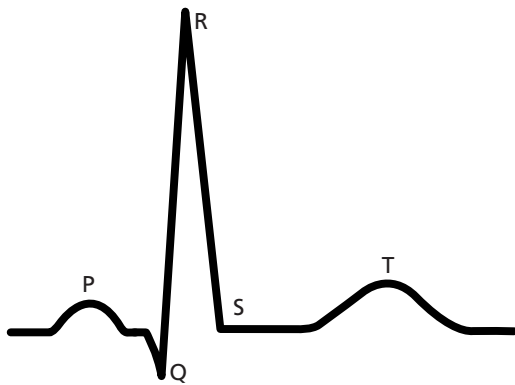
The ventricular cells depolarize forcing a contraction of the powerful ventricular muscles (ventricular systole). This forces blood out over the pulmonary artery (and into the lungs) on the right side or into the aorta (and into the systemic circulatory system) on the left side. This beat is the most powerful action of the heart and it forms the largest complex on an electrocardiogram (ECG).

After contraction, the ventricular muscles repolarize or resume their resting state. The heart resumes the cycle with the passive filling of the ventricles.

Seen on an ECG, a healthy heartbeat shows three distinct wave patterns plus some flat areas of rest (Fig. 1.4). The cycle begins with an atrial beat, shown by the small P wave on the ECG. The flat line between the P wave and the next complex indicates the short rest phase. The large complex, called the



**Fig. 1.3** The heartbeat is a sequence of events that begins with ventricular diastole when the ventricles relax, begin to fill, and complete filling. The next phase is ventricular systole when the ventricles contract and empty. Atrial systole helps completely fill the ventricles, and the valves work to ensure that blood moves efficiently through the heart.



**Fig. 1.4** The main waveforms on a surface ECG correspond to the various parts of the heartbeat. The P wave indicates atrial depolarization. This is followed after a short delay by the large QRS complex, which represents ventricular depolarization. A short pause follows, then the ventricles repolarize. This is shown on an ECG by the T wave. The ventricular contraction is the “biggest” event in the cardiac cycle in terms of creating electrical energy, so it appears as the largest portion of the ECG.

QRS complex, is the ECG depiction of the ventricular contraction. As the ventricles are massively large compared to the atria, the ventricular complex dominates the ECG in terms of size. There are three strokes to the ventricular complex, known as the Q, R, and S. Taken together, they describe the ventricular contraction. Another short expanse of flat line shows a rest period. The last wave in the complex is a T wave, which is the electrical depiction of the ventricles repolarizing or resuming their old form.

## The pump

The healthy heart beats in a four-part cycle consisting of systole (contraction) and diastole (rest) of upper and lower chambers. When the cycles are precisely timed, the heart is able to pump very effectively. The passive filling of the ventricles combined with the “atrial kick” assure that the maximum amount of blood is brought into the ventricles to be pumped back out. The ventricles – forced to stretch to accommodate the large quantity of blood – contract even more strongly because of this stretch (Starling’s law of contractility states that the heart muscle is like a rubber band; the more it is stretched, the more force with which it will snap back). In good working order, the valves in the heart (tricuspid, mitral, pulmonary, and aortic) open clearly and close securely, thus allowing and stopping the flow of blood at the right moments.

The healthy heart relies on a system of vessels to transport blood in and out of the heart. In addition, a separate network of very fine vessels delivers oxygenated blood to the heart muscle itself: the coronary arteries are the heart’s own system for nourishment. When these small vessels get clogged or damaged in coronary artery disease (CAD), the heart muscle may be deprived of the oxygen it needs to work properly.

The healthy heart is able to keep a large amount of blood in constant circulation in the body. When the

body consumes more oxygen, the heart increases its pumping action to keep pace, usually by beating faster. In its perfect state, the heart does a remarkable job of keeping the body fueled with oxygen and exchanging waste products. Of course, many things can occur in such a complex system to impair its ability to perform. Some of the main malfunctions of the cardiovascular system – the heart and its vessels – are listed below.

- **Coronary artery disease** in which the network of small arteries that help feed the heart muscle itself become occluded, typically through hyperlipidemia (cholesterol and plaque deposits). This can limit the heart's ability to perform. In extreme cases, blood flow is blocked causing a heart attack and ischemia to portions of the heart muscle itself. A coronary artery bypass graft (CABG) procedure is a typical intervention to treat blocked coronary arteries.
- **Heart failure** refers to the gradual decline in the ability of the heart muscle to pump efficiently. Although there are many manifestations of heart failure, all involve a deterioration of the pumping capacity of the heart. In some cases, the heart

muscle gets flabby and enlarged; this is known as dilated cardiomyopathy. In other cases, such as hypertrophic cardiomyopathy, the ventricular wall thickens to the point that not only can it not contract properly, it cannot hold an adequate quantity of blood for a heartbeat. Heart failure is typically treated with drugs, but biventricular device therapy (sometimes called cardiac resynchronization therapy or CRT) holds enormous promise, at least for certain types of patients.

- **Conduction disorders** occur when the electrical system that governs the heart does not work correctly. In such cases, the heart muscle may still be strong, but the electrical signals do not allow the heart to function properly. Conduction disorders, also known as rhythm disorders, are the subject of the next chapter – and the main heart condition treated by pacemakers.

### Further reading

Huszar RJ. *Basic Dysrhythmias: Interpretation and Management*. St Louis, MO: C. V. Mosby, 1988.

### The nuts and bolts of the healthy heart

- The human heart is a four-chambered pump that circulates blood through a complex network of vessels.
- The heart can be talked about in terms of upper chambers (atria) and lower chambers (ventricles) or right side (right atrium and right ventricle) and left side (left atrium and left ventricle). The right side pumps oxygen-depleted blood through the pulmonary artery over the lungs, while the left side receives the oxygenated blood and pumps it out through the aorta and into the rest of the body.
- It is much easier to implant a pacing lead in the right side of the heart (which is needed for conventional pacemakers) than the left side of the heart (which is required for “biventricular pacing”).
- When the heart “beats,” it contracts owing to changes at the cellular level called “depolarizations.”
- The heart has two types of cells: myocardial cells (which can depolarize) and conduction system cells (which conduct electricity).
- Myocardial contractility (how the heart muscle contracts) responds to many influences, including exercise, drugs, and fever.
- A single heartbeat breaks down into four phases: (a) atrial systole, when the atria contract but the ventricles remain relaxed; (b) rest; (c) ventricular systole, when the blood is pumped out over the body as the atria relax; (d) rest.
- An ECG is a visual depiction of the heartbeat taken from electricity on the surface of the skin. The P wave is the atrial activity. It is followed by the large QRS complex, which represents ventricular depolarization. The T wave after the QRS represents ventricular repolarization or the resumption of the resting state.
- Systole is the contraction phase, and diastole is the resting phase. Thus systolic blood pressure is

*Continued p.6*

## 6 CHAPTER 1

---

*Continued.*

the blood pressure that occurs when the heart is pumping. Diastolic blood pressure is the blood pressure that occurs when the heart is at rest.

- Coronary artery disease (CAD) occurs when the network of tiny vessels that feed the heart muscle become occluded and limit the heart's ability to perform.
- Heart failure is the gradual decline in the ability of the heart muscle to pump efficiently.

Heart failure may manifest itself as a flabby, enlarged heart (dilated cardiomyopathy) or as the abnormal thickening of the ventricular wall (hypertrophic cardiomyopathy).

- Conduction disorders occur when the heart's electrical system does not work properly. Pacemakers address conduction disorders of the heart.