

Electrocardiogram (ECG)

ECG paper 1 small square = 0.04 s

1 large square = 0.2 s

5 large squares = 1 s

Rate: $300 \div \text{R-R interval (large squares)}$

Rhythm: look at pattern of P, QRS

Sinus rhythm: P followed by QRS complex

Atrial fibrillation: no P, QRS irregular

Atrial flutter: sawtooth baseline and regular QRS

Nodal rhythm: normal QRS, P absent or within QRS

Ventricular rhythm: prolonged QRS followed by P

Axis: To estimate: sum of vectors: I + aVF

Normal: -30° to $+90^\circ$

Left axis deviation: -30° to -90°

Right axis deviation: $+90^\circ$ to $\pm 180^\circ$

P wave

Absent: AF, flutter, SA block

Bifid: LA hypertrophy

Peaked: RA hypertrophy/pulmonary hypertension, hypokalaemia

P-R interval: 0.12 – 0.2 s (3–5 small squares); long (heart block); short (Wolff-Parkinson-White)

QRS complex: ≤ 0.12 s (3 small squares); wide (ventricular rhythm, third degree heart block, BBB, pacing)

Q-T interval: ≤ 0.4 s (2 large squares)

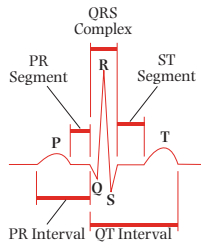
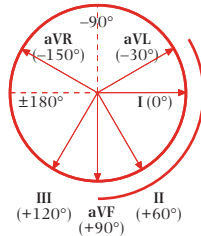
ST segment: elevation > 1 mm (infarction, pericarditis); depression > 0.5 mm (ischaemia, digoxin use)

T wave:

Inversion: normal in aVR, V_1 in all, V_2 in young, V_3 in Afro-Caribbean. Causes: ischaemia, ventricular hypertrophy, BBB, digoxin toxicity (reverse tick)

Peaked: hyperkalaemia, acute MI

Flattened: hypokalaemia





Conduction problems

1° heart block: PR >0.2 s

2° heart block: Mobitz type I /Wenckebach (PR gets longer until drop QRS);
Mobitz type II (occasional non-conducted beats)

3° heart block: no relationship between P waves and QRS

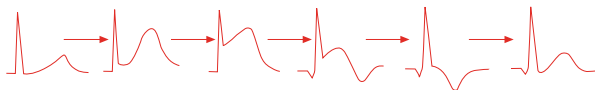RBBB: QRS >0.12 s, RSR' in V₁, deep, wide S V₆ (**MaRRoW**)

LBBB: QRS >0.12 s, M pattern in V₆ (**WILLiaM**)

ECG

ECG in acute myocardial infarction (MI)

Progression of ECG changes



Normal

Hours

Hours

Days

Weeks

Months

Lead groups

Region	Leads	Vessel(s)
Anterior	V ₂₋₄	LCA, LAD
Anterolateral	I, aVL, V ₃₋₆	LAD, circumflex, marginal
Anteroseptal	V ₁₋₄	LAD
Inferior	II, III, aVF	RCA
Lateral	I, aVL, V ₅₋₆	circumflex, LCA
Posterior	V ₈₋₉	RCA, circumflex
RV	V _{4R-6R}	RCA

