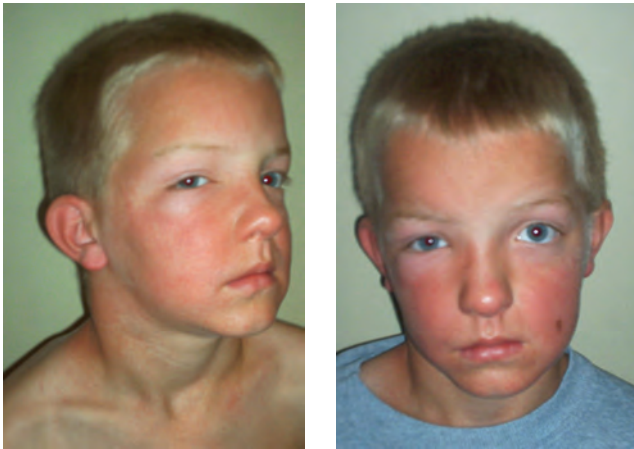

Case 1 | Rash following brush fire

Christopher P. Holstege, MD

Case presentation: A 9-year-old male presents to the emergency department with facial pain, erythema, and swelling. He was in his normal state of health until this morning when he awoke from sleep and noted a diffuse rash over



his face with a marked burning sensation in the region of the rash. It has progressed through the day and involves only his face and neck and stops at his shirt neckline. He has had no fevers and his immunizations are up to date. He denies any other complaints. His best friend also awoke with the same rash. The previous day, while playing on the school playground, they watched a neighboring farm burning brush. Smoke from the fire blew over the area where they were watching. His facial examination is pictured as shown.

Question: The rash is due to:

- A** Type 1 allergic reaction
- B** Type 4 allergic reaction
- C** Roseola
- D** Rubella (German measles)
- E** Rubeola (measles)

See page 67 for Answer, Diagnosis, and Discussion.

Case 2 | Herbalist with bradycardia and vision changes

William J. Brady, MD

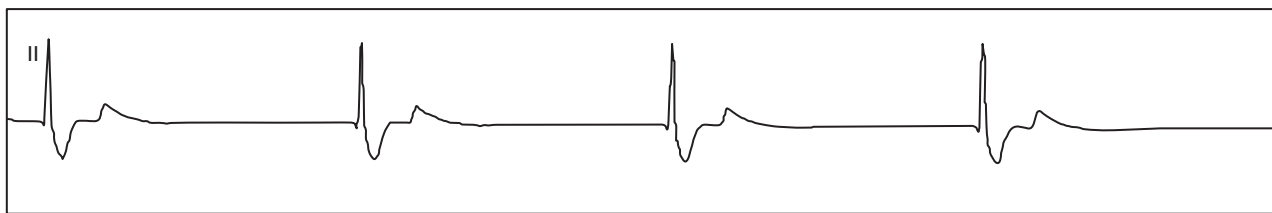
Case presentation: A 33-year-old female herbalist presents to the emergency department with a complaint of weakness and yellow discoloration of her vision. She recently grew the plant pictured at right and is ingesting it as an herbal remedy in an attempt to alleviate menstrual cramps.

On arrival, the patient is alert and oriented. Her initial vital signs are blood pressure 110/60 mmHg, pulse 88 beats/minute, respirations 28 breaths/minute. The rest of her examination is unremarkable. An initial 12-lead electrocardiogram (ECG) demonstrates a normal sinus rhythm with multiple premature ventricular contractions (PVC).

Her electrolyte results returned from the laboratory demonstrating marked hyperkalemia. She subsequently developed progressive bradycardia (see rhythm strip on the next page) over the ensuing 60 minutes.



4 | Visual Diagnosis in Emergency and Critical Care Medicine



Question: Which of the following would be appropriate in the management of this patient?

- A** Digoxin-specific Fab fragments
- B** Physostigmine
- C** Naloxone

- D** Flumazenil
- E** Amiodarone

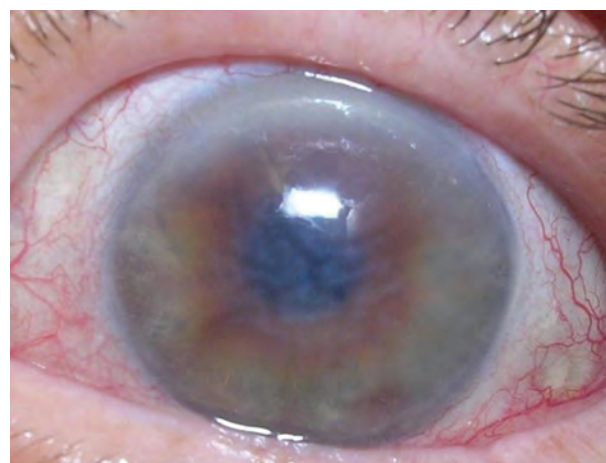
See page 67 for Answer, Diagnosis, and Discussion.

Case 3 | Acute eye pain and blurred vision in an elderly female

Chris S. Bergstrom, MD & Alexander B. Baer, MD

Case presentation: A 68-year-old female with no significant past medical history presents to the emergency department complaining of pain, blurred vision, and colored halos around lights in her left eye. She states that her visual symptoms started acutely along with associated nausea, vomiting, and a frontal headache.

On physical examination the visual acuity is 20/30 in the right eye and 20/100 in the left. Pupillary exam reveals a sluggish, mid-dilated pupil in the left eye as noted in the picture. Slit lamp examination of the left eye shows conjunctival injection with a cloudy cornea. The anterior chamber is shallow and the iris detail is blurred. Palpation of the globes through closed lids demonstrates a normal tension in the right eye and a firm, tense left eye. Intraocular pressures are measured and reveal 15 mmHg in the right eye and 58 mmHg in the left.



Question: Which of the following agents would be appropriate to administer to this patient?

- A** Subcutaneous epinephrine
- B** Topical atropine
- C** Topical timolol

- D** Intravenous atropine
- E** Topical phenylephrine

See page 68 for Answer, Diagnosis, and Discussion.

Case 4 | Suspicious hand pain

Rex Mathew, MD

Case presentation: A 38-year-old man presents to the emergency department on a Saturday night with a right

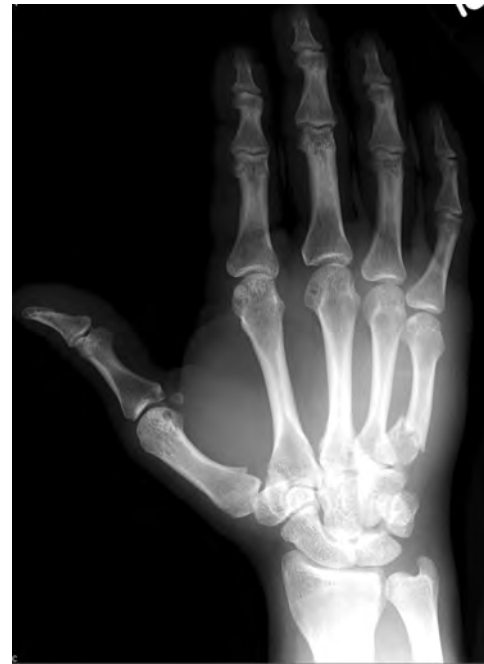hand injury. He states that he simply bumped his hand on a bar stool. On exam, the skin is intact over the fist; there is

swelling over the dorsum of the hand and tenderness over his right 5th metacarpal; the motor, sensory, and vascular exams are normal. An X-ray is obtained.

Question: What is the next most appropriate management strategy at this time?

- A** Reassure the patient that there is no fracture and discharge him with analgesics and ice
- B** Admit the patient for emergent orthopedic surgical repair
- C** Splint the patient and discharge with orthopedic referral
- D** Admit the patient for intravenous antibiotics given the almost certain chance that this represents a fight bite
- E** Admit the patient for rheumatologic evaluation

See page 69 for Answer, Diagnosis, and Discussion.

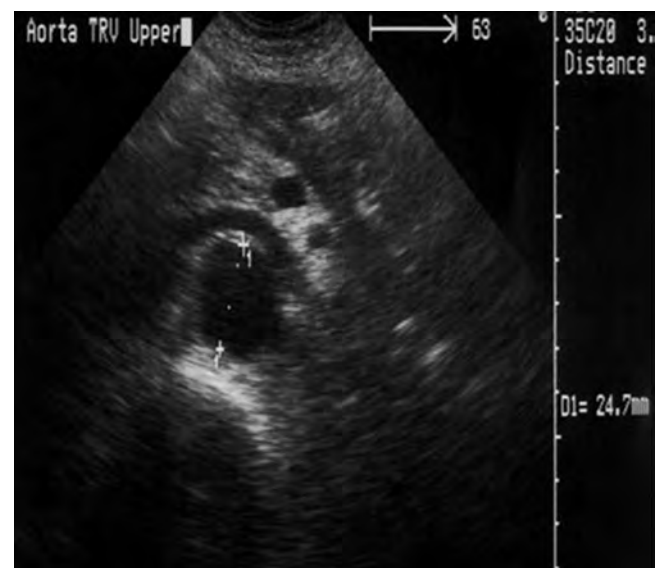
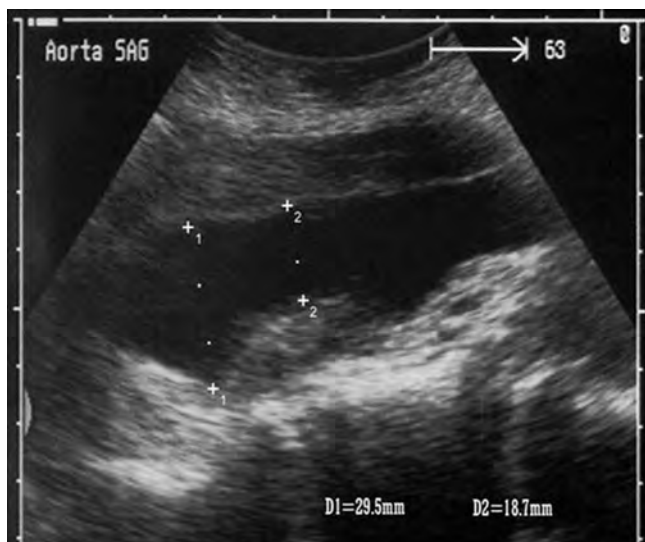
Case 5 | An elderly man with flank pain

Daniel K. Vining, MD & Anthony J. Dean, MD

Case presentation: A 73-year-old man with a history of obesity, hypertension, and cigarette smoking presents to the emergency department after a syncopal episode. He complains of mild left-sided back and flank pain. He has a blood pressure of 118/94 mmHg, pulse of 96 beats/minute, and respirations of 20 breaths/minute. The physical exam is significant only for

mild diffuse abdominal discomfort to palpation with left back and flank tenderness to percussion. His urinalysis is normal. An ultrasound is performed. The image on the left shows a sagittal view of the aorta and the image on the right shows a transverse view of the aorta at the level of the renal veins.



6 | Visual Diagnosis in Emergency and Critical Care Medicine

Question: Which of the following is true?

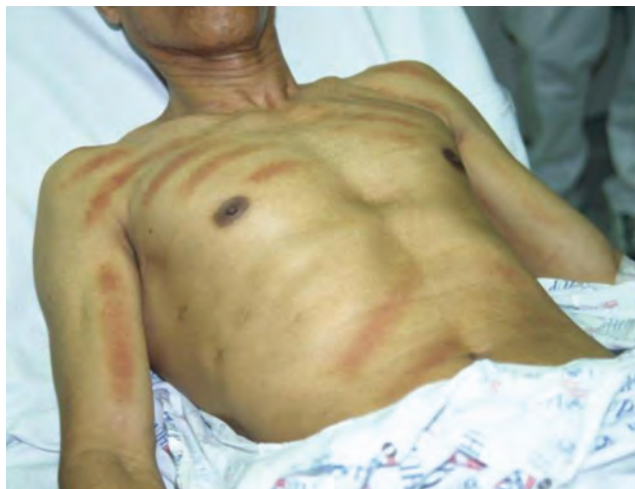- A** The aorta imaged here has a normal diameter. This reduces the likelihood of abdominal aortic aneurysm (AAA) to less than 90%.
- B** The patient has an AAA. If no intra-abdominal free fluid is found in the abdomen, acute aortic aneurysm rupture is excluded from the differential diagnosis.
- C** The patient has an AAA. Immediate surgical consultation and operative intervention are needed.
- D** The patient has an AAA. Since the patient is comfortable and hemodynamically stable, he should be admitted for in-patient observation and further evaluation and imaging.
- E** The aorta imaged here shows significant stenosis. Doppler flow analysis or angiography is needed to identify whether this is the cause of the patient's acute symptoms.

See page 69 for Answer, Diagnosis, and Discussion.

Case 6 | **An immigrant child with skin lesions**

Roger A. Band, MD

Case presentation: A 14-year-old Vietnamese child presents accompanied by his grandmother, complaining of a non-productive cough, rhinorrhea, and low-grade fever to 100.2°F. The grandmother speaks little English, but once the mother arrives, she is able to give you the remaining history; specifically she denies any behavioral changes, trauma, or complaints of abdominal pain or arthralgias. On exam, the child appears generally well, with the exception of signs consistent with a viral upper respiratory tract infection, and the impressive lesions on his trunk pictured.



Question: What is the next most appropriate management strategy at this time?

- A** Give the child's mother appropriate return precautions and follow-up instructions, and reassure her that his upper respiratory tract complaints typically resolve in 2–3 days
- B** Order a CBC, blood culture, and urinalysis
- C** Call social work and child protective services
- D** Order a skeletal survey
- E** Discharge home with an antibiotic cream to be applied to the skin lesions

See page 70 for Answer, Diagnosis, and Discussion.

Case 7 | **Wrist pain following a fall**

Rex Mathew, MD

Case presentation: A 21-year-old man complains of left wrist pain after falling from a 5-foot ladder onto his left

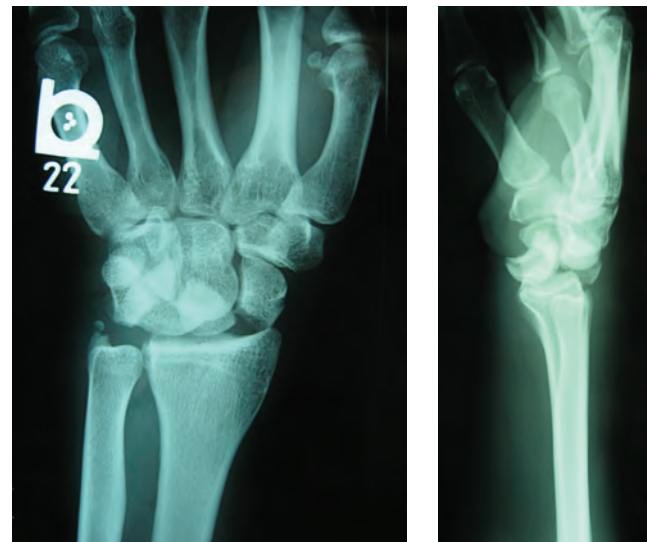hand. On exam, there is swelling and tenderness over his wrist and exam is limited due to pain over the dorsum of his

hand; the motor function is strong, and the sensory and vascular exams are otherwise normal. The wrist radiographs are noted as shown in the picture.

Question: What is the most likely injury?

- A** Scaphoid fracture
- B** Lunate dislocation
- C** Perilunate dislocation
- D** No fracture or dislocation; normal X-ray
- E** 5th metacarpal fracture

See page 71 for Answer, Diagnosis, and Discussion.



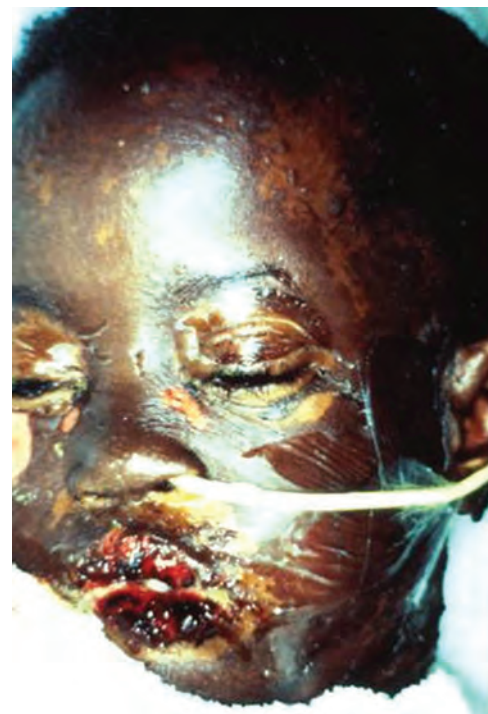Case 8 | Rash in a child with epilepsy

Alexander B. Baer, MD & Christopher P. Holstege, MD

Case presentation: A 3-year-old female with a history of epilepsy and taking phenytoin presents to the emergency department with a rapidly progressing, painful rash, inability to swallow secretions, and difficulty breathing. The rash began 5 days previously, at which time her mother noted mild skin tenderness, low-grade fever, anorexia, and malaise. The child also complained of headache and developed diarrhea. She had been seen previously by three different health care providers over the past 5 days; all diagnosed her with a viral exanthema. When the child's mother awoke on the morning of arrival to the emergency department, she found her child with marked progression of the rash pictured at right that now involves her mucus membranes diffusely. In the emergency department, her vitals are as follows: blood pressure 67/34 mmHg, pulse 160 beats/minute, respirations 38 breaths/minute, and temperature 38.5°C. She is intubated and pictured at right. Her laboratory studies demonstrate that she has both renal and hepatic dysfunction.

Question: Which of the following is correct regarding this child's condition?

- A** This child would be expected to have a positive Nikolsky's sign
- B** If this child had been started on antibiotics earlier, she would never have required intubation
- C** With proper treatment, this child's chances of survival are greater than 90%
- D** This is a primary dermatologic condition, with other organ involvement not expected



- E** She should be restarted on her phenytoin to avoid seizure complications

See page 72 for Answer, Diagnosis, and Discussion.