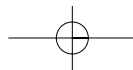
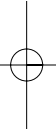
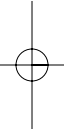
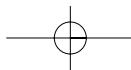
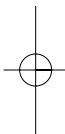
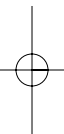
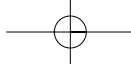


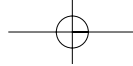
---

# Section 1

## Kidney and Ureter



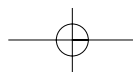
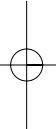
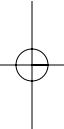


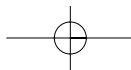
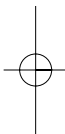
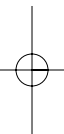
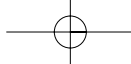


---

# Part 1.1

## Kidney and Upper Ureter





# Chapter 1

## Posterior Lumbotomy

*V. Pansadoro*

### Introduction

This technique was first published by H. Lurz in 1956 and is the author's method of choice for pyeloplasty whenever the laparoscopic approach is not possible. It is relatively easy to perform, demonstrate, and teach, with a short learning curve. There is limited exposure but it is good enough for the planned procedure.

### Patient counseling and consent

As for a routine surgical procedure.

### Indications

This procedure is indicated in surgical pyeloplasty and in approaches to the lumbar ureter.

### Limitation and risks

- Very high kidney.
- Very short patient.

### Contraindications

The technique is contraindicated in patients with previous cancer surgery, a horseshoe kidney, an anteriorly placed renal pelvis, and a history of previous surgery.

### Preoperative management

As routine for kidney surgery.

### Anesthesia

Blended, general, and peridural anesthesia.

### Special instruments/suture material

- Bookwalter self-retaining retractor.

### Operative technique

#### Anatomy

The lumbodorsal region is delineated by three bony structures: the iliac crest, the 12th rib, and the spinal processes. Between these three structures are the sacrospinalis muscle and the quadratus lumborum muscle. Two factors contribute to the originality of the Lurz approach: the incision is exactly on the quadratus lumborum muscle, which is situated in the center of the dorsolumbar region, and the operating field is widened by mobilization of the 12th rib after the costovertebral ligament is severed.

#### Patient's position

The position of the patient on the operating table is important and needs emphasis. It is characterized by three main features. The laterolateral axis makes a 45° angle with the operating table. It is not necessary for the table to be bent too much because the muscles do not need to be stretched; on the contrary, it is better if they are relaxed to allow easier retraction. The thorax is turned ventrally and the pelvis dorsally to allow a better opening of the dorsolumbar space. The legs and the upper arm are positioned as usual for a flank incision (Fig. 1.1).

#### Skin incision

Once the iliac crest, the 12th rib, and the spinal processes have been localized, the sacrospinalis muscle can be identified easily and the surgeon is able to localize the quadratus lumborum. This muscle goes from the medial part of the 12th rib to the mid third of the iliac crest; its upper third is under the sacrospinalis muscle. The skin incision is made over the quadratus lumborum muscle and begins at the costovertebral angle, over the lateral part of the sacrospinalis muscle, and with a slightly oblique course extends down to the iliac crest,

## 6 Kidney and Ureter

3–5 cm in front of the anterior margin of the sacrospinalis muscle (Fig. 1.2).

### Approach to the kidney

The incision of the muscular plane has the shape of a ‘Y’, with the sacrospinalis muscle contained between the two arms of the Y (Fig. 1.3). The incision of the muscular layers is a step-by-step procedure that should open the flank safely and exactly, and avoid any injury to the muscle and nerves present in this region. After the incision of the subcutaneous fat, the last fibers of the latissimus dorsi and the serratus dorsalis caudalis muscles are cut.

As the incision is deepened in its cranial portion, the posterior aspect of the lumbodorsal fascia is opened and the fibers of the sacrospinalis muscle are uncovered (Fig. 1.4). These fibers are easily identified by their craniocaudal direction. By cutting through the posterior lumbodorsal fascia around the sacrospinalis muscle, the surgeon completes the incision of the superficial arm of the Y. The sacrospinalis muscle is then prepared in its lateral and deep aspect and is retracted medially, uncovering the anterior aspect of the lumbodorsal fascia and, under this, the quadratus lumborum muscle (Fig. 1.5). When the fascia between these two muscles is incised, the deep arm of the Y is completed and the lumbodorsal fascia is severed caudally over the quadratus lumborum. Following strictly the direction of the fibers of this muscle, the surgeon completes the limb of the Y (Fig. 1.6). Retracting this muscle medially, we uncover the posterior aspect of the perirenal (Gerota’s) fascia and identify the iliohypogastric and ilioinguinal nerves. This fascia must be incised between these nerves, which are retracted to each side by two Richardson retractors, reaching the perirenal area (Fig. 1.7).

### Ureterolithotomy

In the event a ureterolithotomy must be performed, a deeper retractor should be inserted in the anterior aspect of the wound, so the inferior pole of the kidney can be lifted and moved cranially. Usually the ureter can be identified by simple inspection of the posterior aspect of the retroperitoneal space (Fig. 1.8). An oblique ureterotomy is preferred, and a 5/0 extramucosal running suture is used for closure. Of course the posterior approach is not indicated for stones lying lower than the iliac crest.

### Ureteropyeloplasty

When the need for a ureteropyeloplasty arises, the pelvis lies directly in the center of the incision, and the operation can be done without any further dissection. It is helpful to expose the renal sinus with the aid of a small peanut. The kidney can then be moved anteriorly and superficially with two Gil-Vernet retractors. Usually after this maneuver a self-retaining retractor can be inserted and the pyeloplasty can be done with great ease (Fig. 1.9).

### Wound closure

The wound closure is accomplished with interrupted 1/0 absorbable sutures, in one layer, on the lumbodorsal fascia. The quadratus lumborum and sacrospinalis muscles will regain their normal positions. Patients will usually experience an almost painless recovery.

### Tips

Before surgery obtain a KUB in a supine and standing position to evaluate the kidney’s mobility. Avoid fixed kidneys. By incising the costovertebral ligament the 12th rib can be retracted easily obtaining a wider exposure.

The surgeon who uses posterior lumbotomy must learn how to get the best exposure with this relatively small incision. During the opening phase, two Richardson retractors are used, and after the renal sinus has been prepared, two Gil-Vernet sinus retractors are essential to bring the kidney into the best position. Only then is a self-retaining retractor used to provide the best exposure, with the kidney lifted and positioned in the center of the incision.

### Postoperative care

As routine for kidney surgery.

### Complications

Care must be taken not to injure the ileoinguinal and ileohypogastric nerves to avoid secondary anesthesia of the corresponding region. Temporary hypotonus of muscles of the anterolateral abdominal wall, caused by stretching of the corresponding nerves, may happen.

### Troubleshooting

The patient’s positioning is of the utmost importance to get the best from the incision. The posterior lumbotomy is a fast, easy, relatively painless, and minimally traumatic approach to the kidney and upper ureter but the working space is more limited than usual. The surgeon who uses the posterior lumbotomy technique should avoid using it for the wrong indications.

### Results

The muscle-sparing incision, lack of postoperative pain, absence of postoperative laparocoele, and short hospitalization are the rewards of this approach.

### To do

It is the perfect incision for a skinny patient, with a mobile kidney and a posteriorly placed dilated pelvis.

### Not to do

The surgeon who uses this approach should know the limits of the incision and use it for the right indications.

### References

- 1 Bergmann EV. Über Nierenextirpation. Berl Klin Wochenschr 1885;39:46–8.
- 2 Gil-Vernet J. New surgical concept in removing renal calculi. Urol Int 1965;20:255–88.
- 3 Guyon F. Leçons cliniques sur les Maladies des Voies Urinaires. J.B. Ballière, Paris, 1881.
- 4 Israel J. Ein Fall von Nierenextirpation. Berl Klin Wochenschr 1883;37:689.
- 5 Lury H. Ein muskelschonender Lumbalschnitt zur Freilegung der Niere. Chirurg 1956;27:125–8.
- 6 Lurz L, Lurz H. Die Eingriffe an den Harnorganen, Nebennieren und männlichen Geschlechtsorganen. In: Allgemeine und spezielle chirurgische Operationslehre, 2nd edn (Guleke N, Zenker R, eds). Springer Verlag, Berlin, 1961.
- 7 Lutzeyer Wl, Lymberoupoulos S. Der Lumbodorsale Zugang zur Niere (Lurz): Indikation, klinische Erfahrung, und kritische Beurteilung. Urologe A 1970;9:324–9.
- 8 Pansadoro V. La via posteriore nella Chirurgia del Rene e dell'Uretere. Atti Soc Ital Urol 1977:414–20.
- 9 Rosenstein P. Ein funktioneller Lumbalschnitt zur Freilegung der Niere. Z Urol Chir 1925;7:119–26.
- 10 Sigel A, Held L. Die Zugangswege der Nierenchirurgie. Urologe A 1963;2:144–53.
- 11 Simon G. Extirpation einer Niere am Menschen. Dtsch Klin 1870;22:137–9.

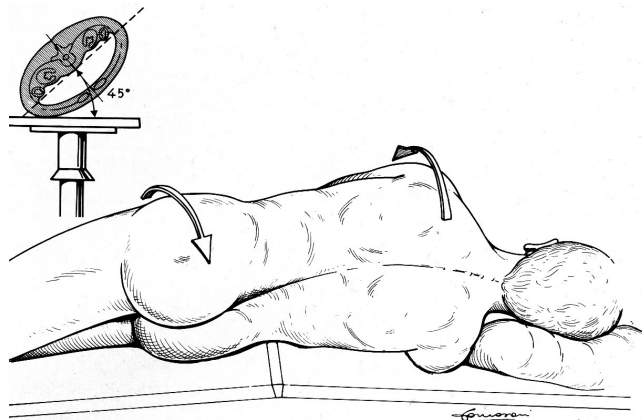


Figure 1.1 Position of the patient on the operating table.

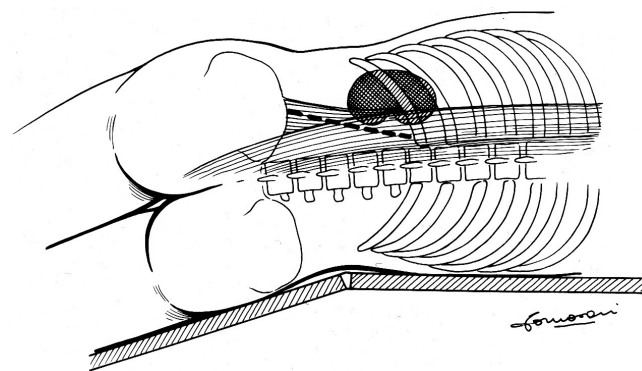


Figure 1.2 Skin incision.

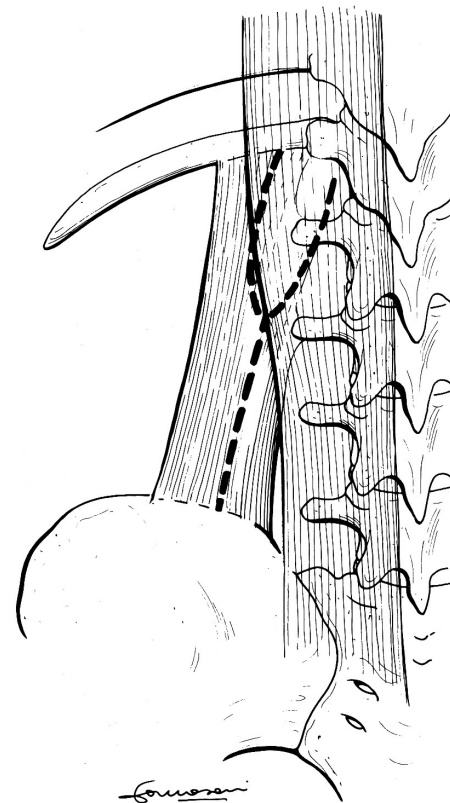
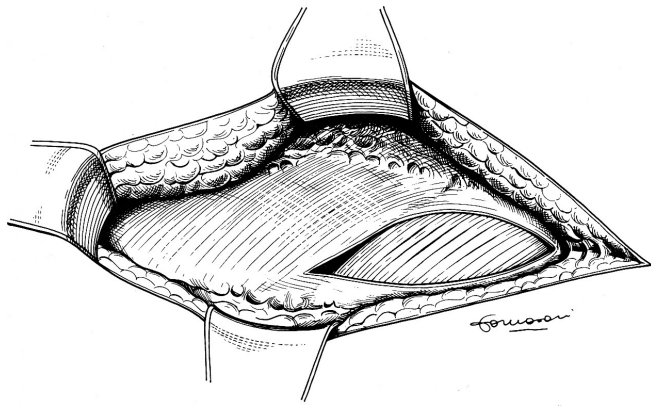
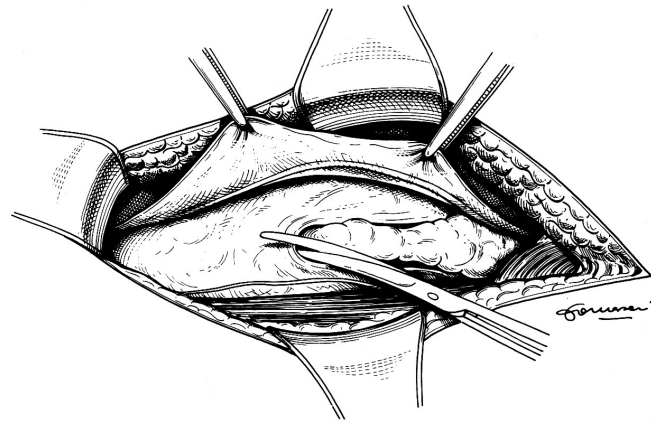


Figure 1.3 The approach to the kidney has the shape of a 'Y'.

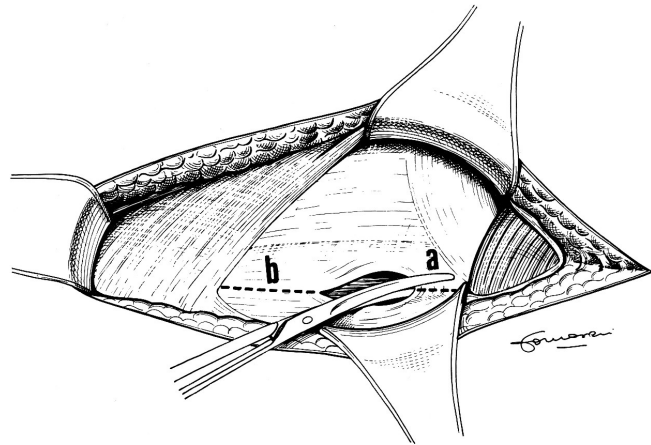
8 Kidney and Ureter



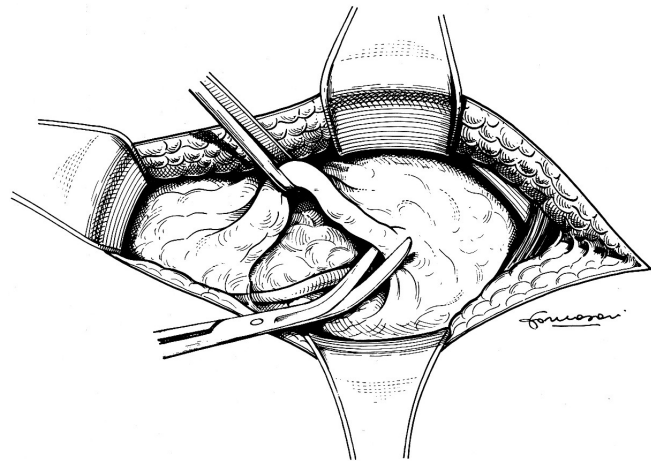
**Figure 1.4** By incising the superficial arm of the 'Y', the fibers of the sacrospinalis muscle are uncovered.



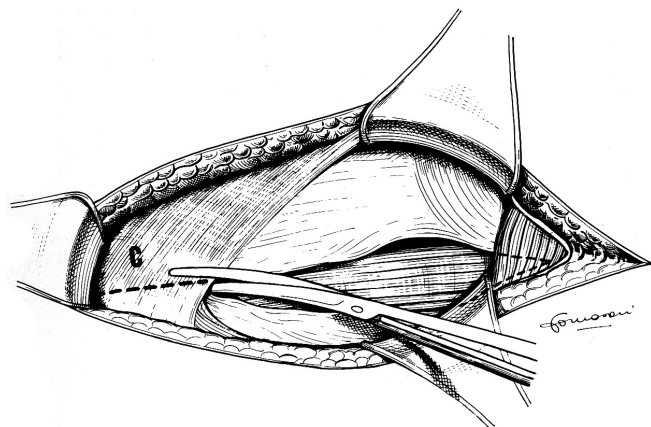
**Figure 1.7** The iliohypogastric and ilioinguinal nerves are exposed, and the perineal space is entered between the two.



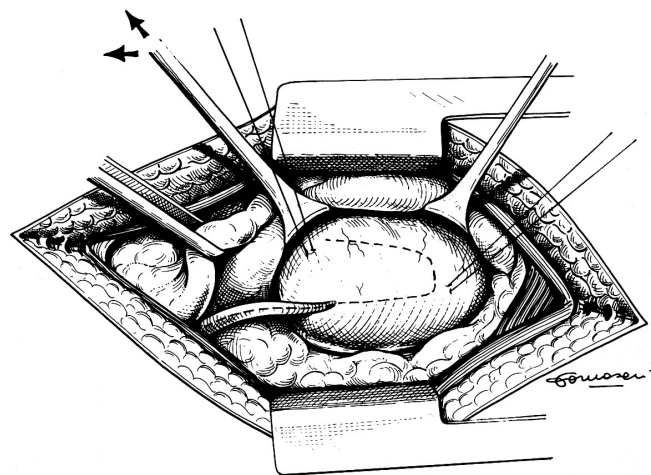
**Figure 1.5** When the sacrospinalis muscle is retracted medially, the quadratus lumborum muscle is exposed under the deep aspect of the lumbodorsal fascia (a-b, the costovertebral ligament).



**Figure 1.8** The lumbar ureter is usually easy to identify with proper anterior retraction.



**Figure 1.6** Incision of the limb of the 'Y' over the quadratus lumborum (c, the lumbodorsal fascia).



**Figure 1.9** The proper use of two sinus retractors allows visualization of the entire renal pelvis.