

1

CHAPTER 1

Clinical skills, physical signs and anatomy

'There's something wrong with my left leg, and I'm not walking properly.' In this chapter we are going to use this clinical problem to remind us:

- how important the details of the history are in making a neurological diagnosis, especially the clear definition of how the problem has evolved with respect to time;
- of the components of the nervous system involved in normal movement, their anatomy (which isn't complicated), and the physical signs produced by lesions in the various components;
- of the common patterns of neurological malfunction, affecting any part of the body, such as a leg;
- of the importance of the patient's response to his malfunctioning limb, in defining the size and nature of the whole illness;
- of the reliability of the clinical method in leading us to a diagnosis or differential diagnosis and management plan;
- how important it is to explain things clearly, in language the patient and relatives can understand.

At the end of the chapter are a few brief case histories, given to illustrate the principles which are outlined above and itemized in detail throughout the chapter.

Our response to a patient telling us that his left leg isn't working properly must not just consist of the methodical asking of many questions, and the ritualistic performance of a complex, totally inclusive, neurological examination, hoping that the diagnosis will automatically fall out at the end. Nor must our response be a cursory questioning and non-focused examination, followed by the performance of a large battery of highly sophisticated imaging and neurophysiological tests, hoping that they will pinpoint the problem and trigger a management plan.

No, our response should be to listen and think, question and think, examine and think, all the time trying to match what the patient is telling us, and the physical signs that we are eliciting, with the common patterns of neurological malfunction described in this chapter.

History

We need all the details about the left leg, all the ways it is different from normal. If the patient mentions wasting, our ideas will possibly start to concentrate on lower motor neurone trouble. We will learn that if he says it's stiff, our thoughts will move to the possibility of an upper motor neurone or extrapyramidal lesion. If he can't feel the temperature of the bath water properly with the other (right) leg, it is clear that we should start to think of spinal cord disease. If it makes his walking unsteady; we may consider a cerebellar problem. Different adjectives about the leg have definite diagnostic significance. We will ask the patient to use as many adjectives as he can to describe the problem.

Details of associated symptoms or illnesses need clarification. 'There's nothing wrong with the other leg, but my left hand isn't quite normal'—one starts to wonder about a hemiparesis. 'My left hand's OK, but there's a bit of similar trouble in the right leg'—we might consider a lesion in the spinal cord. 'I had a four-week episode of loss of vision in my right eye, a couple of years ago'—we might wonder about multiple sclerosis. 'Mind you, I've had pills for blood pressure for many years'—we might entertain the possibility of cerebrovascular disease. These and other associated features are important in generating diagnostic ideas.

Very important indeed in neurological diagnosis is detail of the mode of onset of the patient's symptoms. How has the left leg problem evolved in terms of time? Let's say the left leg is not working properly because of a lesion in the right cerebral hemisphere. There is significant weakness in the left

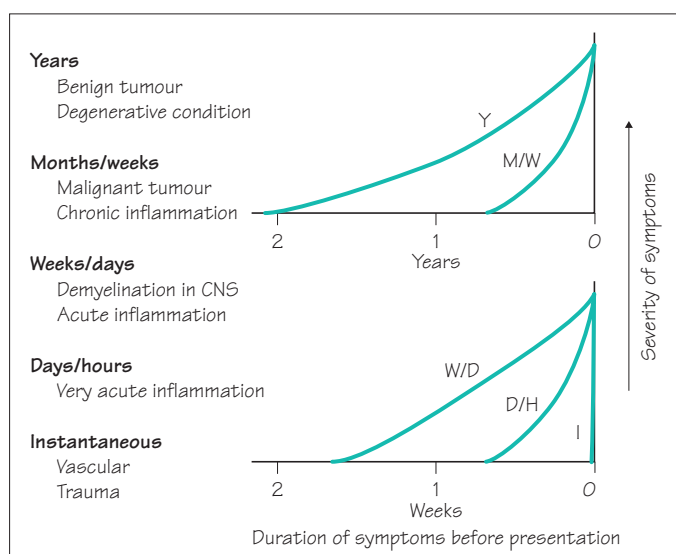
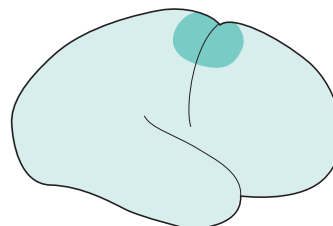


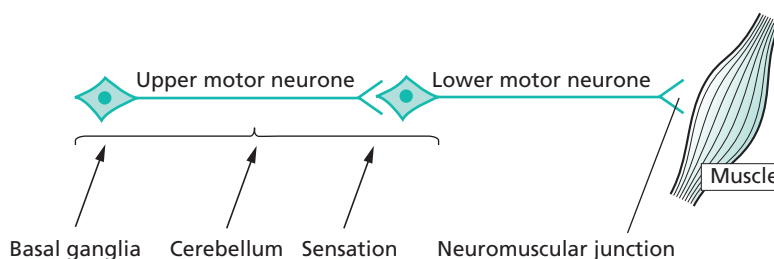
Fig. 1.1 The patient's history indicates the probable pathology.

leg, slight weakness in the left hand and arm, some loss of sensation in the left leg and no problem with the visual fields. This same neurological deficit will be present whatever the nature of the pathology at this site. If this part of the brain isn't working there is an inevitability about the nature of the neurological deficit.

It is the history of the mode of evolution of the neurological deficit which indicates the nature of the pathology (Fig. 1.1).

Components of the nervous system required for normal function; their anatomy; physical signs indicating the presence of a lesion in each component; and the common patterns in which things go wrong

The basic components of the nervous system required for normal movement are shown on the simple diagram below.

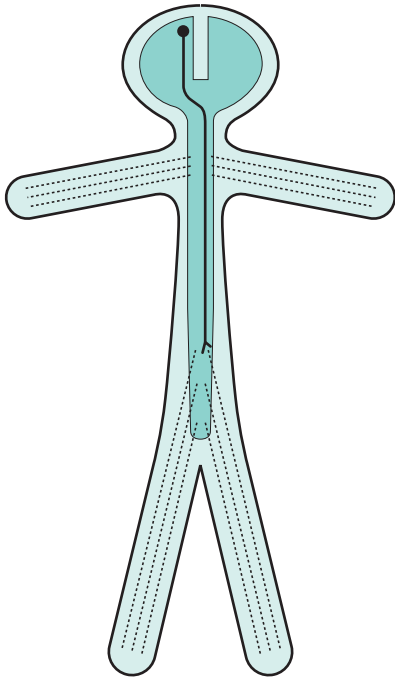


Lesions along the primary motor pathway, UMN–LMN–NMJ–M, are characterized by weakness or paralysis. We will see that the characteristics of the weakness are different in each instance; for example, UMN weakness has different characteristics from LMN weakness. Knowledge of these characteristics is fundamental to clinical neurology.

Normal basal ganglia, cerebellar and sensory function is essential background activity of the nervous system for normal movement. Lesions in these parts of the nervous system do not produce weakness or paralysis, but make movement imperfect because of stiffness, slowness, involuntary movement, clumsiness or lack of adequate feeling.

So we will be questioning and examining for weakness, wasting, stiffness, flaccidity, slowness, clumsiness and loss of feeling in our patient's left leg. This will help to identify in which component of the nervous system the fault lies.

To make more sense of the patient's clinical problem, we have to know the basic anatomy of the neurological components, identified above, in general terms but not in every minute detail. This is shown on the next three pages.

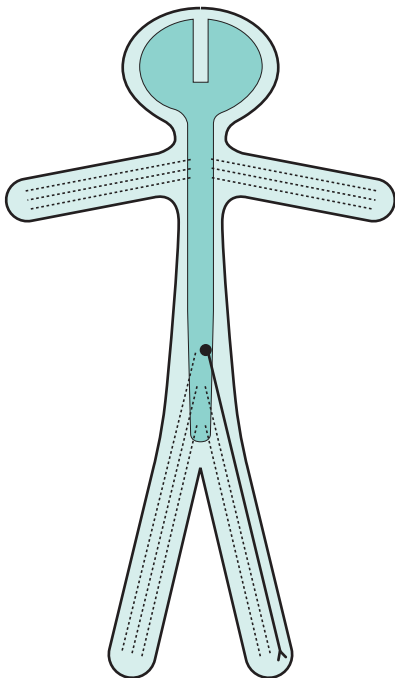


An upper motor neurone involved in left leg movement

Cell body in motor cortex of right cerebral hemisphere

Axon:

- descends through right internal capsule
- crosses from right to left in the medulla
- travels down the spinal cord on the left side in lateral column
- synapses with a lower motor neurone innervating left leg musculature

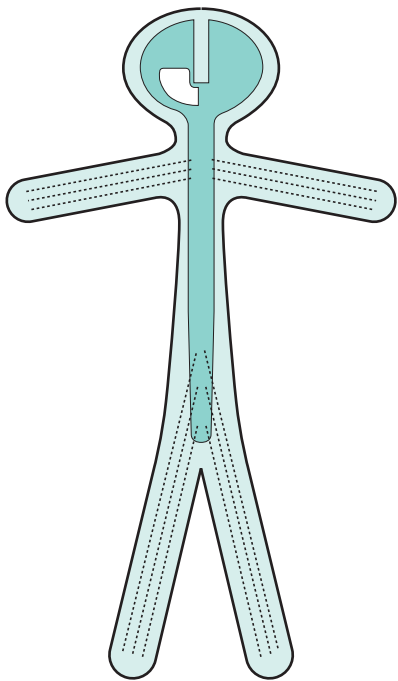


A lower motor neurone involved in left leg movement

Cell body at the lower end of the spinal cord on the left side

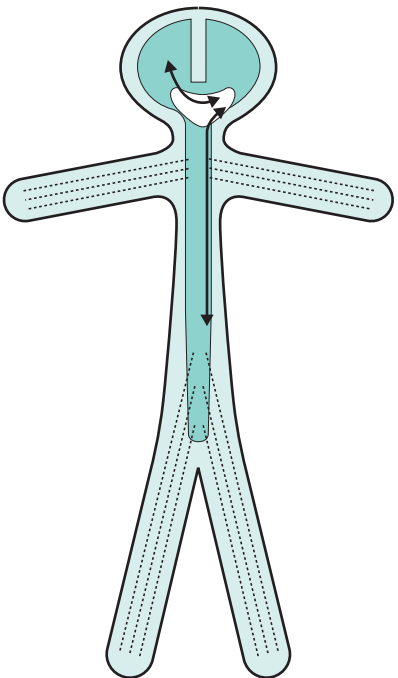
Axon:

- leaves the spine within a numbered spinal nerve
- travels through the lumbosacral plexus
- descends within a named peripheral nerve
- synapses with muscle at neuromuscular junction

**Basal ganglion control of the left leg**

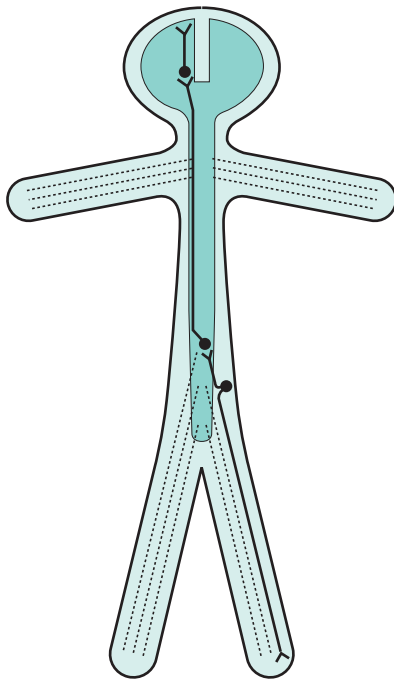
The structures involved in extrapyramidal control of the left side of the body reside in the basal ganglia and cerebral peduncle on the right

Basal ganglion function is contralateral

**Cerebellar control of the left leg**

The left cerebellar hemisphere has two-way connection with the right cerebral hemisphere and the left side of the body, via the cerebellar peduncles, brainstem and spinal cord

Cerebellar function is ipsilateral



Pain and temperature sensation in the left leg

Third sensory neurone:

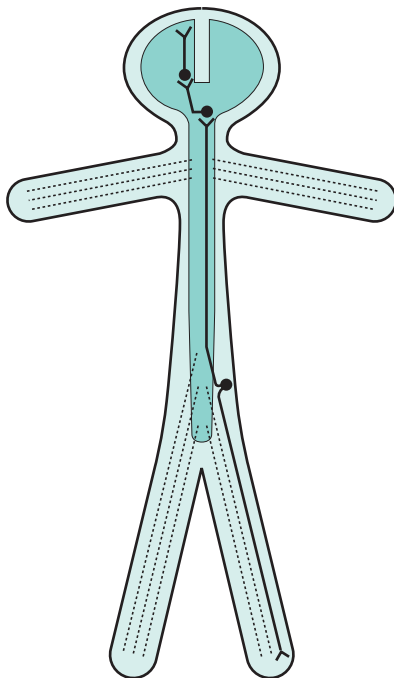
- cell body in thalamus
- axon travels to sensory cortex

Second sensory neurone:

- cell body in lumbar spinal cord on the left
- axon crosses to the right and ascends to thalamus in lateral column of spinal cord

Dorsal root ganglion cell:

- distal axon from the left leg, via peripheral nerve, lumbosacral plexus and spinal nerve
- proximal axon enters cord via dorsal root of spinal nerve, and relays with second sensory neurone



Position sense in the left leg

Third sensory neurone:

- cell body in thalamus
- axon travels to sensory cortex

Second sensory neurone:

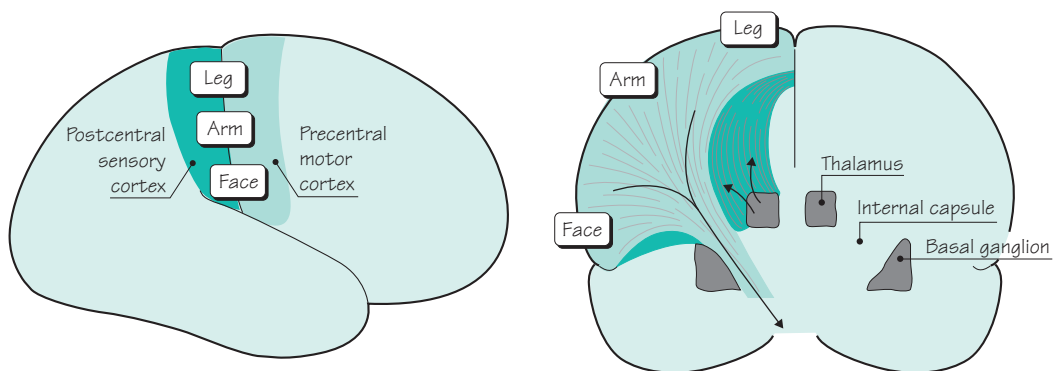
- cell body in gracile or cuneate nucleus on left side of medulla, axon crosses to the right side of medulla and ascends to thalamus on the right

Dorsal root ganglion cell:

- distal axon from left leg, via peripheral nerve, lumbosacral plexus and spinal nerve
- proximal axon enters cord, ascends in posterior column on the left to reach the second sensory neurone in left lower medulla

The final piece of anatomical knowledge which is helpful for understanding the neurological control of the left leg, is a little more detail about motor and sensory representation in the brain. The important features to remember here are:

- the motor cortex is in front of the central sulcus, and the sensory cortex is behind it;
- the body is represented upside-down in both the motor and sensory cortex;
- the axons of the upper motor neurones in the precentral motor cortex funnel down to descend in the anterior part of the internal capsule;
- the axons of the 3rd sensory neurone in the thalamus radiate out through the posterior part of the internal capsule to reach the postcentral sensory cortex.

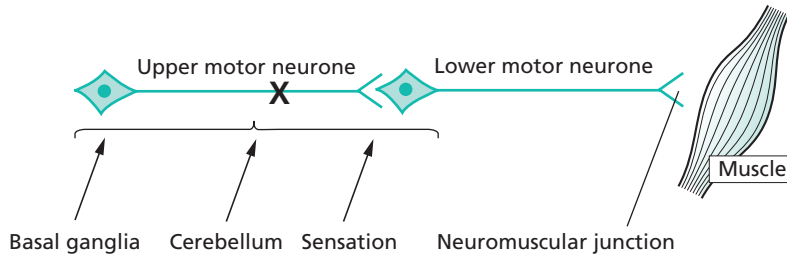


Having reviewed the components of the nervous system involved in normal function of the left leg, and their basic anatomy, we now need more detail of:

- the clinical features of failure in each component;
- the common patterns of failure which are met in clinical practice.

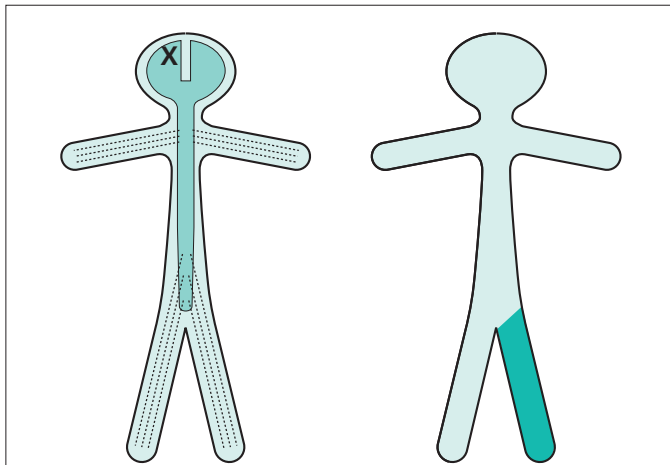
The next section of this chapter reviews these features and patterns.

Upper motor neurone



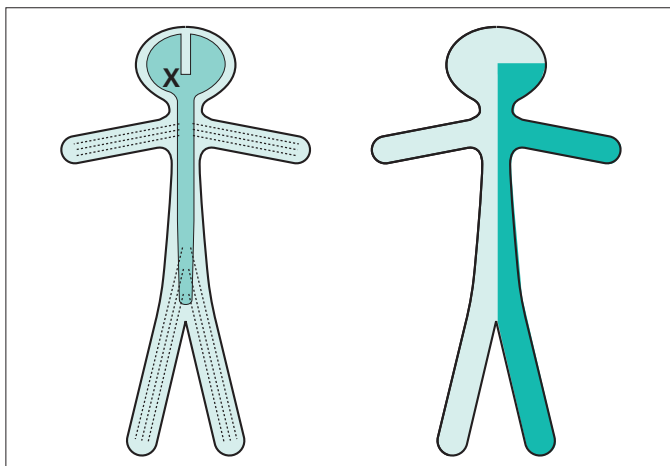
Characteristic of upper motor neurone lesions:

- no wasting;
- increased tone of clasp-knife type;
- weakness most evident in anti-gravity muscles;
- increased reflexes and clonus;
- extensor plantar responses.



Contralateral monoparesis

A lesion situated peripherally in the cerebral hemisphere, i.e. involving part of the motor homunculus only, produces weakness of part of the contralateral side of the body, e.g. the contralateral leg. If the lesion also involves the adjacent sensory homunculus in the postcentral gyrus, there may be some sensory loss in the same part of the body.

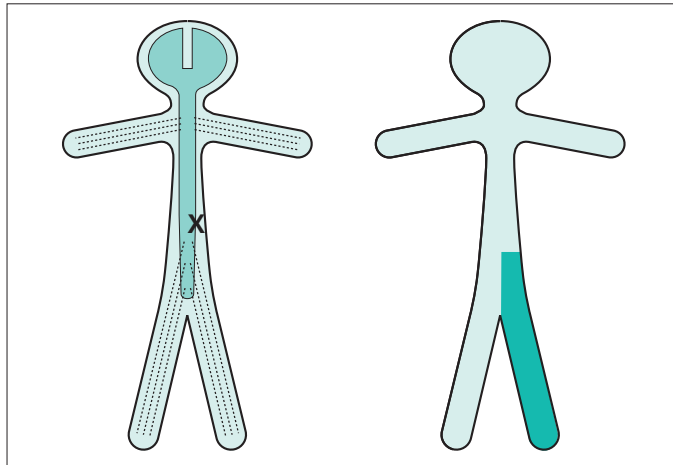


Contralateral hemiparesis

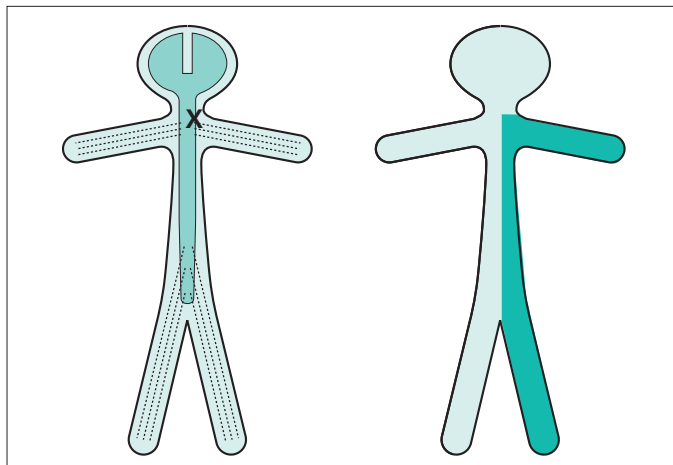
Lesions situated deep in the cerebral hemisphere, in the region of the internal capsule, are much more likely to produce weakness of the whole of the contralateral side of the body, face, arm and leg. Because of the condensation of fibre pathways in the region of the internal capsule, such lesions commonly produce significant contralateral sensory loss (hemianaesthesia) and visual loss (homonymous hemianopia), in addition to the hemiparesis.

Ipsilateral monoparesis

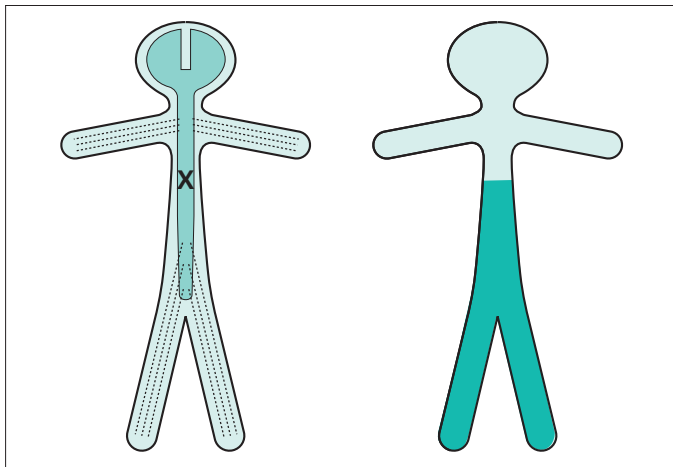
A unilateral lesion in the spinal cord below the level of the neck produces upper motor neurone weakness in one leg. There may be posterior column (position sense) sensory loss in the same leg, and spinothalamic (pain and temperature) sensory loss in the contralateral leg. This is known as dissociated sensory loss, and the whole picture is sometimes referred to as the Brown-Séquard syndrome.

**Ipsilateral hemiparesis**

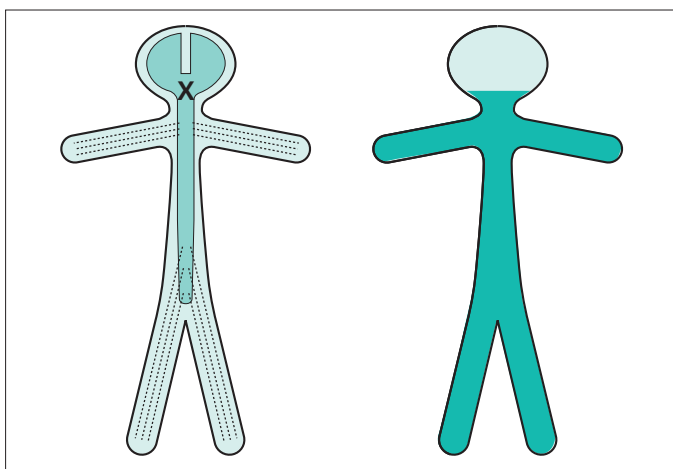
A unilateral high cervical cord lesion will produce a hemiparesis similar to that which is caused by a contralateral cerebral hemisphere lesion, except that the face cannot be involved in the hemiparesis, vision will be normal, and the same dissociation of sensory loss (referred to above) may be found below the level of the lesion.



A spinal cord lesion more usually causes upper motor neurone signs in both legs, often asymmetrically since the pathology rarely affects both sides of the spinal cord equally.



Paraparesis, if the lesion is at or below the cervical portion of the spinal cord.

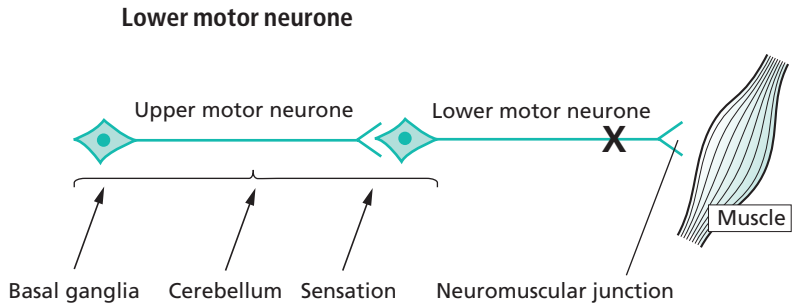


Tetraparesis or quadriplegia, if the lesion is in the upper cervical cord or brainstem.

Lesions anywhere between the midbrain and lower spinal cord may, in addition, involve ascending sensory pathways and fibre tracts involving sphincter function. There may therefore be sensory loss below the level of the lesion, and the possibility of bladder, bowel and sexual symptoms.

There may be physical signs which indicate the level of the lesion very accurately:

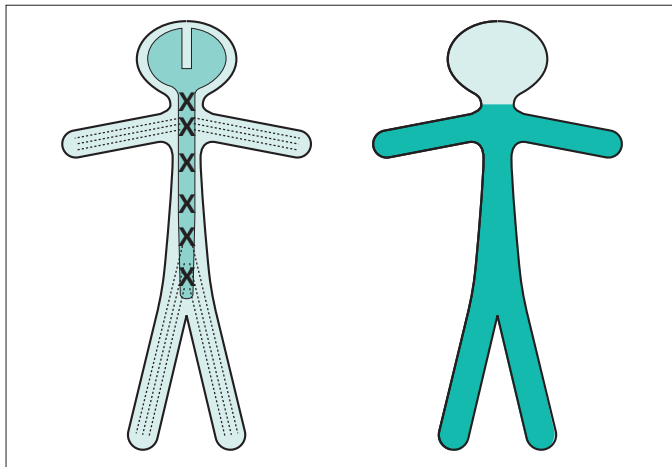
- LMN signs, loss of reflexes, dermatome pain or sensory loss, at the level of the lesion in the spinal cord;
- cerebellar signs or cranial nerve palsies when the lesion is in the midbrain, pons or medulla.



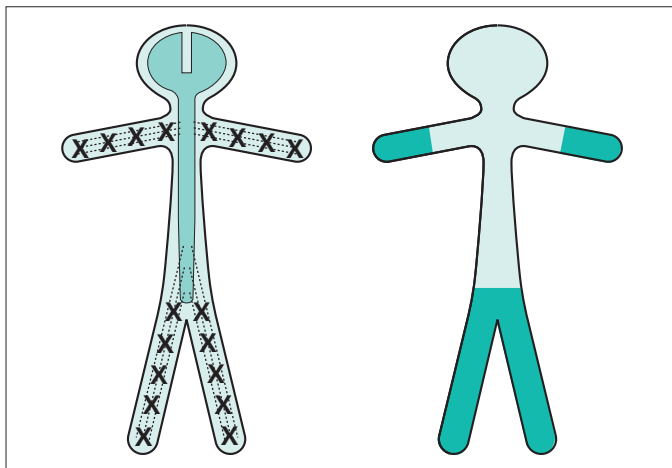
Characteristics of lower motor neurone lesions:

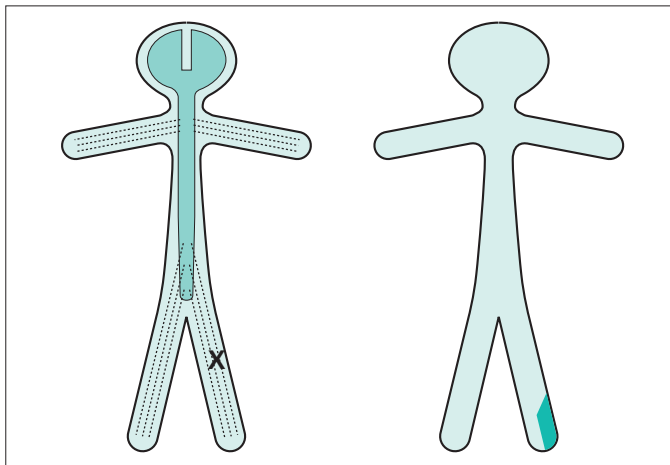
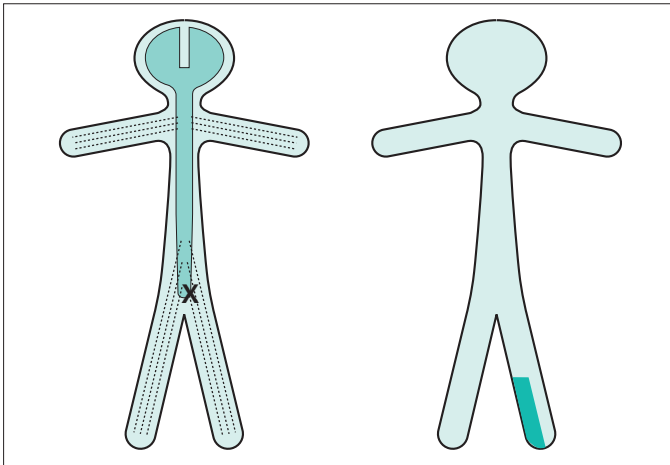
- wasting;
- fasciculation;
- decreased tone (i.e. flaccidity);
- weakness;
- decreased or absent reflexes;
- flexor or absent plantar responses.

Generalized LMN weakness may result from pathology affecting the LMNs throughout the spinal cord and brainstem, as in motor neurone disease or poliomyelitis. Generalized limb weakness (proximal and distal), trunk and bulbar weakness characterize this sort of LMN disorder.



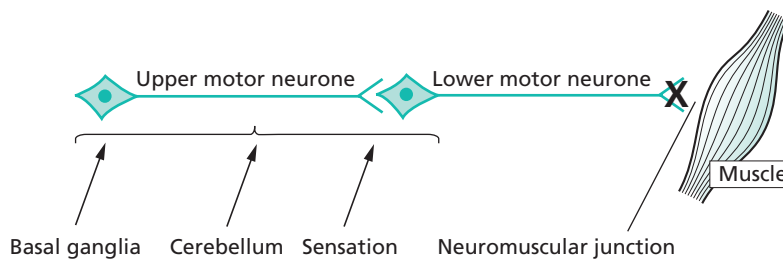
Generalized LMN weakness may also result from widespread damage to the axons of the LMNs. This is the nature of peripheral neuropathy (also called polyneuropathy). The axons of the dorsal root sensory neurones are usually simultaneously involved. The LMN weakness and sensory loss tend to be most marked distally in the limbs.





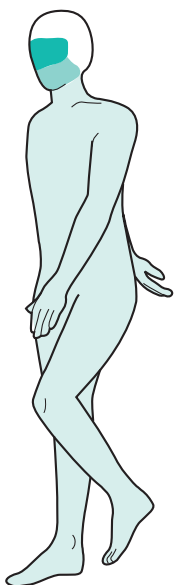
LMN weakness may be confined to the distribution of one spinal root (above) or one individual peripheral nerve (below). In such circumstances, the LMN signs are found only in the muscles supplied by the particular nerve root or peripheral nerve in question. Almost always there is sensory impairment in the area supplied by the nerve or nerve root. Examples of such lesions are an S1 nerve root syndrome caused by a prolapsed intervertebral disc, or a common peroneal nerve palsy caused by pressure in the region of the neck of the fibula.

Neuromuscular junction



The classic disease of the neuromuscular junction is myasthenia gravis. Characteristics of myasthenia gravis:

- uncommon;
- no wasting;
- tone normal;
- weakness;
- fatiguability;
- reflexes normal;
- positive response to anticholinesterase.



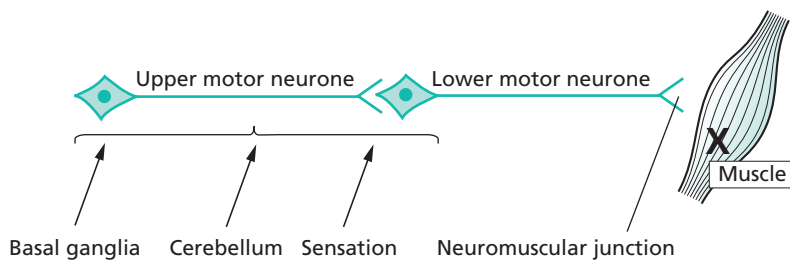
The pattern of muscle involvement in this rare disease:

- ocular muscles common:
 - ptosis;
 - diplopia;
- bulbar muscles fairly common:
 - dysarthria;
 - dysphagia;
- trunk and limb muscles less common:
 - limb weakness;
 - trunk weakness;
 - breathing problems.

More common paralysis due to neuromuscular blockade is that which is produced by anaesthetists during operative surgery.

Myasthenia gravis would not be a likely diagnosis in a patient presenting with left leg malfunction.

Muscle

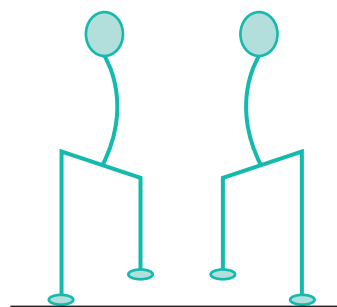


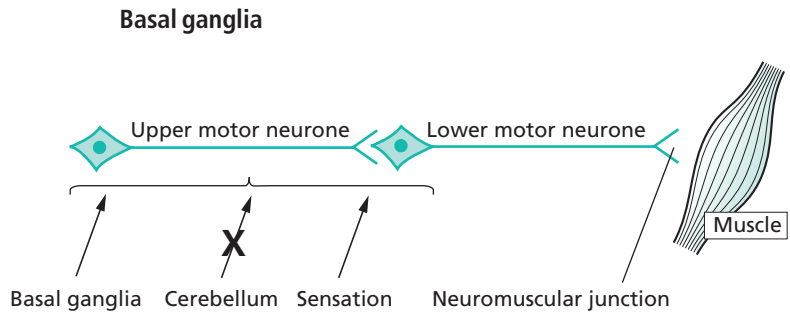
Characteristics of primary muscle disease:

- uncommon;
- wasting;
- no fasciculation;
- weakness;
- tone normal or reduced;
- reflexes normal or reduced.

Proximal muscle weakness typifies most primary muscle disease. The patient has difficulty in lifting his arms above shoulder level, and in rising from a chair into the standing position. He needs to use his arms to help him do this. In the standing position, the trunk muscle weakness often allows an abnormal amount of extension of the lumbar spine, so that the abdomen protrudes forwards. When walking, the abdominal and pelvic muscle weakness allow downward tilting of the pelvis when the leg is off the ground. This is known as Trendelenburg weakness.

A diagnosis of muscle disease would be unlikely in a patient presenting with unilateral leg malfunction. This is partly because muscle disease is rare, and partly because it usually produces bilateral symmetrical weakness.





Two main syndromes, each with different characteristics:

1. Parkinson's disease:

- common;
- tremor at rest;
- increased tone;
- bradykinesia;
- flexed posture.

2. Involuntary movements:

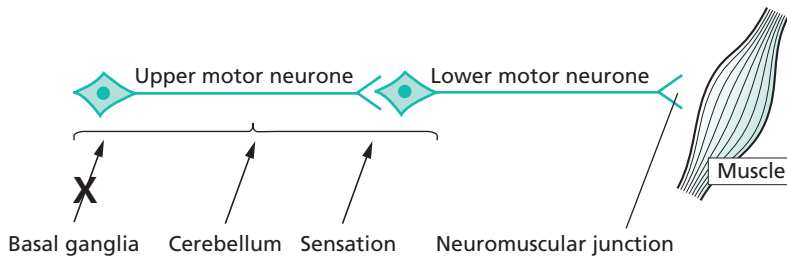
- uncommon;
- involuntary movements at rest and during action;
- tone increased, normal or reduced;
- normal speed of movement;
- all sorts of postural abnormalities.

No weakness in either.

These syndromes may be unilateral and are commonly asymmetrical, the pathology being in the basal ganglia of the contralateral cerebral hemisphere.

It is not at all improbable that a patient complaining of left leg malfunction, and difficulty in walking, might be presenting with Parkinson's disease.

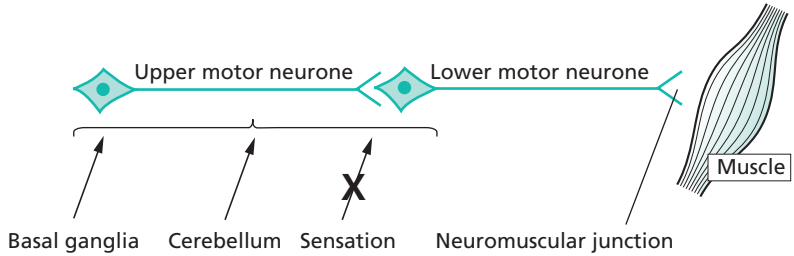
Cerebellum



Characteristics of cerebellar lesions are:

1. Incoordination of muscle activity:
 - in the head: nystagmus, dysarthria;
 - in the arms: finger–nose ataxia, kinetic tremor, difficulty with rapid alternating movements (dysdiadochokinesia);
 - in the legs: heel–knee–shin ataxia, gait ataxia, falls.
2. There is no weakness. (Alcohol in large doses impairs cerebellar function. Intoxicated people show all the features of muscular incoordination mentioned above, but may be very strong.)
3. In a unilateral cerebellar lesion, the neurological deficit is ipsilateral to the side of the lesion. A patient complaining of malfunction of the left leg due to a left cerebellar lesion would have heel–knee–shin ataxia most marked in the left leg, and gait ataxia with deviation to the left. There might also be left arm cerebellar signs, and nystagmus most marked looking to the left.

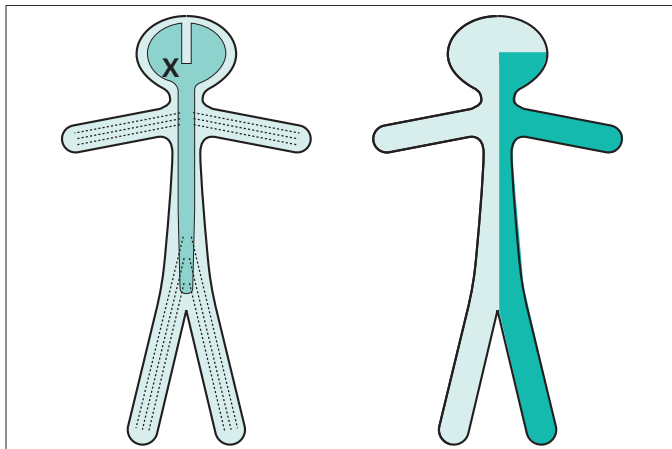
Sensation



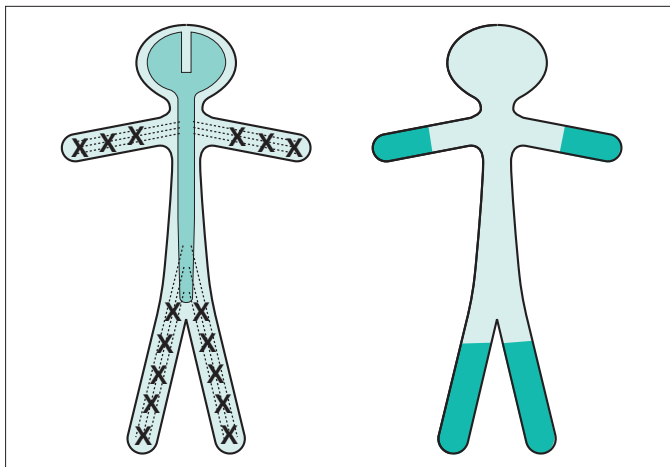
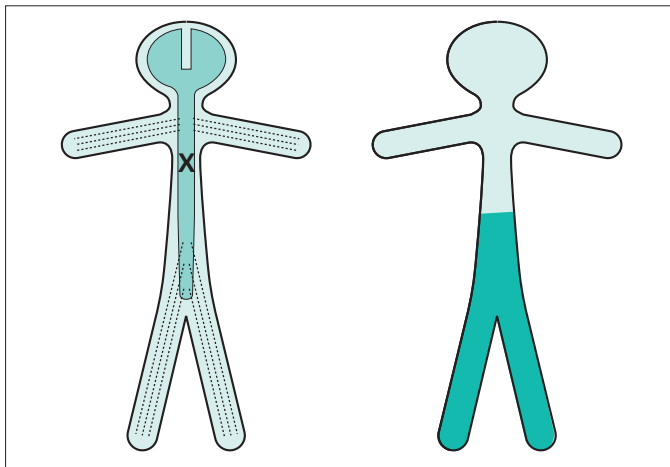
Characteristics of movement in the presence of sensory loss:

- ataxia or clumsiness of movement due to loss of sense of position mainly, but also due to loss of touch sensation;
- partial compensation by active monitoring of movement by the eyes;
- no weakness.

There are three main clinical syndromes where sensory loss may play an important role in impairing movement and function.



Cerebral hemisphere lesions: impaired accurate movements of the contralateral limbs because central registration of limb position is lost.

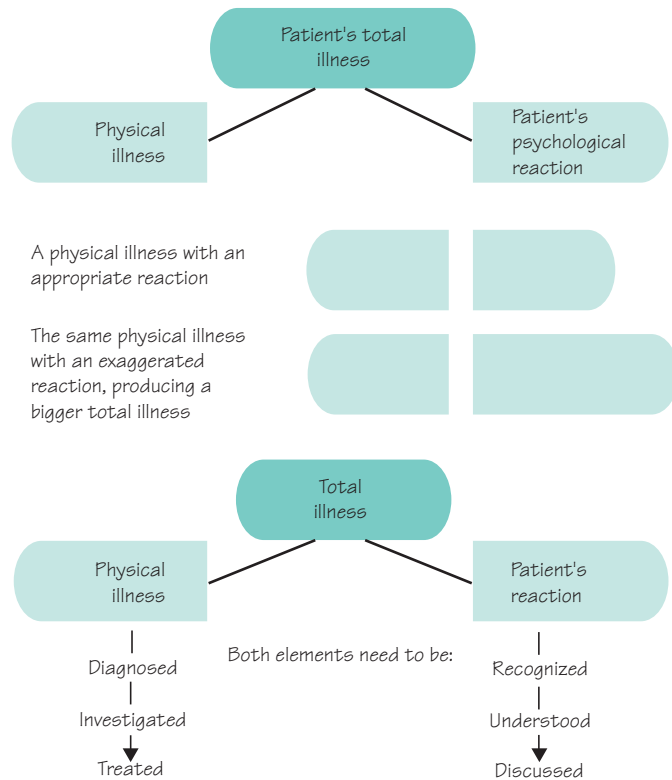


Loss of proprioceptive sense in the legs and feet may occur as a result of either spinal cord disease (above) or peripheral neuropathy (below). The loss of sense of position gives rise to clumsiness of leg movement when walking, unsteadiness, and the need to watch the feet and floor carefully. There is marked unsteadiness and falling when vision cannot compensate, e.g. in the dark, in the shower, when washing the face, when putting clothes over the head. Romberg's sign (stance steady with eyes open, but unsteady with eyes closed) is positive in such patients.

The patient's response to his symptoms

Hopefully the nature of the patient's physical illness causing the left leg malfunction will emerge from the history and examination, carried out against this background knowledge of common patterns of neurological failure. Just as important, and to be conducted during the same history and examination, is an evaluation of the patient's response to the illness. How much is the imperfect function in the left leg bothering him? What are the practical consequences of having the problem in his everyday life? What does he think is the matter? Has he worried about a really serious cause? Is he anticipating recovery or further disability?

In this section we recognize that the total illness in any patient is the sum of the physical illness plus the patient's psychological reaction to the physical illness. The latter may be appropriate and entirely understandable. Sometimes, however, the reaction is exaggerated for some reason, making the whole illness a bigger one for the patient, his family and the medical staff looking after him. Recognition of the two elements of illness, and the management of both, are particularly appropriate in patients with neurological disorders.



Diagnosis, explanation and planning

A diagnosis, or differential diagnosis, for the patient's left leg problem is established, and a good feel for the level of patient concern has been achieved. Tests to confirm the diagnosis often need to be arranged before the diagnosis is finally established. Careful explanation of the differential diagnosis, and careful explanation of the tests to the patient, often with another family member present, is important. Diagnostic certainty may be achieved nowadays as a result of sophisticated scanning, neurophysiological tests and laboratory investigations, but some patients are apprehensive about such investigations and others are very apprehensive about what diagnosis may emerge as a result of them. The need for excellent communication and patient explanation reaches its height when the final diagnosis and management plan are discussed with the patient (and family member). Plenty of opportunity should be given for the patient and family to express their feelings at this stage.

The following five points are helpful from the communication point of view. The doctor should show in an open and friendly way, that:

1. there is always enough time;
2. there is always enough concern;
3. enough privacy is always available for the patient to speak freely and openly;
4. there is always an opportunity to talk to the patient's family;
5. he can talk to the patient and family in language they can easily understand.

Investment of such time and effort with a patient who has a neurological illness is always worthwhile. The more the patient and family trust, like and respect the doctor, the greater will be their confidence in the diagnosis and their compliance with the management. It is clearly a shame if a bright doctor has established the correct explanation of our patient's left leg problem, but communicates very poorly and establishes little rapport with the patient. The patient may be far from satisfied, and seek help elsewhere.

Patience with patients

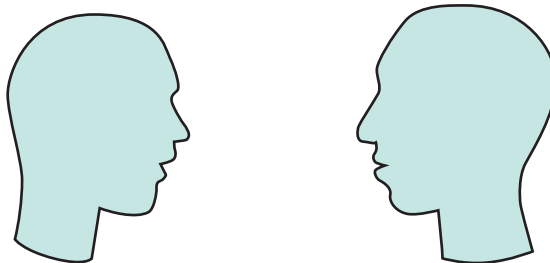
Time

Concern

Privacy

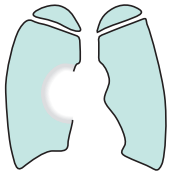
Relatives

Language



Some typical case histories

Let's create a few different neurological scenarios which might develop from a patient presenting with a malfunctioning left leg, to show the range of different outcomes.



A semi-retired groundsman of 68 years, retired, smoker, has noticed gradually progressive weakness in the left leg for 6–8 weeks. Both he and his wife are worried, mainly

because they have an imminent 4-week trip to visit their son and family in Australia.

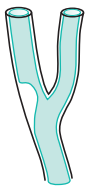General examination is normal.

Neurological examination reveals mild UMN signs in the left arm and major UMN signs in the left leg.

A chest X-ray shows a mass at the right hilum and a CT brain scan shows two mass lesions, one (apparently producing no problem) in the left frontal region, and one in the region of the precentral motor

cortex high up in the right fronto-parietal region. Bronchoscopy confirms that the right hilar lesion is a bronchial carcinoma.

In discussion, it transpires that the patient had a strong notion that this was what was wrong from fairly early on, confirmed for him when he was asked to have a chest X-ray; that he would like to take advantage of the transient improvement produced by large-dose steroids, reducing the oedema around the brain lesions; and that, although not rich, he could afford hospital care or urgent flights home from Australia if required. They would continue with their planned visit, and cope as best they could when the inevitable worsening of his condition occurred, hopefully when they have returned home.



A widow of 63 years, who has been on treatment for high blood pressure for some years, developed sudden weakness of the left leg whilst washing up at 9 a.m. She fell over and had to call the doctor by shuffling across the floor of the house to the telephone. Now, 3 days later, there has been moderate recovery so that she can walk but she feels far from safe.

Her father had hypertension and died after a stroke.

General examination reveals a BP of 200/100, a right carotid arterial bruit, a right femoral arterial bruit and hypertensive retinopathy.

Neurological examination reveals mild UMN signs in the left arm and major UMN signs in the left leg.

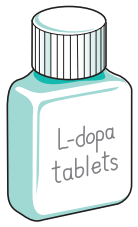Chest X-ray and ECG both confirm left ventricular hypertrophy.

Blood tests are all normal.

CT brain scan shows no definite abnormality.

Carotid doppler studies show critical stenosis of the lower end of the right internal carotid artery.

A small stroke, from which she seems to be recovering satisfactorily, is the diagnosis discussed with her. The patient is happy to see the physiotherapist to help recovery. She is worried about the degree of recovery from the point of view of driving, which isn't safe in her present car (which has a manual gear shift). She understands she is predisposed to future strokes because of her hypertension and carotid artery disease. She is prepared to take preventative drug treatment in the form of aspirin, blood pressure pills and a statin. She doesn't smoke. She wants to have a good talk to her doctor son before submitting herself to carotid endarterectomy, although she understands the prophylactic value of this operation to her.



A golf course groundsman of 58 years gives a history of lack of proper movement of the left leg, making his walking slower. It has been present for 6 months and has perhaps worsened slightly. Most of his work is on a tractor so the left leg problem hasn't really

affected him at work. He feels he must have a nerve pinched in his left leg somewhere.

General examination is normal.

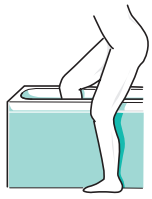Neurological examination reveals a rather fixed facial expression, tremor of the lightly closed eyes, a little cogwheel rigidity in the left arm with slow fine movements in the left fingers. In the left leg there is a slight rest tremor and moderate rigidity. He walks in a posture of mild flexion, with reduced arm swinging on

the left and shuffling of the left leg. His walking is a little slow.

He is profoundly disappointed to hear that he has Parkinson's disease. He has never had any previous illness, and somebody in his village has very severe Parkinson's disease indeed.

Several consultations are required to explain the nature of Parkinson's disease, the fact that some people have it mildly and some severely, that effective treatment exists in the form of tablets, and that a very pessimistic viewpoint isn't appropriate or helpful to him.

Gradually he's coming round to the idea and becoming more optimistic. Levodopa therapy is producing significant improvement. Literature produced by the Parkinson's Disease Society has helped his understanding of the illness.



A girl of 24 years presents with a 3-week history of heaviness and dragging of the left leg. She has had to stop driving because of left leg weakness and clumsiness. For a week she hasn't been able to tell the

temperature of the bath water with the right leg, though she can with the weak leg. She has developed a little bladder frequency and urgency. She has had to stop her job as a riding school instructor.

Three years ago she lost the vision in her left eye for a few weeks, but it recovered well. Doctors whom she saw at the time talked about inflammation of the optic nerve.

She is engaged to be married in a few month's time.

General examination is normal.

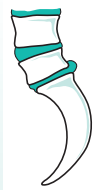Neurological examination reveals no abnormalities in the cranial nerves or arms. She has moderate UMN

signs in the left leg, loss of sense of position in the left foot and toes, and spinothalamic sensory loss (pain and temperature) throughout the right leg. She drags her left leg as she walks.

She understands that she now, almost certainly, has another episode of inflammation, this time on the left hand side of her spinal cord, similar in nature to the optic nerve affair 3 years ago.

She accepts the offer of treatment with high-dose IV steroids for 3 days, to help to resolve the inflammation. She is keen to return to work.

The neurologist knows that he has got quite a lot more work to do for this girl. He has to arrange for the investigations to confirm his clinical opinion that she has multiple sclerosis. He will then have to see her (and her fiancé, if she would like it) and explain that multiple sclerosis is the underlying explanation for the symptoms. He will have to do his best to help her to have an appropriate reaction to this information. Both she and her fiancé will need information and support.



A man of 46 years, scaffold-erector, knows that his left foot is weak. It has been present for a few months. He has lost spring at the ankle, and the left foot is weak when taking all his weight on ladders and scaffold. He's had back pain, on and off, for many years like a lot of his work mates. He doesn't get paid if he's not working.

General examination is normal except for some restriction of forward flexion of the lumbar spine.

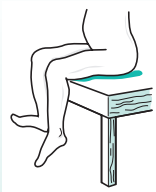Neurological examination reveals wasting and weakness of the left posterior calf muscles (i.e. foot and toe plantar-flexors), an absent left ankle jerk, and impaired cutaneous sensation on the sole and lateral aspect of the left foot.

Scanning confirms the presence of a large prolapsed intervertebral disc compressing the left S1 nerve root.

He is offered referral to a neurosurgeon.

His concerns are:

- Will the operation work (i.e. restore better function to the left leg)?
Yes — more likely than not, but only over several months, even up to a year.
- How much time off work?
Probable minimum of 6–8 weeks and then light duties for a further 6–8 weeks.
- Should he be thinking of changing his job?
Not essential, but an excellent idea if a good opportunity turned up.



A 38-year-old unkempt alcoholic presents with a left foot drop so that he cannot lift up the foot against gravity, and as he walks there is a double strike as his left foot hits the ground, first with the toe and then with the heel. He's very frequently intoxicated, and he can't remember how, or precisely when, the foot became like this.

General examination reveals alcohol in his breath, multiple bruises and minor injuries all over his body, no liver enlargement, but generally poor nutritional state.

Neurological examination reveals weakness of the left foot dorsiflexion, left foot eversion, left toe dorsiflexion and some altered cutaneous sensation down the lower anterolateral calf and dorsal aspect of the foot on the left.

A left common peroneal nerve palsy, secondary either to compression (when intoxicated) or to trauma, at the neck of the left fibula, is explained as the most probable diagnosis. Arrangements are made for a surgical appliance officer to provide a foot-support, the physiotherapists to assess him, and for neurophysiological confirmation of the diagnosis.

The patient defaults on all these and further appointments.

