

# Preface

*Visual Fields via the Visual Pathway* presents the varying visual field deficits occurring with lesions of the visual pathway. The main content is structured such that the visual pathway is traced anatomically from front to back, and each section of the visual pathway has its own dedicated chapter.

The chapters are clearly structured and comprise an outline of anatomy, pathology and signs and symptoms, plus visual field defects specifically associated with that part of the visual pathway. Each chapter is supplemented by numerous illustrations of visual field results, neuroimaging scans and/or line drawings; colour plates of associated fundus images are also provided.

In addition, chapters are provided on the basic theory of visual field assessment, methodology, aids to differential diagnosis, artefacts of visual field results and a glossary of terms used in visual field assessment. References and further reading lists are provided for each chapter, containing key articles and up-to-date literature.

This textbook has been written to provide a guide for the multi-disciplinary eye care team: ophthalmologists, orthoptists, optometrists, ophthalmic technicians and ophthalmic nurse practitioners. Its clinical content for both text and illustrations is particularly relevant for the practitioner.

Unless otherwise stated the right visual field is displayed above the left visual field result, or to the right side of the left visual field result. **Note:** the blind spot appears on the right side of central fixation within the right visual field, and on the left side of central fixation within the left visual field.

## Disclosure

Dr Rowe has no financial or commercial interest in either Goldmann perimeters or Humphrey visual field analysers.

## Chapter 1

# Field of vision and visual pathway

Visual field assessment is the process by which the boundaries of the visual field are plotted and the field within the peripheral boundaries is determined to be intact. Assessment of the visual field has been undertaken in varying ways since the blind spot was first documented by Mariotte in the seventeenth century. The outer boundaries of the visual field were assessed by Young and Purkinje in the nineteenth century. However, the first clinical measurement of the visual field was not made until the 1850s and this was achieved by von Graefe.

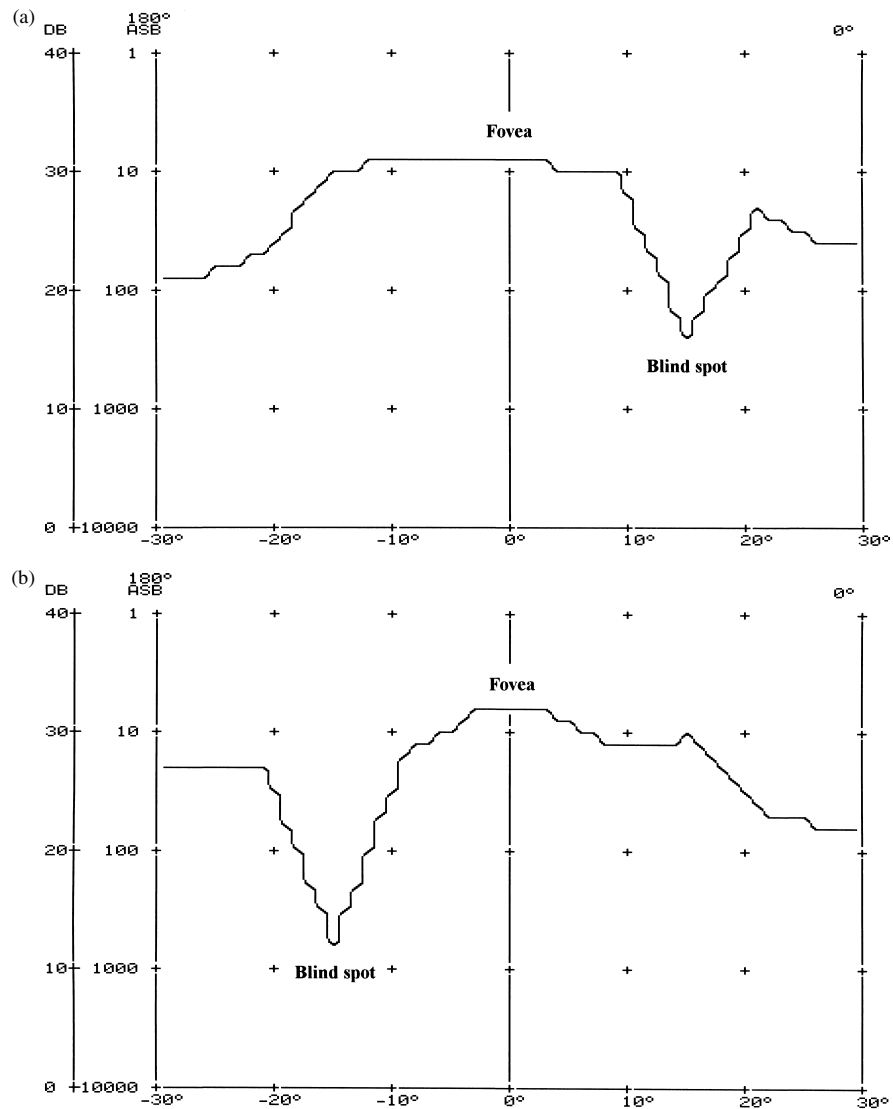
Varying methodologies have been developed for the assessment of the field of vision since the nineteenth century. In 1889, Bjerrum introduced a tangent screen for assessment of the visual field which currently retains his name. This predominantly assessed the central visual field. The Arc perimeter was introduced by Aimark in the 1930s which had the advantage of being able to plot the peripheral visual field. This was followed by the introduction of the Goldmann perimeter in 1945 which today remains in widespread use and continues to be of considerable clinical value.

The Friedmann perimeter was the first quantitative static measurement introduced in 1966 and assessed the central visual field. Automated perimetry was introduced in the 1970s with the subsequent development of a myriad of different automated perimeters with many testing programmes which today provide accurate and reliable visual fields with the advantage of statistical analysis of results and computer storage of patient files. The automated perimeter most commonly in current use in hospital practice is the Humphrey field analyser (Humphrey Systems, Dublin, CA).

### General anatomy of the visual system

---

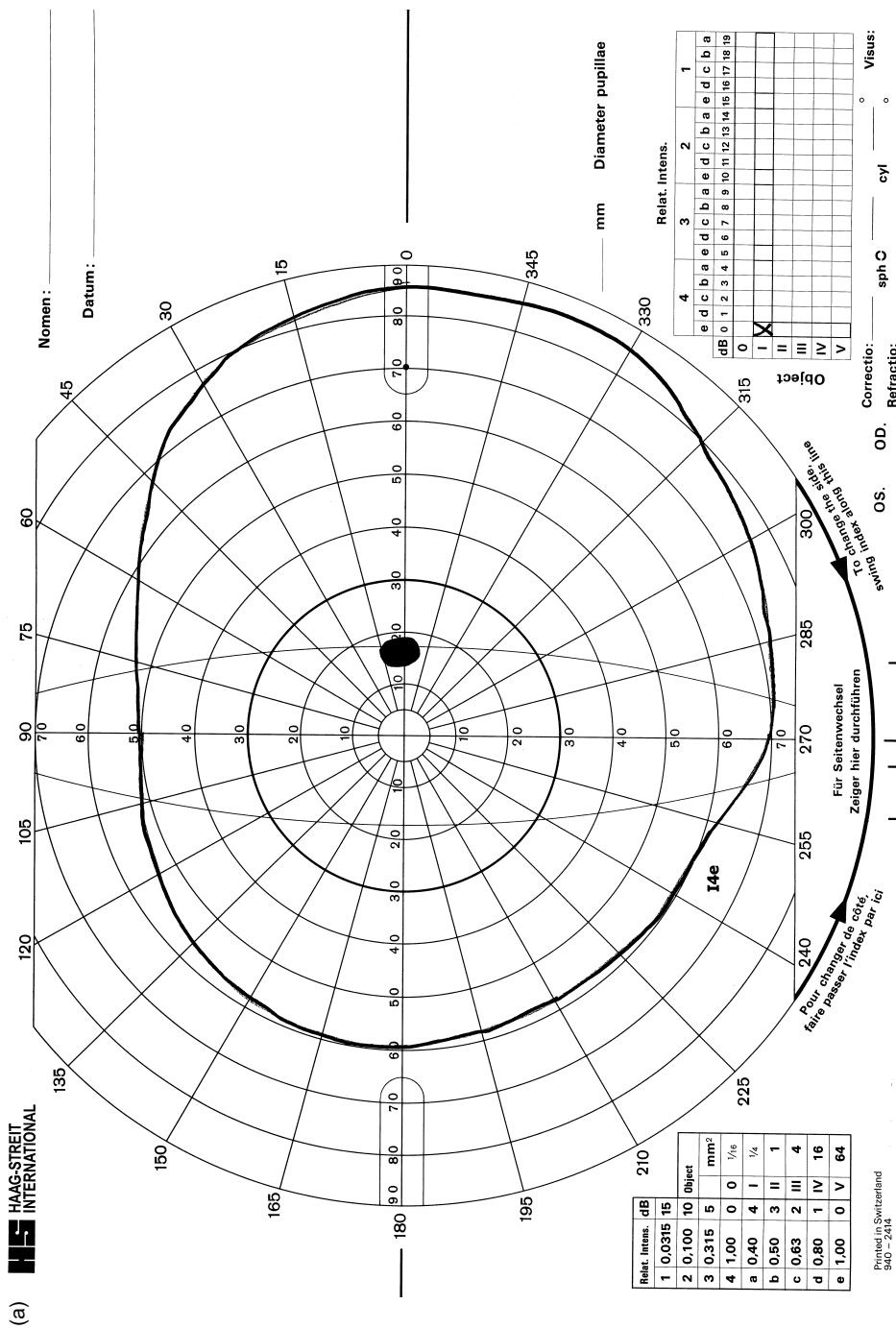
The hill of vision is a map of the visual sensitivity across the visual field, usually in three dimensions. A one dimension representation usually takes a horizontal section bisecting the optic disc and fovea (Fig. 1.1). The central peak of the hill equates to the fovea and is typically the area of highest sensitivity. Sensitivity decreases towards the periphery of the visual field. The normal monocular visual field extends 50–60 degrees superiorly, 60 degrees nasally, 70–75 degrees inferiorly and 90–100 degrees temporally (Kanski & McAllister 1989; Stamper *et al.* 1999). The extent



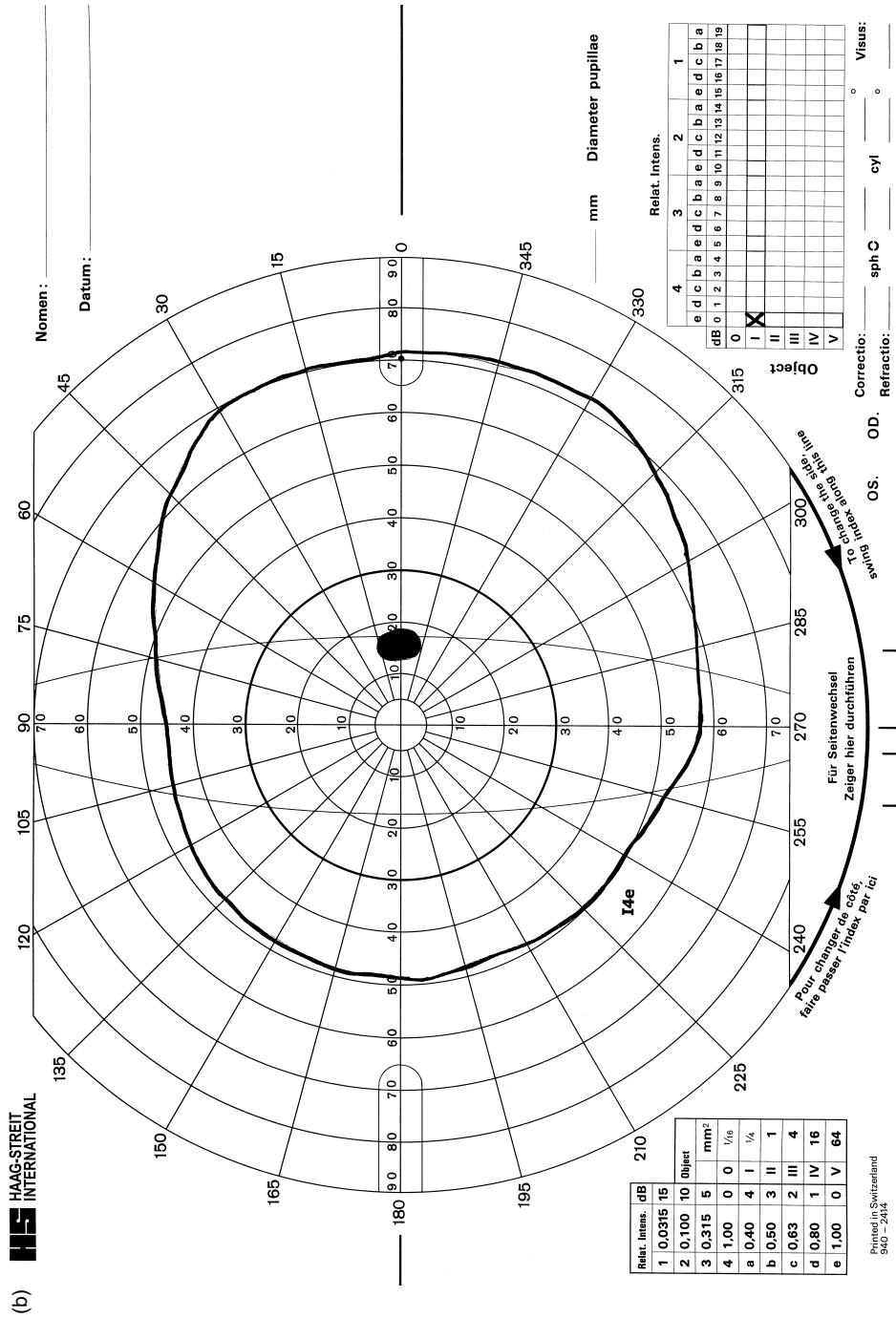
**Figure 1.1** Hill of vision. Map of visual field is usually in three dimensions but is represented here in one dimension. The central peak has the highest sensitivity and represents the fovea. Sensitivity decreases towards the periphery of the visual field.

of visual field will vary with stimulus size, and the extent measured with a Goldmann I4e or  $\frac{3}{4}$  mm white target is regarded as normal (Fig. 1.2). As the optic disc has no retinal photoreceptors, it forms the blind spot of the visual field.

The visual field is produced by retinal stimulation of each eye and relates to what is seen by the individual whilst maintaining steady fixation, i.e. it is the perceived vision of an individual. Retinal images are projected to a position opposite the area of retina stimulated; for example, objects that stimulate nasal retina are situated in



**Figure 1.2** Normal extent of field of vision. Goldmann chart plotted with a I4e target showing the peripheral boundary of the visual field and the blind spot. The extent of peripheral boundary is age dependent: (a) 20 year old; (b) 60 year old.



the temporal visual field and objects that stimulate inferior retina are situated in the superior visual field.

A high percentage of nerve fibres arise from the macular area of the retina and pass directly to the optic disc (papillomacular bundle). Nerve fibres located further temporally in the peripheral retina (nasal field of vision) must arc above and below the macular fibres to enter the optic disc superiorly and inferiorly. Nerve fibres on the nasal side of the optic disc (temporal field of vision) pass directly to the nasal border.

Once in the optic nerve, the macular fibres move to a central position with superior retinal fibres above and inferior retinal fibres below. Temporal and nasal nerve fibres retain their temporal and nasal location within the optic nerve.

On reaching the optic chiasm, the temporal nerve fibres maintain their temporal position whilst nasal nerve fibres (both central and peripheral) decussate. Ipsilateral temporal nerve fibres and contralateral nasal nerve fibres regroup in the optic tracts, but again with superior fibres retaining a more superior location to the inferior fibres.

Nerve fibres are distributed in a complicated multi-layered arrangement in the lateral geniculate nucleus of the lateral geniculate body, with macular fibres distributed throughout the nucleus. Ipsilateral and contralateral peripheral nerve fibres are located in different layers of the nucleus. There is a synapse of nerve fibres in the lateral geniculate body.

Fibres leaving the lateral geniculate body fan out to form the optic radiations, many of which pass directly posterior to the visual cortex. A proportion, however, initially pass anteriorly and laterally before turning posterior towards the visual cortex.

Within the striate visual cortex (V1) the macular fibres terminate on the tip of the occipital lobe (occipital pole), whilst the more peripheral fibres terminate more anteriorly. The most peripheral fibres relating to the monocular crescent of each eye are the most anteriorly represented. Superior fibres are on the upper lip of the calcarine fissure, whilst inferior fibres are on the lower lip. Figure 1.3 represents the afferent visual pathway.

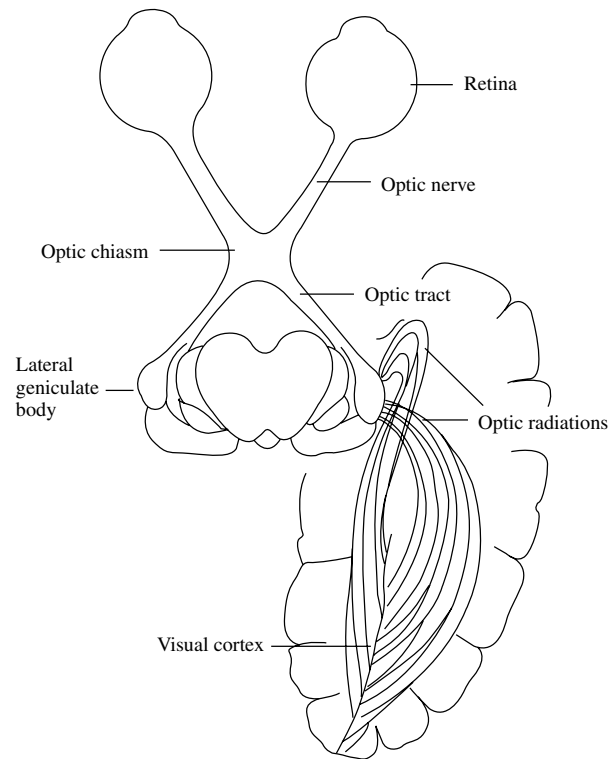
## Visual field defect types

---

### Altitudinal visual field defect (Fig. 1.4)

This involves two quadrants of either the superior or inferior visual field and is typically seen in ischaemic optic neuropathies. The defect precisely respects the horizontal meridian. The sharp horizontal separation occurs because there is a clear demarcation between superior and inferior nerve fibres temporal to the macula and nasal to the optic disc.

Severe hypotension, sudden haemorrhage and rapid development of anaemia may be responsible for simultaneous bilateral ischaemic optic neuropathies with altitudinal visual field defects. They may also be due to bilateral symmetric involvement at a cortical level, including bilateral lesions affecting the occipital lobe (Heller-Bettinger *et al.* 1976; Miller & Newman 1999).



**Figure 1.3** Afferent visual pathway. Visual pathway from retina to visual cortex.

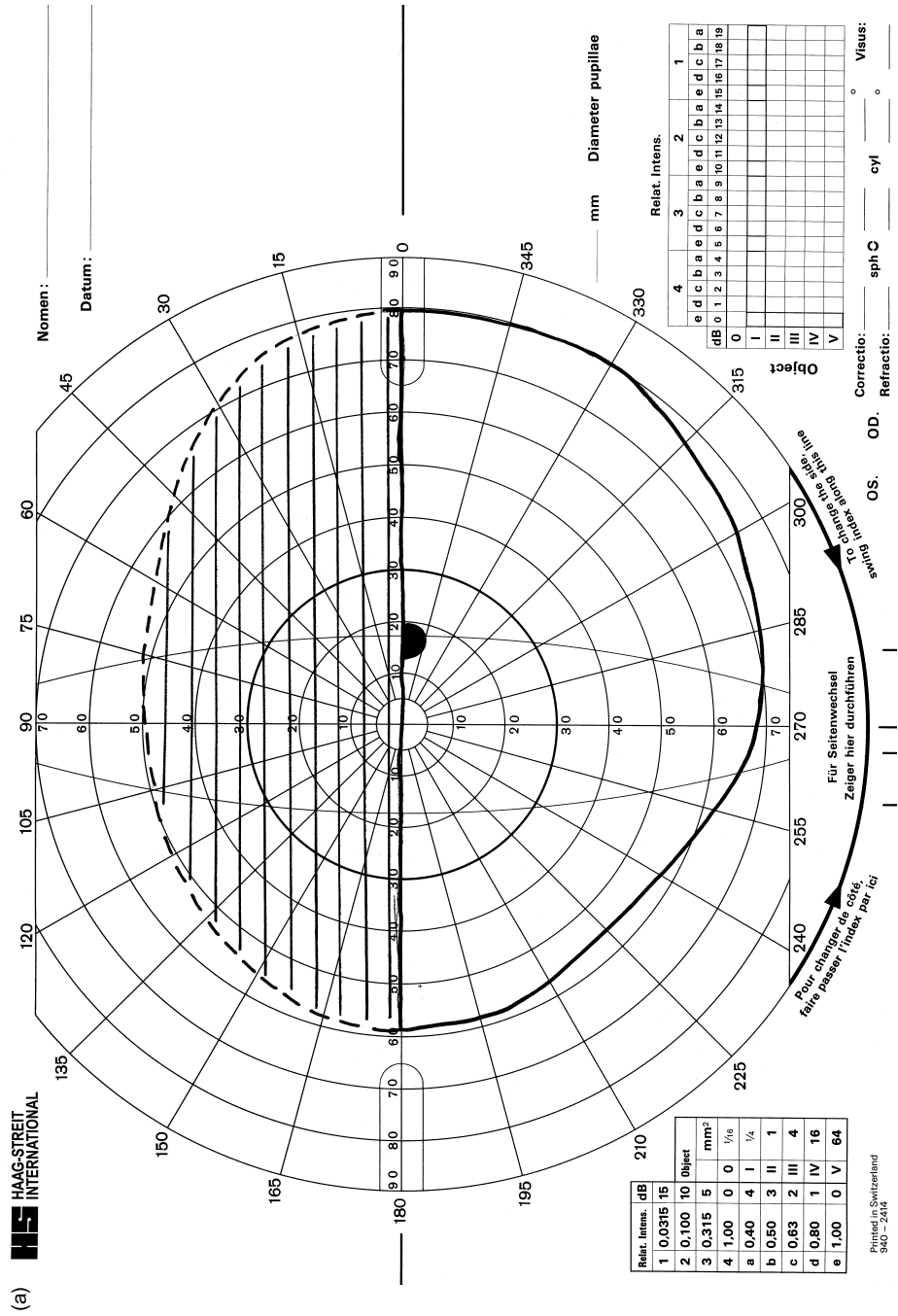
### **Arcuate visual field defect (Fig. 1.5)**

This is caused by selective damage to the superior or inferior retinal nerve fibre bundles as they enter the optic nerve head and is typical of glaucoma. However, such visual field defects are also seen in optic neuritis, ischaemic optic neuropathy and congenital optic disc drusen.

Temporally, the defect is narrow because all of the nerve fibre bundles converge on the optic disc. The defect spreads out on the nasal side, but typically arcs over central fixation. All complete arcuate scotomas extend to the horizontal meridian producing a nasal step, assuming there is differing involvement of the superior and inferior visual fields.

### **Hemianopia (Fig. 1.6)**

A hemianopia is a complete defect involving one half of the visual field. A heteronymous hemianopia involves opposite sides of the visual field (e.g. lesions of the optic chiasm typically produce bitemporal heteronymous hemianopias). A homonymous hemianopia involves the same side of the visual field in each eye (e.g. lesions of the retrochiasmatal pathways typically produce homonymous hemianopias).



**Figure 1.4** Altitudinal visual field defect: (a) superior altitudinal defect involving inferior retinal nerve fibres; (b) inferior altitudinal defect involving superior retinal nerve fibres.





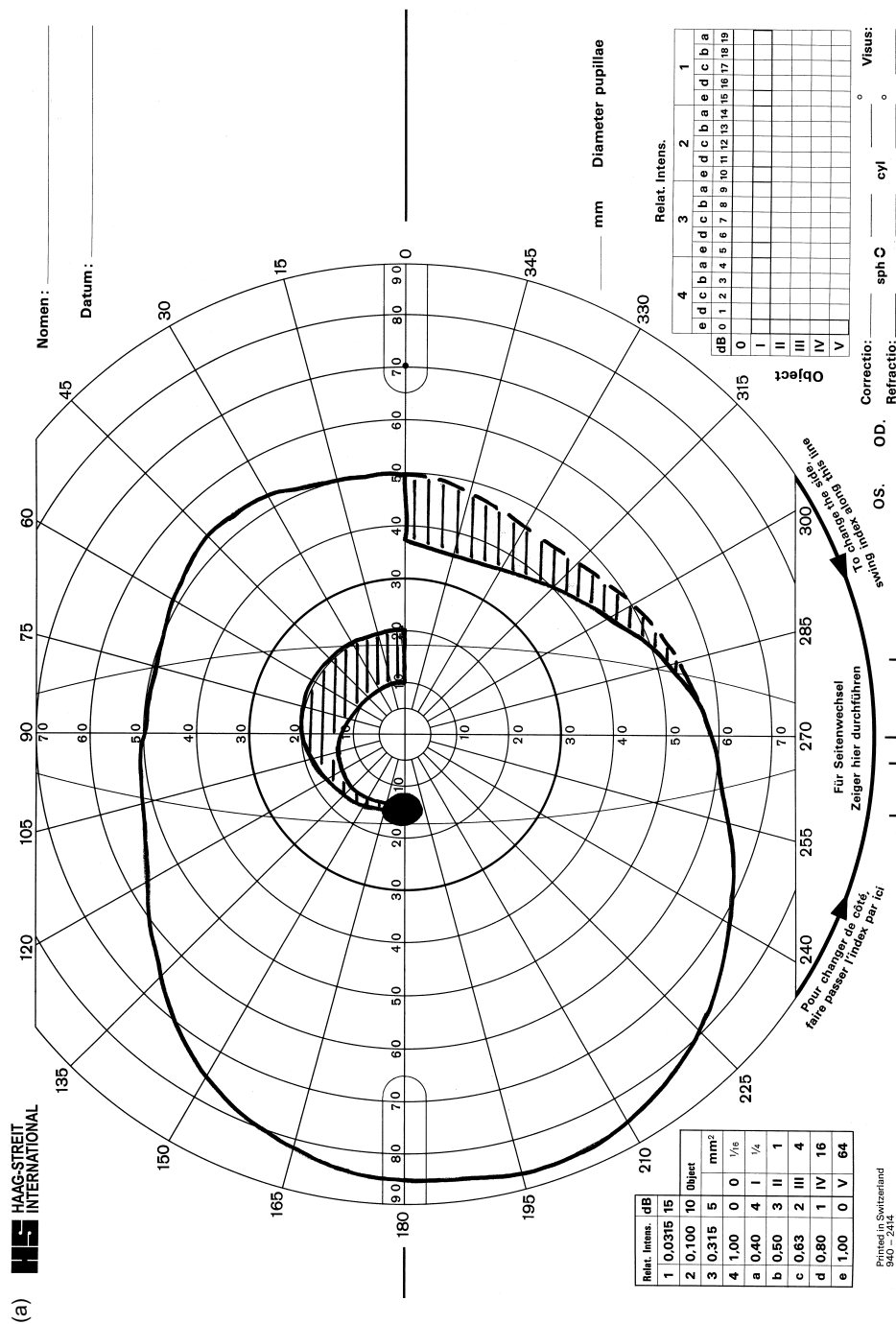


Figure 1.5 Arcuate visual field defect: (a) superior arcuate defect with inferior nasal step; (b) inferior arcuate defect.

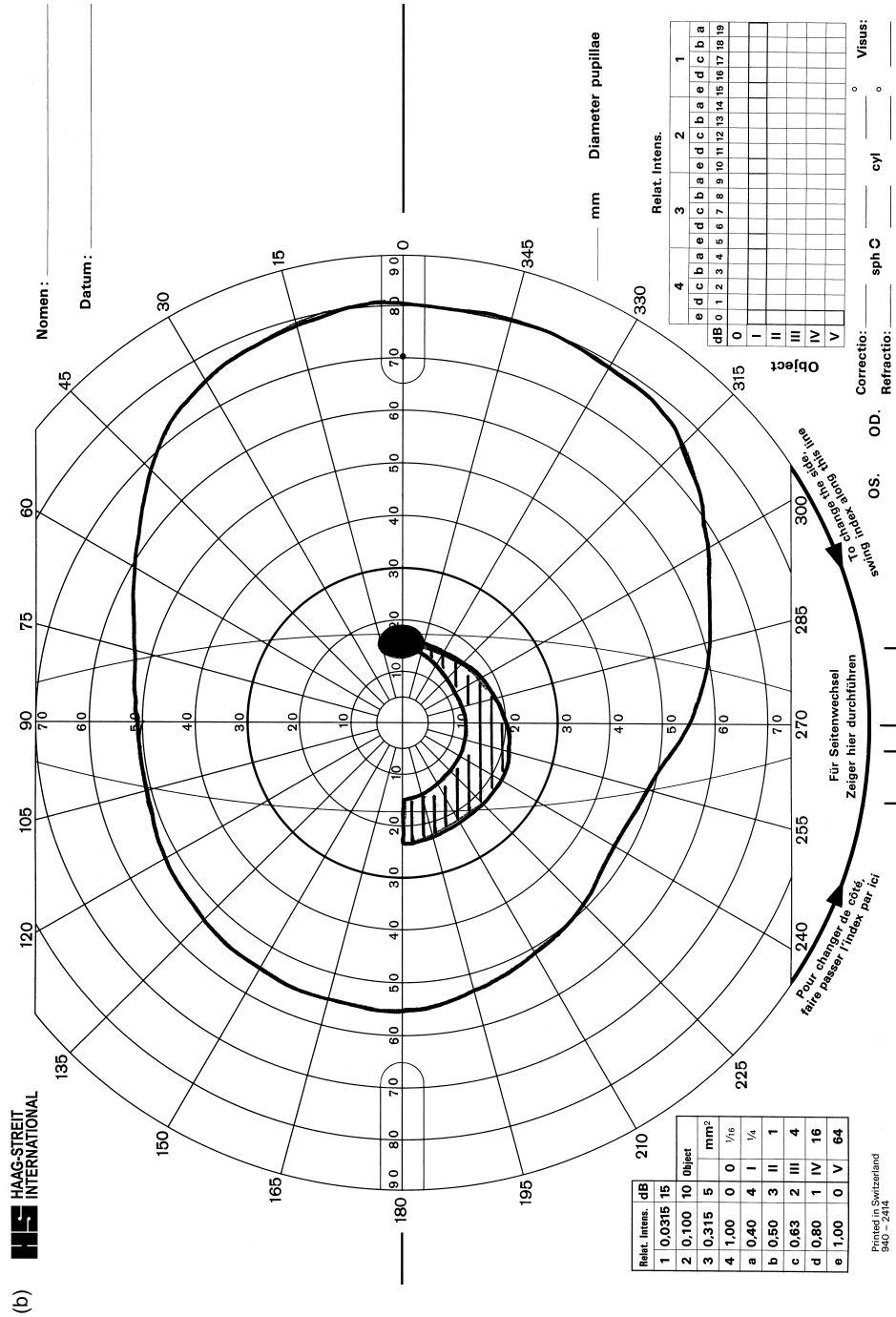


Figure 1.5 (Continued)

### **Quadrantanopia (Fig. 1.7)**

This is a complete defect involving a quadrant of each visual field. Heteronymous quadrantanopia involves opposite sides of the visual field and either superior or inferior quadrants. Homonymous quadrantanopias involve the same side of the visual field in each eye and either superior or inferior quadrants. These may be produced by temporal, parietal or occipital lobe lesions.

### **Scotoma**

A scotoma is an absolute or relative area of depressed visual sensitivity surrounded by normal vision. In an absolute scotoma all vision is lost, whereas in a relative scotoma a variable amount of vision remains. Scotomas may be central, paracentral or caecocentral in type.

A central scotoma only involves fixation (Fig. 1.8a). The scotoma can be relative or absolute depending on the severity of the lesion. A central scotoma typically occurs in optic neuritis, although it can also be caused by ischaemic and compressive optic nerve lesions.

A paracentral scotoma (Fig. 1.8b) involves an area of visual field away from fixation and tends to be elongated circumferentially along the course of the optic nerve fibres within the central 30 degrees. It may be seen in glaucoma or lesions affecting the optic disc such as papilloedema.

A caecocentral scotoma (Fig. 1.8c) extends from fixation to the blind spot and is caused by disease of the papillomacular bundle. It typically occurs in toxic optic neuropathies and Leber's optic neuropathy. Congenital optic disc pits associated with serous detachment of the macula may also produce a similar defect. Bilateral caecocentral scotomas may be due to toxic amblyopia, optic neuritis, Leber's optic neuropathy or intrinsic optic nerve tumours.

### **Sector-shaped (wedge) visual field defect (Fig. 1.9)**

These visual field defects start as small scotomas on the temporal side of the visual field and end as complete sectorial loss.

### **Parameters and variables in visual field assessment**

---

There are a number of parameters that must be considered when undertaking quantitative visual field assessment:

- (1) The size of stimulus
- (2) Luminance intensity
- (3) Anatomical features
- (4) Interference with perception of stimuli
- (5) Patient ability
- (6) Examination technique.

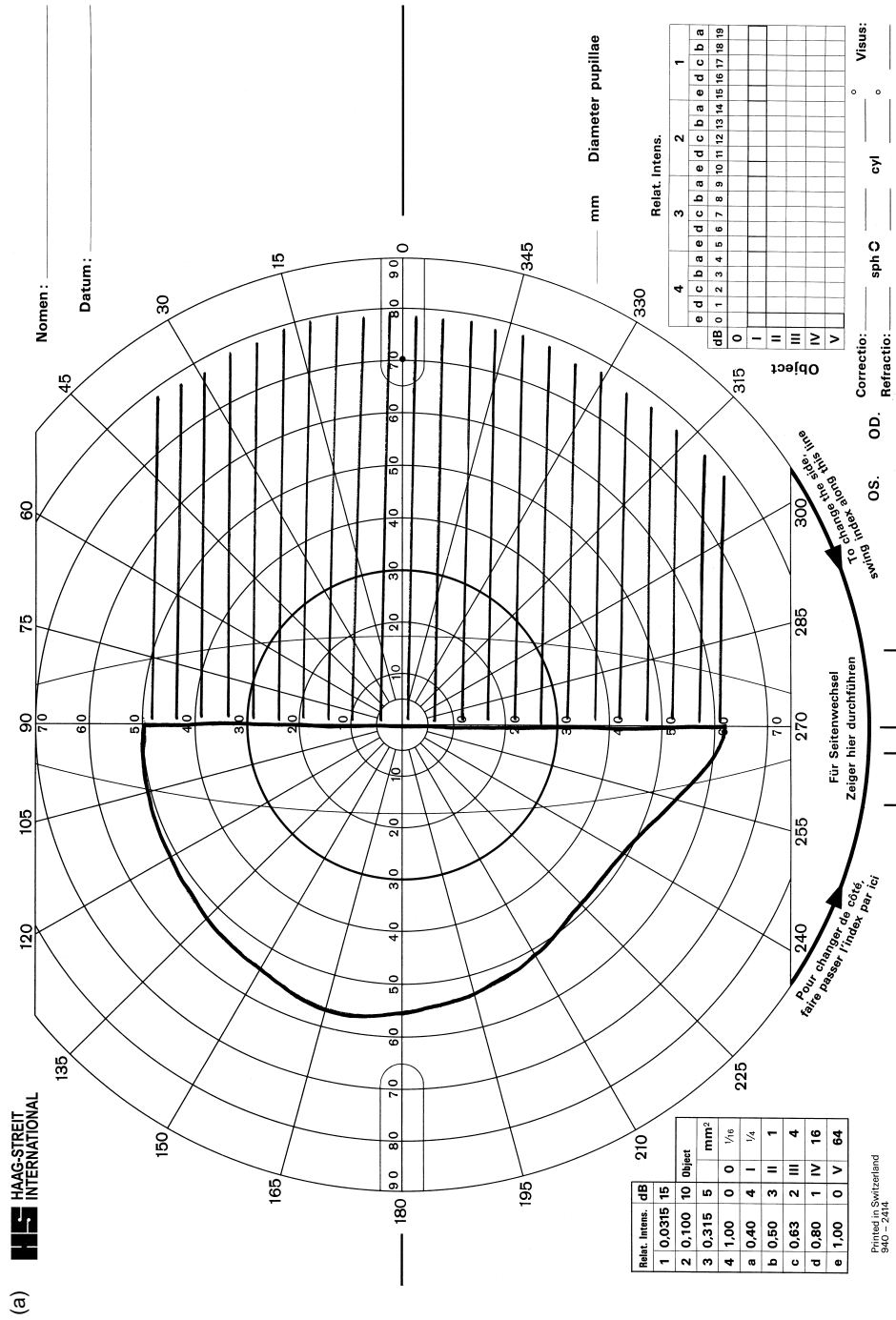


Figure 1.6 Hemianopia: (a) bitemporal hemianopia; (b) homonymous hemianopia.













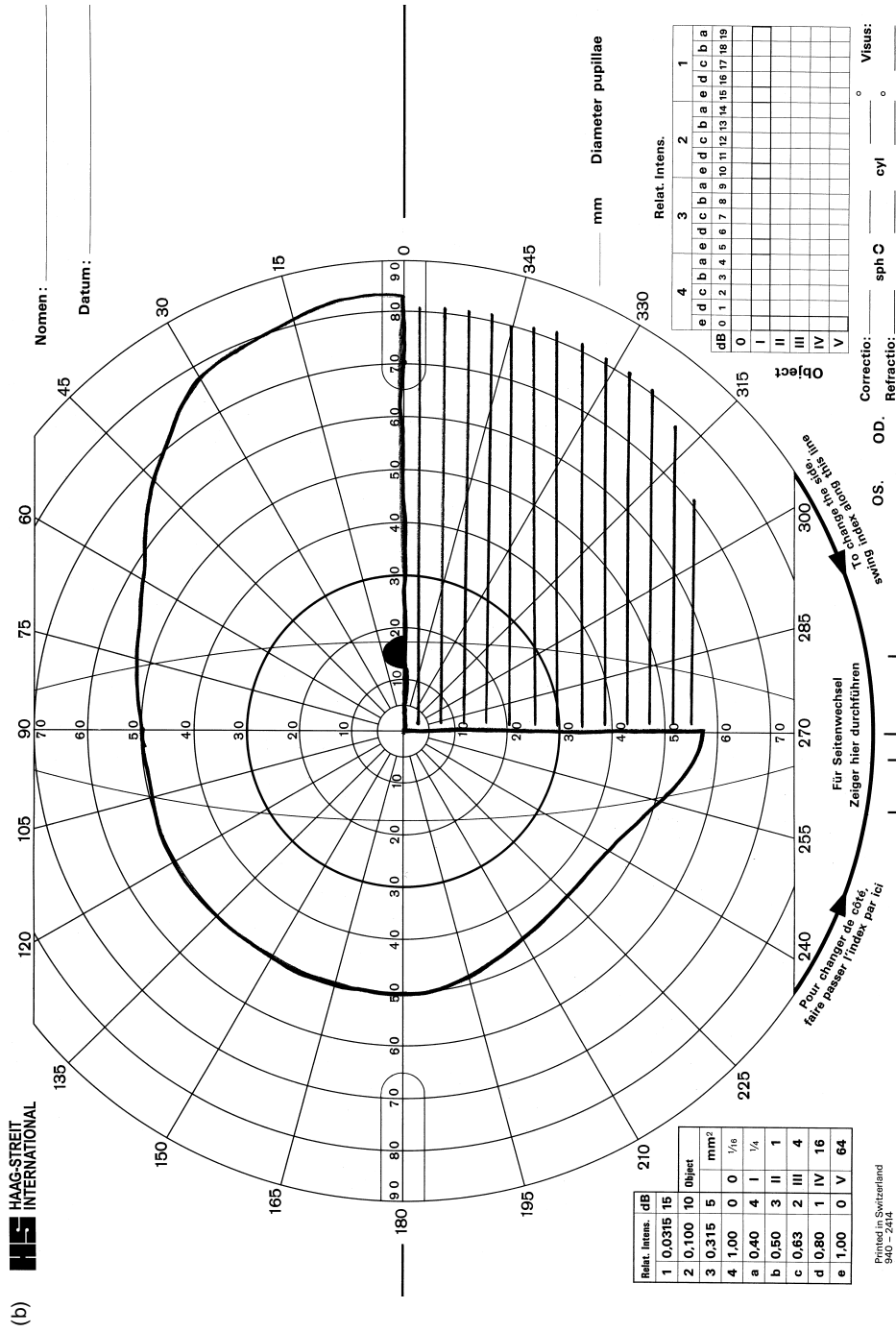


Figure 1.7 (Continued)

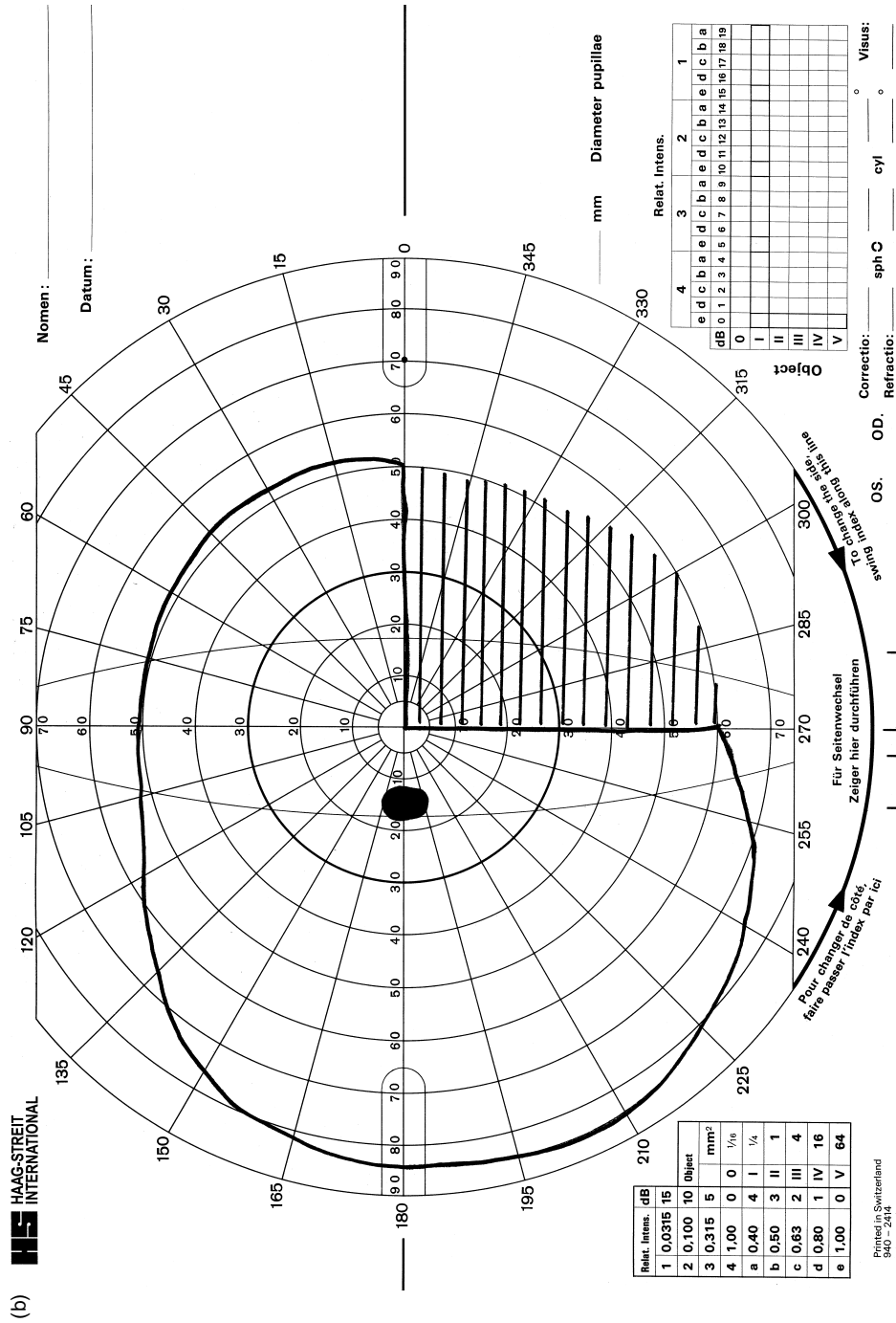
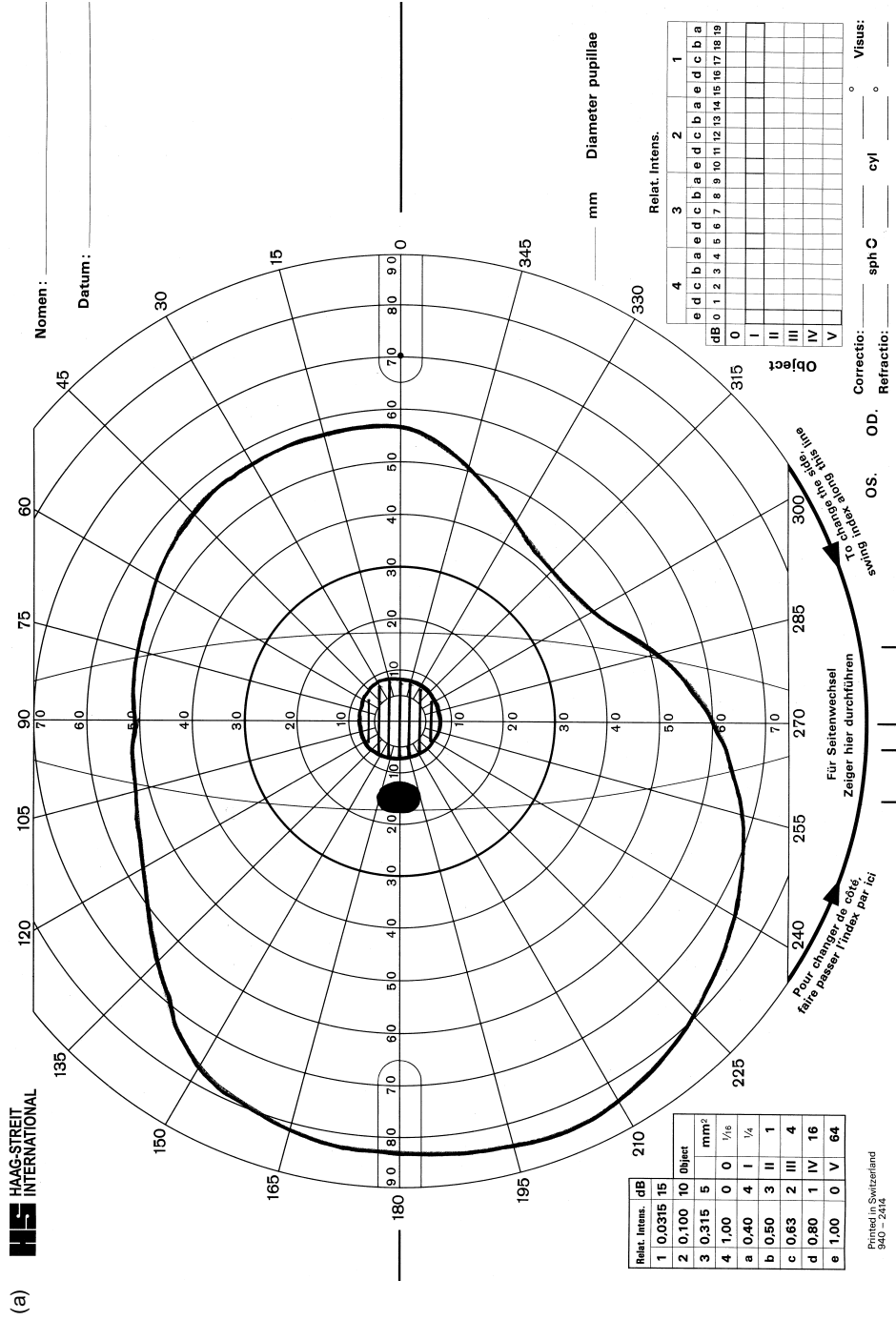


Figure 1.7 (Continued)



**Figure 1.8** Scotomas: (a) central – involvement of central fixation only; (b) paracentral – defect is located within 30 degrees of central fixation; (c) caeccentral – central fixation is involved with extension of the defect to the blind spot.



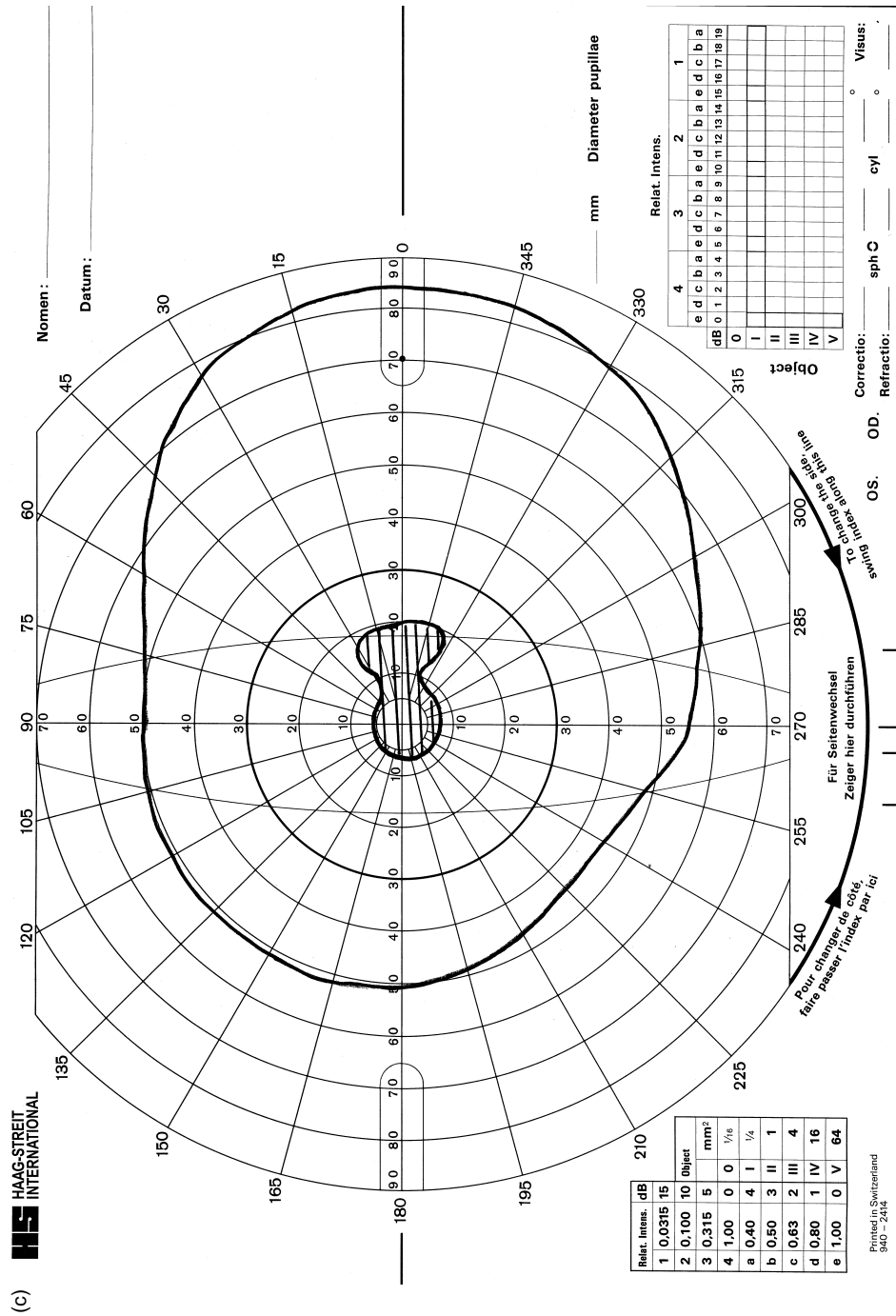


Figure 1.8 (Continued)

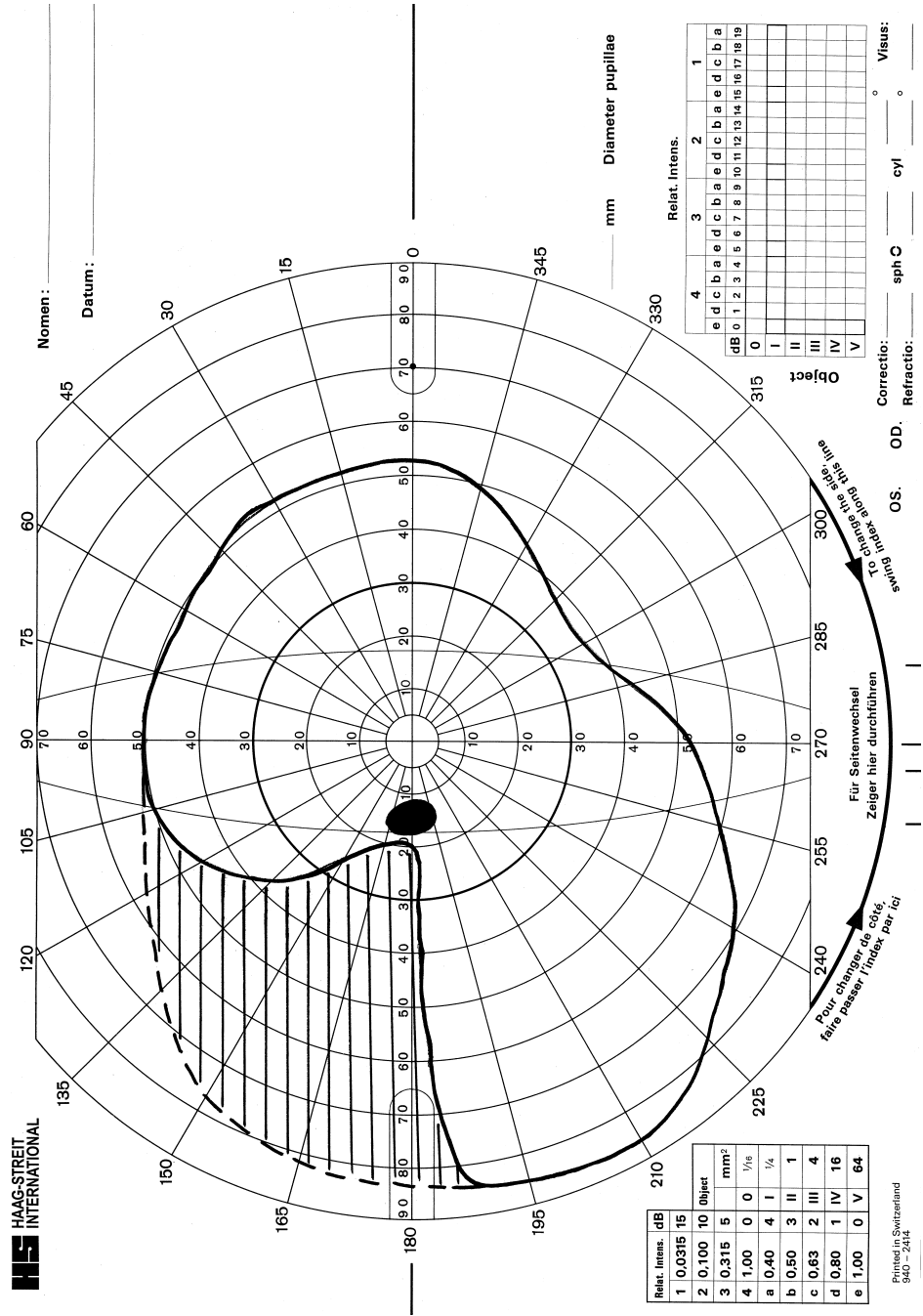


Figure 1.9 Sector-shaped (wedge) visual field defect. Temporal defect extends to the blind spot.



**Table 1.1** Size and intensity of targets in Goldmann perimetry.

Stimulus <sup>a</sup>	Intensity		Size of target (mm <sup>2</sup> )
	Apostilb	Decibel	
V4e	1000	0	64
IV4e	315	5	16
III4e	100	10	4
II4e	31.5	15	1
I4e	10	20	1/4
I3e	3.15	25	1/4
I2e	1	30	1/4
I1e	0.315	35	1/4

<sup>a</sup>These eight standard stimuli are used to allow continuity of testing and interpretation.

The size of stimulus can be varied in that stimuli can be presented in sizes I to V in both Humphrey automated and Goldmann manual perimetry ( $\frac{1}{4}$  mm<sup>2</sup> to 64 mm<sup>2</sup>; Table 1.1). Size III stimulus is standardly set for automated perimetry (4 mm<sup>2</sup>). The size of stimuli remains constant in Humphrey automated perimetry, thereby providing consistent stimuli. Stimulus size is varied during testing in manual Goldmann perimetry when plotting peripheral and central isopters.

The sensitivity of the visual field is expressed in luminance or light intensity units. Luminance units are candelas per square metre (cd/m<sup>2</sup>). Light intensity is expressed as an apostilb which is an absolute unit of light measurement equal to 0.1 millilamberts (1 cd/m<sup>2</sup> equals 3.14 asb). The range of retinal light sensitivity measured by visual field assessment is expressed in log units with a base of 10. In perimetry, stimulus intensity for visual field assessment is represented in decibel values which equal  $\frac{1}{10}$ th of a log unit (10 decibels equals 1 log unit) and allows larger numbers to be expressed as smaller numerical units. Therefore changes in sensitivity are more easily detected (0 decibels = 1000 apostilb = 300 cd/m<sup>2</sup>).

The luminous intensity of the stimulus in automated visual field assessment may be altered from 0 to 51 decibels, providing a wide range of brightness levels for stimuli to completely assess the threshold of all visual field areas. The relative luminance between background and stimulus will alter sensitivity. In Goldmann and Humphrey perimetry the background illumination is set at 31.5 apostilb. This standard calibration is necessary for test/retest repeatability. The area of retina stimulated will provide different responses to stimuli, i.e. peripheral retinal responses have lower luminance sensitivity than central retinal responses.

There are a number of external variables that must be considered with regard to the visual field result. These include anatomical features of the face (e.g. prominent brow or nose), interference with ocular media and perception of stimuli (e.g. ptosis, miotic pupil, uncorrected refractive error, cataract), attention and age of the patient, and technique of the examiner (explanation of the test and patient set-up) (Haas *et al.* 1986; Johnson *et al.* 1989).

Protruding facial features such as lids and brows may provide spurious visual field defects, often in the superior visual field. Where there is ptosis, the lid should be taped to prevent it blocking stimuli presentation.

Miosis depresses the visual field and can exaggerate the size and depth of existing visual field defects. Pupil diameter less than 2 mm produces visual field loss as pupil constriction dims both the intensity of the stimulus and the intensity of the background. This is a problem when assessing patients on miotics for glaucoma (Mikelberg *et al.* 1987; Lindenmuth *et al.* 1989).

Refractive errors, if uncorrected, can result in refractive scotomas with enlarged blind spots and enlargement of other visual field defects. There is also a depression of sensitivity in the visual field. Defocus effectively enlarges the stimulus size but will reduce the luminance (Atchison 1987; Henson & Morris 1993). Refractive errors greater than 1 dioptre should be corrected and the prescription given according to the patient's age and instrument optics. Incorrect spectacle corrections can also cause artefacts due to reduced light sensitivity which may produce local or generalised visual field loss.

Abnormalities that interfere with media clarity reduce illumination; therefore sensitivity within the visual field will be generally depressed and existing visual field defects exaggerated (Guthauser *et al.* 1987).

Age gradually depresses the visual field sensitivity. Light-difference sensitivity decreases with age partly due to age-related loss of nerve fibres (Balazsi *et al.* 1984) and increased condensation of the media.

## References

- Atchison DA (1987) Effect of defocus on visual field measurement. *Ophthalmic and Physiological Optics*, 7: 259
- Balazsi AG, Rootman J, Drance SM, Schulzer M, Douglas GR (1984) The effect of age on the nerve fibre population of the human optic nerve. *American Journal of Ophthalmology*, 97: 760
- Guthauser U, Flammer J, Niesel P (1987) Relationship between cataract density and visual field damage. *Documenta Ophthalmologica Proceedings Series*, 49: 39
- Haas A, Flammer J, Schneider U (1986) Influence of age on the visual fields of normal subjects. *American Journal of Ophthalmology*, 101: 199
- Heller-Bettinger I, Kepes JJ, Preskorn SH, Wurster JB (1976) Bilateral altitudinal anopia caused by infarction of the calcarine cortex. *Neurology*, 26: 1176
- Henson DB, Morris EJ (1993) Effect of uncorrected refractive errors upon central visual field testing. *Ophthalmic and Physiological Optics*, 13: 339
- Johnson CA, Adamo AJ, Lewis RA (1989) Evidence for a neural basis of age-related visual field loss in normal observers. *Investigative Ophthalmology*, 30: 2056
- Kanski J, McAllister J (1989). *Glaucoma: A Colour Manual of Diagnosis and Treatment*. London, Butterworths
- Lindenmuth KA, Skuta GL, Rabbani R, Musch DC (1989) Effect of pupillary constriction on automated perimetry in normal eyes. *Ophthalmology*, 96: 1289
- Mikelberg FS, Drance SM, Schutzer M, Wijsman K (1987) The effect of miosis on visual field indices. *Documenta Ophthalmologica Proceedings Series*, 49: 645
- Miller NR, Newman NJ (1999) *Walsh and Hoyt's Clinical NeuroOphthalmology. The Essentials*. 5<sup>th</sup> edn. Baltimore, MD, Williams and Wilkins
- Stamper R, Lieberman M, Drake M (1999). *Diagnosis and Therapy of the Glaucomas*. St Louis, Mosby

## Further reading

- Allergen Humphrey (1991) *Field Analyzer Owner's Manual*. San Leandro, CA, Humphrey Instruments (Carl Zeiss Group)
- American Academy of Ophthalmology (1996) Automated perimetry. *Ophthalmology*, **103**: 1144
- Anderson DR (1992) *Automated Static Perimetry*. St Louis, CV Mosby
- Armaly MF (1969) Ocular pressure and visual fields. *Archives of Ophthalmology*, **81**: 25
- Autzen T, Work K (1990) The effect of learning and age on short-term fluctuation and mean sensitivity of automated static perimetry. *Acta Ophthalmologica*, **68**: 327
- Enoch JM (ed.) (1979) *Perimetric Standards and Perimetric Glossary of the International Council of Ophthalmology*. The Hague, W. Junck
- Fankhauser F, Enoch JM (1962) The effect of blur on perimetric thresholds. *Archives of Ophthalmology*, **86**: 240
- Gonzalez de la Rosa M, Pareja A (1997) Influence of the fatigue effect on the mean deviation measurement in perimetry. *European Journal of Ophthalmology*, **7**: 29
- Haley MJ (1987) *The Field Analyzer Primer*, 2nd edn. San Leandro, CA, Humphrey Instruments
- Herse PR (1992) Factors influencing normal perimetric thresholds. *Investigative Ophthalmology and Visual Science*, **33**: 611
- Heuer DK, Anderson DR, Feuer WJ, Gressel MG (1987) The influence of refraction accuracy on automated perimetric threshold measurements. *Ophthalmology*, **94**: 1550
- Hoyt WF, Tudor RC (1963) The course of papillary temporal retinal axons through the anterior optic nerve. A Nanta degeneration study in the primate. *Archives of Ophthalmology*, **69**: 503
- Jaffe GJ, Alvarado JA, Juster RP (1986) Age-related changes of the normal visual field. *Archives of Ophthalmology*, **104**: 1021
- Johnson C, Nelson-Quigg JM (1993) A prospective three year study of response properties of normal subjects and patients during automated perimetry. *Ophthalmology*, **100**: 269
- Katz J, Sommer A, Witt K (1991) Reliability of visual field results over repeated testing. *Ophthalmology*, **98**: 70
- Kline LB, Bajandas FJ (1995) *Neuro-Ophthalmology Review Manual*, 4th edn. Thorofare, NJ, Slack
- Reitner A, Tittl M, Ergun E, Baradaran-Dilmaghani R (1996) The efficient use of perimetry for neuro-ophthalmic diagnosis. *British Journal of Ophthalmology*, **80**: 903
- Rowe FJ (1998) Visual field analysis with Humphrey automated perimetry. Part I and II. *Eye News*, **4**(6) 6–10; **5**(1) 15–19
- Rowe FJ (1999) *Idiopathic intracranial hypertension. Assessment of visual function and prognosis for visual outcome*. PhD thesis, APU Cambridge
- Sarkies N (1987) Neurological visual fields. *British Orthoptic Journal*, **44**: 15
- Taylor JF (ed.) (1995) *Medical Aspects of Fitness to Drive. A Guide for Medical Practitioners*. London, Medical Commission on Accident Prevention
- Townsend JC, Selvin GJ, Griffin JR, Comer GW (1991) *Visual Fields – Clinical Case Presentations*. Boston, MA, Butterworth Heinemann
- Weinreb RN, Perlman JP (1986) The effect of refractive correction on automated perimetric thresholds. *American Journal of Ophthalmology*, **101**: 706
- Werner EB, Adelson A, Krupin T (1988) Effect of patient experience on the results of automated perimetry in clinically stable glaucoma patients. *Ophthalmology*, **95**: 764
- Zalta AH (1989) Lens rim artefact in automated threshold perimetry. *Ophthalmology*, **96**: 1302

# Chapter 8

## Optic tract

### Anatomy\*

---

The retinal nerve fibres, after having passed through the optic chiasm, travel posteriorly toward the lateral geniculate body by way of the optic tracts. The optic tracts sweep laterally from the optic chiasm, passing around the ventral portion of the midbrain and encircling the hypothalamus posteriorly. The majority of retinal nerve fibres terminate in the lateral geniculate body. A smaller number continue to the pretectal area (pupillary reflexes).

Each optic tract contains crossed nasal retinal fibres that originate in the contralateral nasal hemiretina and uncrossed temporal retinal fibres that originate in the ipsilateral temporal hemiretina. The nerve fibres from corresponding retinal areas are not, however, paired straight away in the optic tract.

As the crossed and uncrossed retinal nerve fibres, corresponding to an entire hemifield, eventually converge, the crossed nasal inferior retinal nerve fibres become related to uncrossed temporal inferior retinal nerve fibres, and crossed superior retinal nerve fibres become related to uncrossed superior retinal nerve fibres. The macular fibres come to lie superolaterally. The nerve fibres from both superior retinas are located superomedially and the nerve fibres from both inferior retinas are located inferolaterally. The retinotopic map is tilted in the optic tracts so that the macula is represented dorsally, inferior retina laterally and superior retina medially.

The optic tracts obtain their blood supply via a pial plexus. This is continuous anteriorly with that of the optic chiasm and fed partly from the posterior communicating artery but mainly from the anterior choroidal artery. It is also supplied by branches of the middle cerebral artery (Francois *et al.* 1956).

---

\* This anatomy section is intended as a brief description only. If required, further detail should be sought from appropriate textbooks – see Further reading. The anatomy and pathology sections, in combination, provide a background to the part of the visual pathway covered in this chapter so that the relevant visual field defects can be considered and interpreted appropriately.

## **Pathology\***

---

Optic tract defects are uncommon, and lesions of the optic tract are similar to those causing damage to the optic chiasm. Typically these include pituitary adenomas with posterior extension, craniopharyngioma and other parasellar tumours, demyelination and vascular abnormalities. Most commonly, optic tract defects result from a compressive tumour extending posteriorly from the optic chiasm area, or trauma at the time of surgical removal of the tumour.

Less common causes of optic tract pathology include inflammatory conditions (such as multiple sclerosis and sarcoid), migraine, trauma and radiotherapy.

### **Craniopharyngioma**

These are slow growing tumours arising from the vestigial remnants of Rathke's pouch along the pituitary stalk (Fig. 8.1). The tumour compresses the tract from above and ventrally.

### **Meningioma**

Meningiomas that involve the optic tract may arise from the tuberculum sellae or lesser wing of sphenoid and are slow growing. These tumours typically affect middle aged women and often cause hyperosmosis which can be seen on a plain skull X-ray.

### **Pituitary tumours**

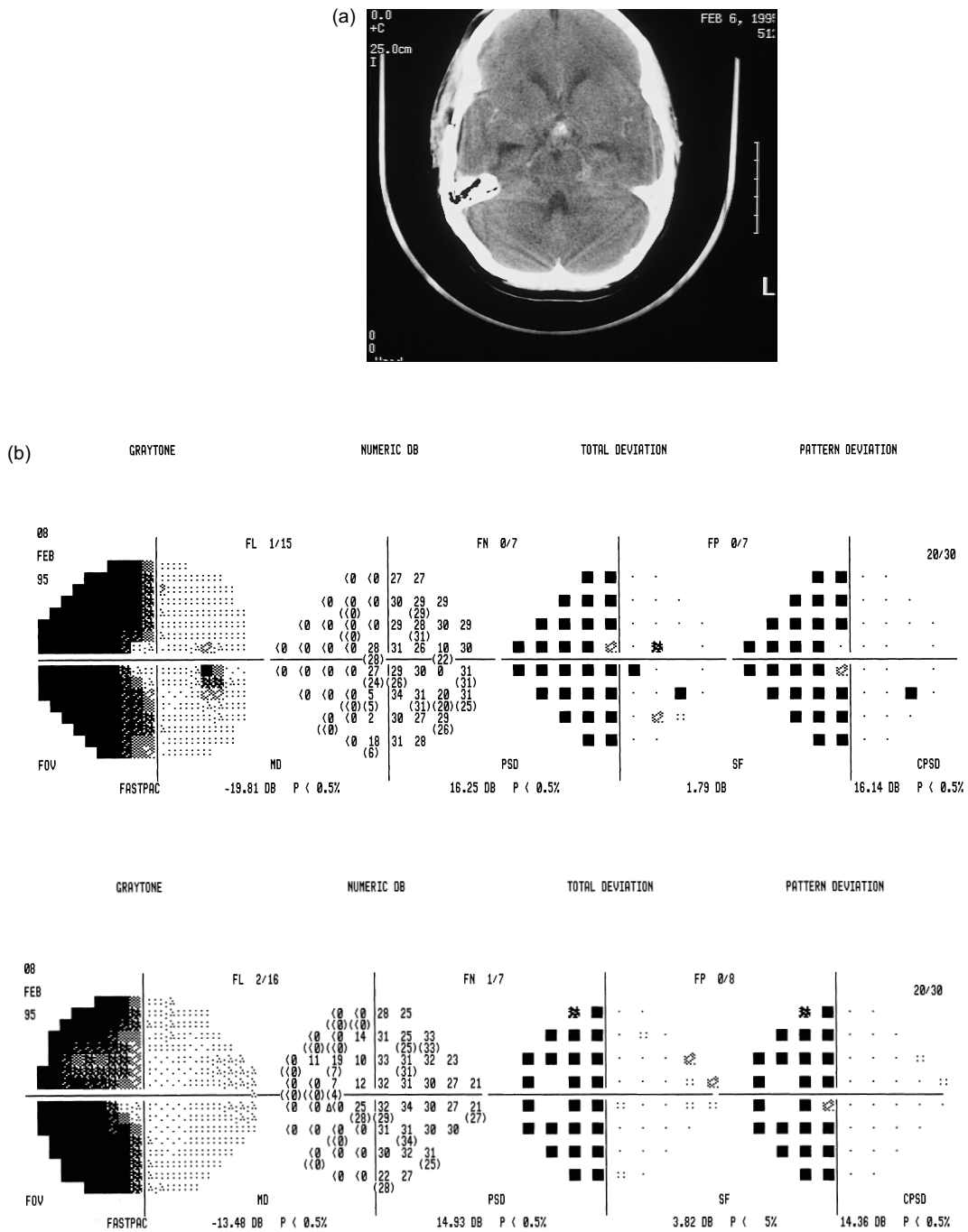
In approximately 10% of normal subjects, the optic chiasm is situated more anteriorly over the tuberculum sellae – prefixed (Walsh & Hoyt 1982). In this situation, pituitary tumours may compress the optic tract first, resulting in homonymous defects (Trobe 1974; see Fig. 7.14).

### **Trauma**

In trauma, acceleration/deceleration injuries are caused by the movement of the brain relative to the skull. The impact to the head produces a rapid movement of both the skull and brain in the direction of the force. The brain lags behind the faster moving skull resulting in high pressure in the brain at the area of impact and low pressure at the counter pole. Shock waves are induced and are transmitted through the brain causing damage to the visual pathway (diffuse axonal injury or shearing injuries). Intracranial effects include effects from haemorrhage or ischaemia.

---

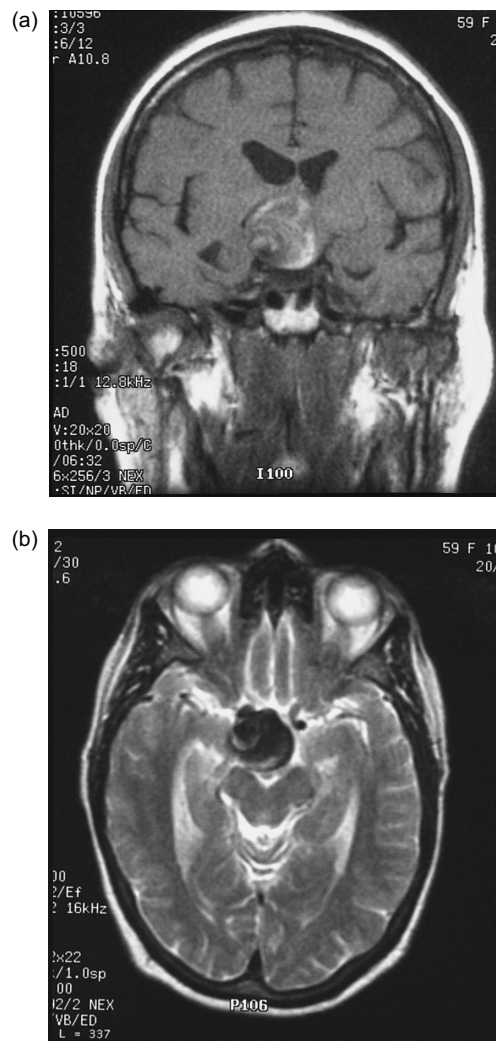
\* This pathology section is provided as a summary of possible disease processes but by its nature cannot be all inclusive. The reader is directed towards other appropriate textbooks for further detail – see Further reading.



**Figure 8.1** Craniopharyngioma. (a) On neuroimaging a mass lesion is evident centrally in the middle cranial fossa. (b) On visual field assessment there is an incongruous left homonymous hemianopia. Note the decibel values in particular and the probability plots. Central vision is retained.

## Vascular abnormalities

Vascular lesions may include a cerebrovascular accident (stroke) with involvement of the anterior choroidal artery, middle cerebral artery or posterior cerebral artery. Stroke is defined as a clinical syndrome consisting of rapidly developing signs of focal (or global) disturbance of cerebral function, lasting more than 24 hours or leading to death, with no apparent cause other than of vascular origin (World Health Organisation). There are two broad categories: (a) cerebral infarct as a result of a temporary or permanent occlusion of a feeding artery (extra- or intracranially) and



**Figure 8.2** Internal carotid artery aneurysm. (a,b) On neuroimaging note the mass effect of the aneurysm centrally. (c) On visual field assessment there is a left homonymous hemianopia which is congruous.

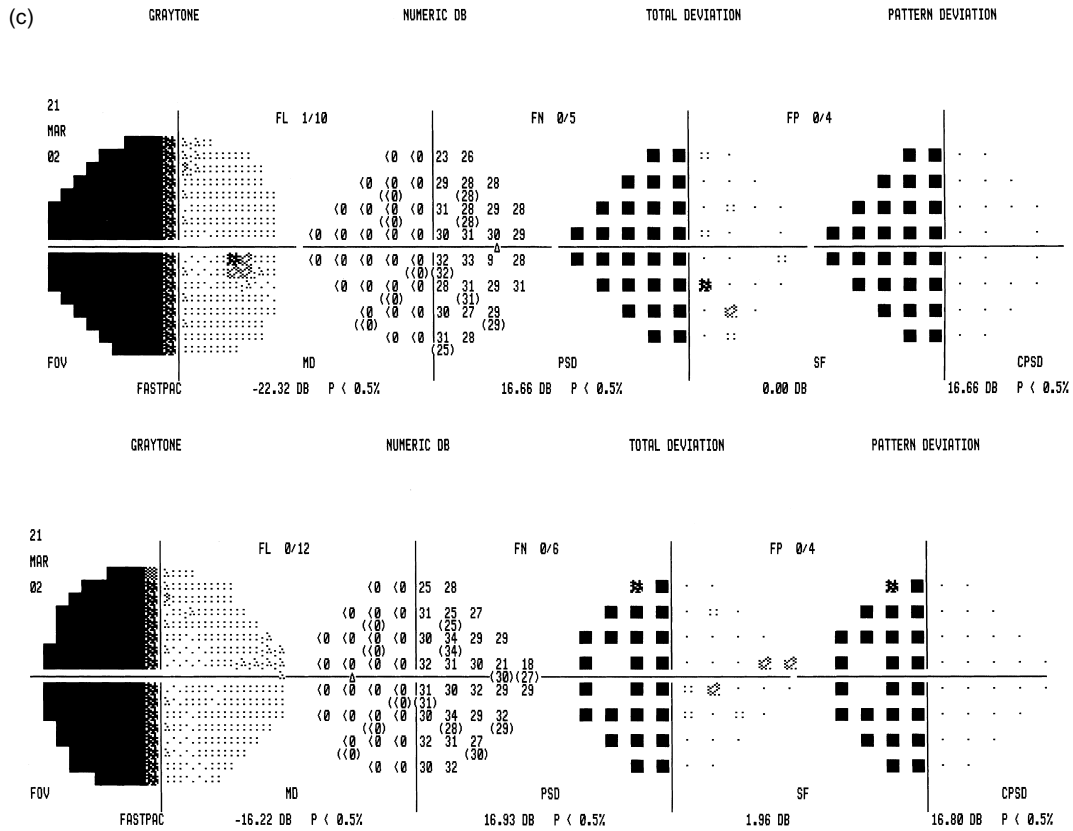


Figure 8.2 (Continued)

accounts for about 80% of strokes (Bamford 1992) and (b) cerebral haemorrhage due to a rupture of an abnormal artery (aneurysm or arteriovenous malformation) or arteriole in the brain parenchyma.

Optic tract involvement may also occur with suprasellar aneurysms (Fig. 8.2).

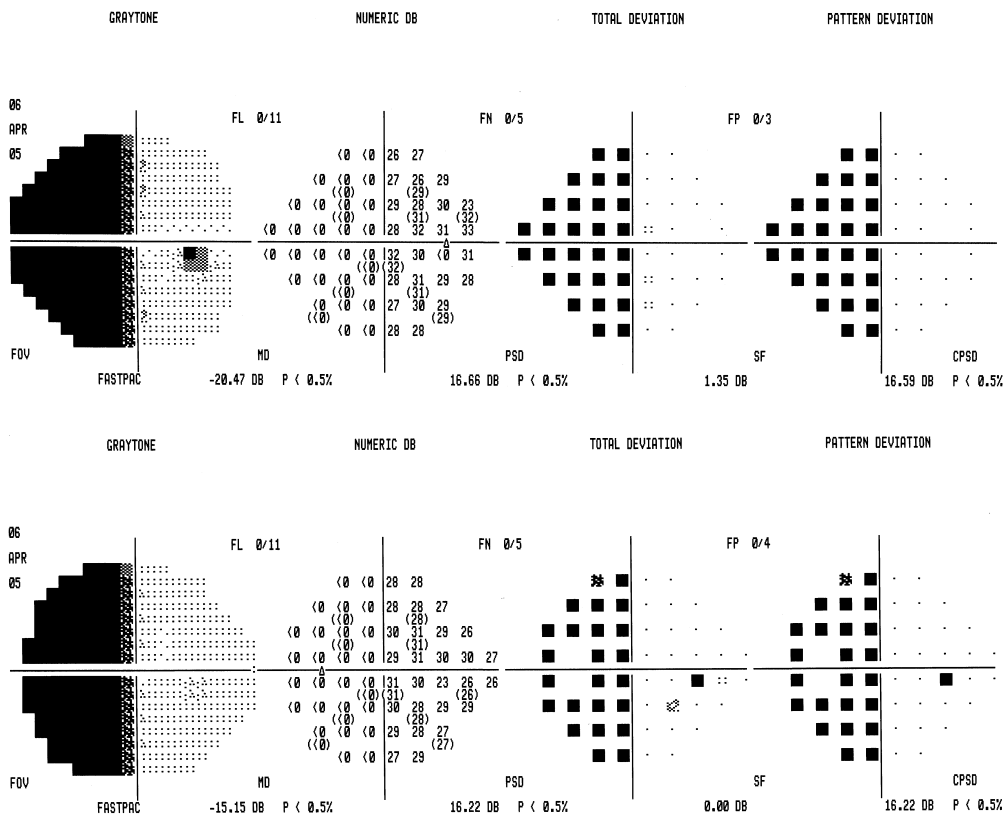
### Associated signs and symptoms\*

#### General signs

A lesion of the optic tract may damage the ipsilateral cerebral peduncle and give rise to mild contralateral pyramidal signs. Other associated abnormalities are unusual, but may include endocrine disturbances because of interference with hypothalamic function and memory impairment from temporal lobe involvement (Bender & Bodis Wollner 1978).

\* This section on associated signs and symptoms is provided so that the practitioner is aware of additional information that can be considered in conjunction with the visual field defect to aid differential diagnosis and localisation of pathology.





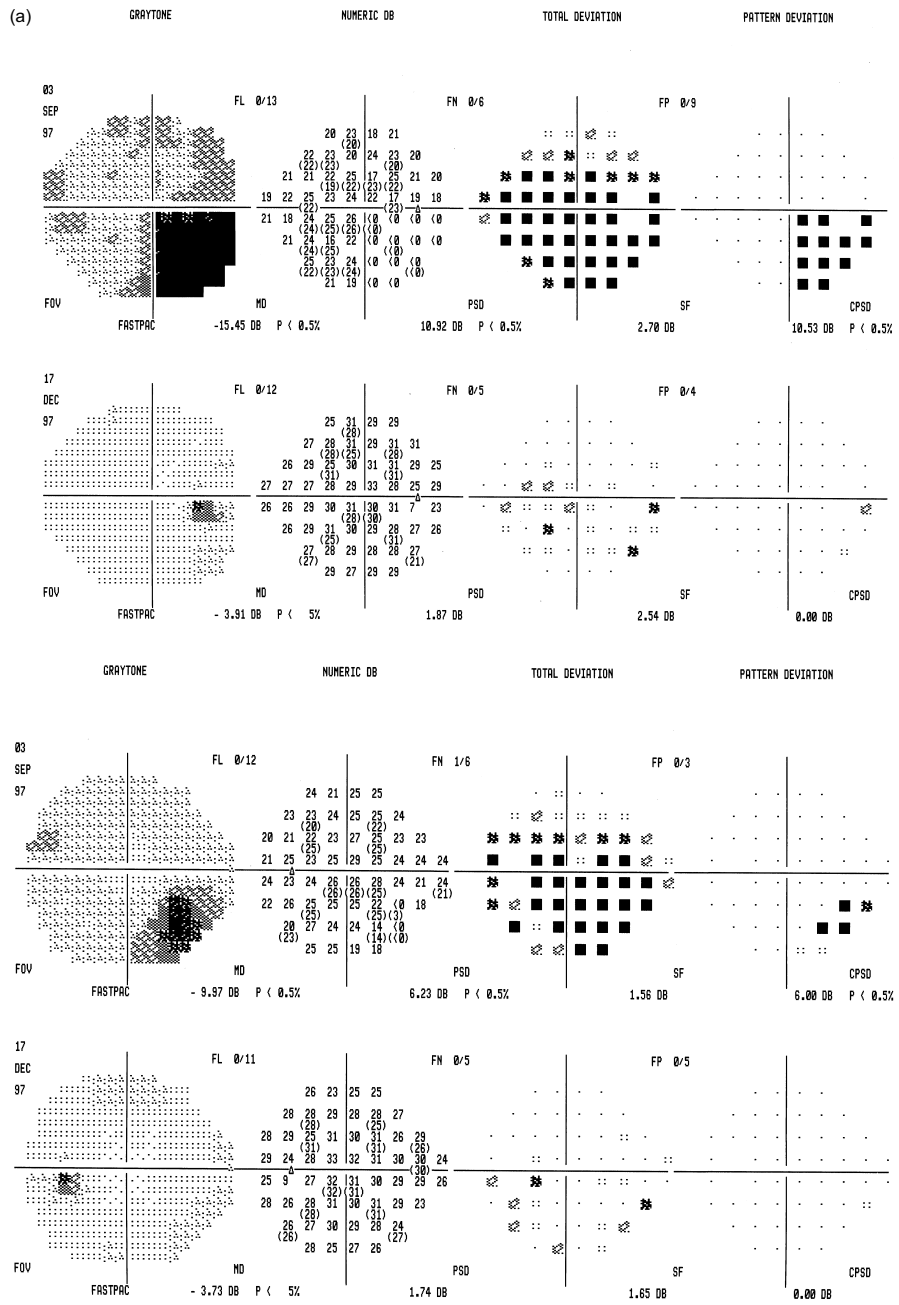
**Figure 8.3** Humphrey perimeter visual field assessment: migraine. There is a congruous complete left homonymous hemianopia.

Although they do not secrete hormones, craniopharyngiomas may interfere with hypothalamic function, and in children they may cause pituitary dwarfism, diabetes insipidus, delayed sexual development and occasionally obesity. Presentation in childhood is commonly related to hydrocephalus.

Pituitary adenomas occur with and without clinically manifest endocrine activity. Pituitary hormones include adrenocorticotrophic hormone (ACTH), thyroid stimulating hormone (TSH), luteinising hormone (LH), follicle stimulating hormone (FSH), somatotropin (STH) and prolactin. Ensuing non-ocular problems include Cushing syndrome, acromegaly, gigantism, infertility, amenorrhoea and galactorrhoea.

### Optic atrophy

Because the cell bodies of all nerve fibres in the optic tract are the retinal ganglion cells, optic atrophy may result when these fibres are damaged due to retrograde degeneration (Paul & Hoyt 1976).



**Figure 8.4** Humphrey perimeter visual field assessment: meningioma. (a) There is a mostly incongruous right homonymous hemianopia. The right eye shows temporal visual field loss, particularly in the inferior visual field, with inferior nasal loss also (note decibel values and probability plots). The left eye shows right inferior nasal visual field loss. Following surgery there is a vast improvement in visual field function which is evident also on the change analysis (b) with centralisation of the boxplot and increase in global indices.




Figure 8.4 (Continued)

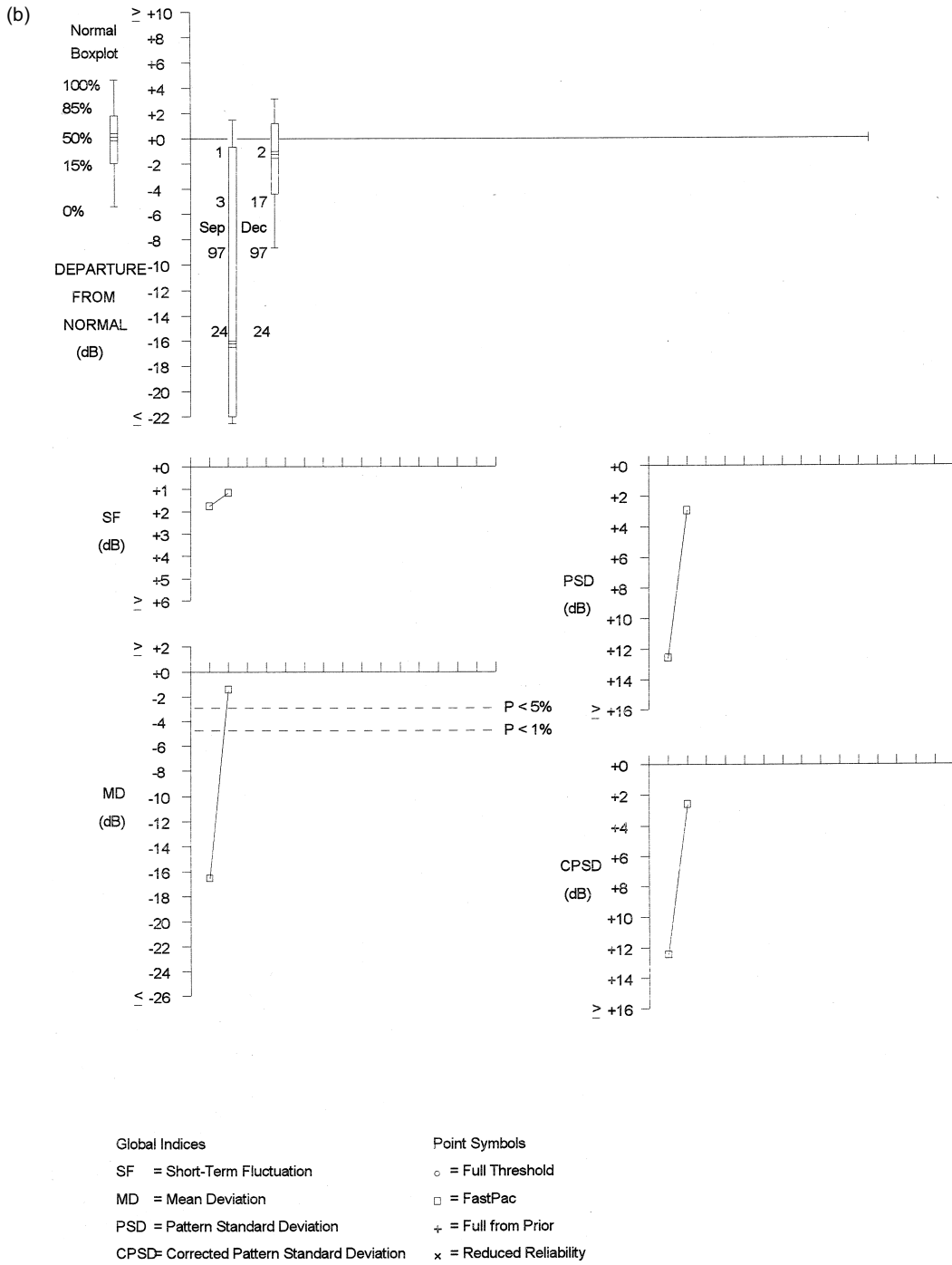


Figure 8.4 (Continued)

## **Pupil abnormalities**

The optic tracts contain retinal nerve fibres that subserve both visual and pupillary functions. The retinal nerve fibres terminate in the lateral geniculate body, but the pupillary nerve fibres leave the optic tract prior to the lateral geniculate body, project through the brachium of the superior colliculus and terminate in the pretectal nucleus. An optic tract lesion may therefore produce an afferent pupillary conduction defect. Typically, the pupillary light reaction is normal when the unaffected hemiretina is stimulated and absent when the involved hemiretina is stimulated. However, in practice, this Wernicke's hemianopic pupillary reaction is difficult to elicit.

The relative afferent pupillary defect is usually in the eye with the temporal visual field loss. This is attributed to the greater size of the temporal visual field and a slightly larger number of axons from the nasal than temporal retina (Bell & Thompson 1978).

## **Visual field defects**

---

In previous chapters, visual field loss has been described in relation to the pathological categories causing the visual field deficit. However, as various pathological categories tend to cause similar types of visual field loss in optic tract disease, it is the visual field loss that will be described in categories in this section.

Visual field defects are characterised by the marked incongruity of the field defect in association with an afferent pupillary defect on the same side as the hemianopia, from damage to the pupillary nerve fibres in the optic tract, and bilateral optic disc pallor.

### **Congruous visual field loss**

With marked involvement of the optic tract by pathological lesions, a complete homonymous hemianopia will be noted which has no localising value (Fig. 8.3).

### **Incongruous visual field loss**

Partial lesions of the optic tract will cause contralateral homonymous visual field defects, but the incomplete pairing of the retinal nerve fibres of the two eyes results in incongruity. Marked incongruity indicates an optic tract lesion, since lesions of the optic radiations tend to cause only mild incongruity and visual cortex lesions are highly congruous.

Incongruity can vary considerably, from marked dissimilarity of the two eyes (Fig. 8.4) to less dissimilarity (Fig. 8.1). Sometimes the visual fields will appear congruous, but careful examination of the sensitivities of the visual fields of either eye will reveal minor dissimilarities (Fig. 8.2).

The combination of optic atrophy, relative afferent pupillary defect and visual field incongruity are important to recognise in a patient with homonymous hemifield defects because the differential diagnosis of optic tract lesions differs greatly from that of lesions of the optic radiations or striate visual cortex. While visual field defects related to optic radiation or striate visual cortex lesions result from vascular disease and other intracerebral pathology, most optic tract lesions are compressive extrinsic masses. Elkington (1968) reported that homonymous hemianopia as a result of an optic tract lesion is uncommon, but is particularly associated with large and extensive tumours such as compression from a pituitary adenoma with a prefixed optic chiasm.

### Choice of visual field assessment

Central visual field assessment is usually sufficient to detect most field defects due to pathology of the optic tract. If pathology is suspected or known but there are no visual field defects centrally, a peripheral visual field test may demonstrate a homonymous loss of visual field in the peripheral field of vision. Peripheral visual field programmes should be undertaken if any doubt exists over the results of a central visual field programme or where full documentation of the entire visual field is required. Careful attention must be paid to the vertical meridia.

### References

- Bamford J (1992) Clinical examination in the diagnosis and subclassification of stroke. *Lancet*, **339**: 400
- Bell RA, Thompson HS (1978) Relative afferent pupillary defect in optic tract hemianopias. *American Journal of Ophthalmology*, **85**: 538
- Bender MB, Bodis Wollner I (1978) Visual dysfunctions in optic tract lesions. *Annals of Neurology*, **3**: 187
- Elkington SG (1968) Pituitary adenoma. Preoperative symptomatology in a series of 260 patients. *British Journal of Ophthalmology*, **52**: 322
- Francois J, Neetans A, Collette JM (1956) Vascularisation of the optic pathway IV. Optic tract and geniculate body. *British Journal of Ophthalmology*, **40**: 341
- Paul TO, Hoyt WF (1976) Fundoscopic appearance of papilloedema with optic tract atrophy. *Archives of Ophthalmology*, **94**: 467
- Trobe JD (1974) Chromophobe adenoma presenting with a hemianopic temporal arcuate scotoma. *American Journal of Ophthalmology*, **77**: 388
- Walsh FB, Hoyt WF (1982) *Clinical Neuro-Ophthalmology*, 4th edn. Vol. 1 (ed. N Miller) Baltimore, Williams and Wilkins; pp.60–68, 119–129
- World Health Organisation. [www.who.int/en](http://www.who.int/en)

### Further reading

- Adler FH, Kaufman PL (eds) (2002) *Adler's Physiology of the Eye. Clinical Application*, 10th edn. St Louis, Mosby

- Jacobson DM (1997) The localizing value of a quadrantanopia. *Archives of Neurology*, **54**: 401
- Kanski J (2003) *Clinical Ophthalmology. A Systematic Approach*, 5th edn. London, Butterworth Heinemann
- Kanski J (2004) *Clinical Ophthalmology. A Synopsis*. London, Butterworth Heinemann/Elsevier Science
- Newman SA, Miller NR (1983) The optic tract syndrome; neuro-ophthalmologic considerations. *Archives of Ophthalmology*, **101**: 1241
- Olver J, Cassidy L (2005) *Ophthalmology at a Glance*. Oxford, Blackwell Publishing
- Plant GT, Kermode AG, Turano G, Moseley IF, Miller DH, MacManus DG, Halliday AM, McDonald WI (1992) Symptomatic retrochiasmal lesions in multiple sclerosis. Clinical features, visual evoked potentials and magnetic resonance imaging. *Neurology*, **42**: 68
- Savino PJ, Paris M, Schatz NJ, Orr LS, Corbett JJ (1978) Optic tract syndrome: a review of 21 patients. *Archives of Ophthalmology*, **96**: 656
- Smith JL (1962) Homonymous hemianopia: a review of one hundred cases. *American Journal of Ophthalmology*, **54**: 616
- Snell RS, Lemp MA (1998) *Clinical Anatomy of the Eye*, 2nd edn. Oxford, Blackwell Publishing
- Wilbrand HL (1926) Schema des verlaufs der sehnervenfasern durch das chiasma. *Zeitschrift für Augenheilkunde* **59**: 135