

1: The History

Neurology remains the specialty in medicine that still requires a good history and examination to diagnose a puzzle. It is ultimately logical and the approach leads the physician to localize the lesion to a part of the neuraxis and then develop a differential diagnosis based on this localization. The imaging tools are now superb, but must be applied correctly and their limitations understood. There is no imaging device that can diagnose a migraine headache. A purist might argue that a spreading depression of Leão might accomplish this with positron emission tomography (PET), but unfortunately other pathologies can cause the same physiology. Magnetic resonance imaging (MRI) does not evaluate bones well because a signal cannot be generated from a calcium lattice (no free H^+). A negative MRI of the spine in a patient with clear L5–S1 symptomatology, a weak extensor hallucis longus muscle and a depressed ankle jerk has overwhelming evidence of L5, S1 pathology. An older patient has bone disease of the spine rather than disk disease. This is not understood by most who hold the MRI as the gold standard for diagnosis of spinal problems. Complicated spine problems require a myelogram with contrast to evaluate the relationship of the nerve root to the facet, pedicle and exit foramina. These studies may be negative, but the patient still complains of severe L5–S1 pain. Recent information suggests that inflammatory cytokines released at an area of injury may directly stimulate C and A-delta pain fibers. If all imaging studies are negative as well as the electromyogram (EMG), but the history and the neurologic examination is positive, the examiner believes the patient and does the best that can be done to relieve the pain.

A productive way to look at modern neurology is that the history gives the diagnosis, the neurologic examination proves it and modern imaging and laboratory tests guide the treatment and predict the prognosis.

Localization by chief complaint

An accurate chief complaint must be given by the patient if possible. Specific pathologies cause very specific chief complaints although the patient may have severe simultaneous deficits. These cannot be summarized as the examiner loses the flavor of the core of the process.

Inability to express oneself with intact understanding is almost always a problem in Broca's area (44), the supplementary motor cortex or, rarely, the thalamus. Inability to understand the spoken word, with sudden onset and no other symptomatology in a patient with atrial fibrillation almost

CHAPTER 1
The History

always indicates an embolus to the inferior division of the middle cerebral artery that involves the superior temporal gyrus (Broadman's area 21, 22) or Wernicke's area.

A patient with severe short-term memory loss, retained social graces and some parietal symptomatology has Alzheimer's disease until proven otherwise. A patient who appears demented, but fluctuates in disease severity and has visual hallucinations most often has diffuse Lewy body disease.

Behavioral neurology is based on deficits in distributed loops, which is how nuclei of the brain interact one with the other. This physiology is the basis for the chief complaint. If the caregiver states that their charge seems to be able to see, but cannot reach objects, the examiner suspects a vascular or mass lesion that interrupts posterior parietal areas that integrate visual information with hand function (Balint's syndrome).

Any chief complaint that incorporates an agnosia, an inability to recognize an object, sound or tactile sensation with intact primary visual, auditory and somesthetic primary modality function, suggests a cortical process. Apraxias, in which a patient has normal strength, coordination and sensory abilities but cannot perform specific one command or sequential command motor acts, suggests cortical pathology. The chief complaint of these patients, often related by the caregiver, is, "Mr. Jones can no longer tie his shoes or use the telephone."

Knowledge of personal spaces that one can touch, and extrapersonal space, is biased toward the right parietal lobe. Patients with posterior right parietal lobe lesions ignore the left side of space. They frequently bump into objects on the left side of their personal space because they are unaware of it. These patients often are seen in the Emergency Room as a result of car accidents. The patient is frequently unaware of the deficit.

Each component of the cortex has anatomy and physiology that leads to a specific chief complaint.

The speed of development of the chief complaint gives insight into localization and pathologic process. If Mr. Jones's caregiver states that he is very rapidly losing intellectual function over a matter of weeks and has developed abnormal movements (myoclonus), the diagnosis is most likely prion disease of the classic Creutzfeldt–Jakob variety. A patient who is focused on a severe right parietal headache, particularly with standing and associated weakness of the left side, is an excellent candidate for a right-sided subdural or hemispheric brain tumor.

Seizures are particularly likely to announce their origin in the brain by their inscription, the initial area of discharge. A patient who states, prior to losing consciousness, that he or she smelled "rotting garbage" has a discharge from the uncus of the hippocampal gyrus. The examiner suspects seizures from the length of time the patient lost consciousness and was not completely him or herself. Seizures cause a change of mental states for minutes to hours in most instances. A syncopal attack, whether vagovagal or vasodepressor, lasts seconds. A cardiac arrhythmia causes loss of consciousness for 30 seconds to 1 minute unless it results in death. A transient

ischemic attack (TIA) of the posterior or anterior circulation usually does not cause loss of consciousness. Shaking or apparent clonus may occur with weakness of an extremity from a carotid TIA. A drop attack, most often from posterior circulation ischemia of the medial reticular formation or possibly the cerebral peduncle or medullary pyramidal tract, does not cause loss of consciousness in most instances. Patients appear stunned. In a TIA, the larger the embolic material (red from the heart), the larger and longer the ischemic deficit. Most TIAs are short, 30 seconds to 2 minutes, and the emboli material seen in retinal arteries is yellow (cholesterol) from an intra-arterial source. A patient's chief complaint of falling when arising in the morning on the way to the bathroom suggests a thrombosis of the right middle cerebral artery (MCA), which leaves him unaware of the left side. Thrombotic strokes occur in the morning (4–6 AM), whereas emboli and hypertensive hemorrhages occur during the day.

Falling as a major complaint is common in elderly patients. The examiner determines in which direction the patient falls. Falling backwards is common with all basal ganglia disease, but particularly progressive supranuclear palsy, normal pressure hydrocephalus and acquired hepatolenticular degeneration. Falling to one side is indicative of cerebellar disease or contralateral hemispheric disease. A patient stating that he or she is "pushed" to a "side" or "driven" to a side often has vestibular disease. Recently, posterior thalamic hemorrhages have been shown to cause patients to push away from the lesioned side. This lesion causes a deficit in the patient's sense of where their body is in relation to the vertical plane (an internal compass now known as the subjective visual vertical or SVV). These patients are known as "pushers." Falling or being "pushed" forward is disease of the utriculus and sacculus.

The most prominent complaint of patients with basal ganglia disease is often difficulty with walking. The problem is frequently one of gait ignition failure. A similar gait difficulty occurs with normal pressure hydrocephalus (NPH) but is associated with cognitive decline and precipitates micturition. The patient with Parkinson's disease, in addition to the major difficulty with gait, complains of drooling, stiffness, tremor and fatigue. While taking this history, the examiner notes a serpentine stare, failure to blink (less than 14 times/minute) and a paucity of spontaneous movements. The patient will give the major complaint in a low voice.

If tremor is the major concern of the patient, the examiner can immediately and logically separate the process as one emanating from the basal ganglia or the cerebellum and its connections. In general, the tremor occurs at rest or with intention. A pill rolling tremor at rest (4–7, H2) with flexion of the metacarpophalangeal joint indicates Parkinson's disease. Tremors that occur with intention emanate from the cerebellum or its connections. A side-to-side tremor is strong evidence of an essential cerebellar tremor. An intention tremor with major oscillations is a cerebellar outflow or a rubral tremor. If it occurs in a young patient, the usual diagnosis is multiple sclerosis (MS). If it appears after head trauma, the midbrain (areas close to

CHAPTER 1
The History

the red nucleus) is damaged. Rarely, movement disorder indicates choreo-athetosis, myoclonus or dystonia.

Most patients with primary brainstem lesions complain of diplopia, dysphagia or dysarthria. Oscillopsia, in which objects in the environment are “jumping up or down” or otherwise moving, occurs with acute nystagmus. If the examiner notes severe nystagmus but the patient does not complain of oscillopsia, it has been compensated and is of long duration.

The outstanding complaint of patients with cerebellar disease is being “off balance” or “walking like a drunk.” These patients also complain of poor handwriting that is too large, sloppy and not legible. They have major difficulty with fine movements such as drinking coffee or buttoning a shirt. If dysarthria is prominent, a spinocerebellar degeneration is suspected (degeneration of the left paravermian zone). Alcoholic cerebellar degeneration primarily affects the anterior lobules of the vermis and gait is more affected than the arm, speech or eyes (minimal nystagmus). Pes cavus is frequently seen with hereditary cerebellar degeneration and dysarthria. Vestibular disease patients often complain of being lightheaded or, as noted earlier, may feel as if they are being pushed.

Intrinsic or extrinsic spinal cord disease is often announced by the feeling of a tight band around the chest. This may at times be painful and unilateral. Patients feel that their legs are heavy after they walk a few blocks. They usually are unaware that bladder, bowel and coordination are affected. If bilateral optic neuritis and concomitant spinal cord involvement occurs, this is most often Devic’s disease, a variant of MS. The usual band is felt at T1–T4 but this is often a dropped level because of cervical cord inflammation that affects the lamination of the spinothalamic tract. If the band is painful at T1–T4, cardiac disease is often suspected. An electrocardiogram (ECG) is certainly justified, but weak legs certainly suggest a spinal cord origin of the constrictive band sensation.

Fatigue as a major component of a neurologic symptom complex is characteristic of demyelinating, chronic fatigue syndrome and basal ganglia disease. It is a major and often the chief complaint of patients with depression, cancer, anemia, thyroid, congestive heart failure and Addison’s disease. If the patient with severe fatigue also complains of Lhermitte’s sign (paresthesias of the hands and arms with neck flexion) and is 20–40 years of age, the most likely diagnosis is MS.

The chief complaint of patients with diseases of the peripheral nervous system is equally as helpful as those who have disease of the central nervous system (CNS) in identifying whether the problem is at a root, plexus, neuromuscular junction or muscle level. The specific, sensory, chief complaint of the patient with a peripheral neuropathy identifies the size of the affected fibers which, when coupled with the pattern, evolution and associated features of the process, allow the examiner to categorize the neuropathy immediately.

Burning feet suggests that C fibers (1 μm unmyelinated) are spontaneously firing. If the strength and reflexes are relatively preserved, the

patient has a small fiber neuropathy. The usual causes are diabetes, alcohol or human immunodeficiency virus (HIV). Unusual causes are Sjögren's syndrome, an autoimmune or specific antigens of the peripheral nerve. Numbness and slight weakness of the lower extremities suggests a dying back or metabolic neuropathy. This impression is further enhanced if the patient states that when the numbness reached the knees he or she started to lose sensation in the fingers. A similar process obtains with the intercostal nerves whose distal-most fibers innervate the anterior chest wall. This causes a "shield pattern" of sensory loss. The size of fibers that are involved in many metabolic dying back neuropathies are 8–10 μm in diameter. They mediate light touch, tap, pressure and motor function. In distinction to patients with a metabolic or dying back neuropathy, patients who complain of minimal numbness but extreme weakness of the legs that is progressing have Guillain-Barré syndrome. In this instance, large neurons of the dorsal root ganglia as well as an alpha fiber (12–22 μm) are affected.

Asymmetric weakness initially striking the upper rather than the lower extremities suggests an autoimmune large fiber neuropathy, with the GM1 epitope as the antigenic stimulus. A small fiber neuropathy is suggested by coldness of the hands (involvement of 1 μm sympathetic fibers that innervate blood vessels) and low blood pressure with intact strength and reflexes.

Lancinating pain is characteristic of root disease and is carried by A-delta (1–4 μm) thinly myelinated fibers. They are often the first impinged upon by an extruded disk that compresses the lateral component of the dorsal root entry zone as it pierces the dura on its way to the dorsal horn of the spinal cord. If this pain radiates into the buttock, lateral thigh and dorsum of the foot to the great toe, the L5 root is the culprit. In general, upper extremity radicular disease radiates to the shoulder, spinous processes and, rarely, to the fingers. Lower extremity radicular pain characteristically radiates to the toe and foot as well as back and buttock. Disturbing to both patient and examiner is the fact that radicular pain is often "striplike" in character. One day it is lateral thigh, the next, back and buttock, and the following week the top of the foot and great toe. It rarely covers the entire distribution of the root. As the more medial fibers of the dorsal root entry zone are compressed, sensations switch from lancinating to paresthetic and then to numbness. Patients may also complain of the blended sensations of burning, numbness and cold lancinating pain.

In the lower extremity, the examiner is able to utilize quality of sensation distribution of sensory abnormality and exacerbating and relieving factors to deduce both physiology and pathology. A patient with spinal stenosis will state that he or she can only walk a block or so and then has to rest because his or her legs are heavy and painful. The most pain is often in the calves and is usually described as a cramp, tightness or a "charley horse." These are neurogenic cramps from activation of deep muscle A-delta pain afferents. A patient with vascular insufficiency of the iliac arteries complains of tightness and a burning sensation in the calves, thighs and buttocks. The burning sensation is from activation of C fibers due to lactic

CHAPTER 1
The History

acidosis. Someone with Buerger's disease has intermittent claudication of the inner side of the foot. Walking that causes intermittent claudication of vision indicates Takayasu's disease (pulseless disease of young women).

In general, the chief complaint of patients who suffer brachial plexus disease is pain. The usual cause is a traction injury such as a motor vehicle accident or fall on the outstretched upper extremity. The radiations are to the trapezius ridge and medial scapular border (upper trunk) as well as the 4th and 5th fingers (lower trunk). The sympathetic system is frequently activated abnormally and patients often gradually develop burning pain in a regional distribution (chronic regional pain syndrome). Unless there is actual avulsion of the roots such as occurs with severe trauma (motorcycle accident), weakness and wasting are less than that noted with radicular disease. As noted earlier, root disease in the upper extremity rarely reaches the hand. C4 radiates along the trapezius ridge, C5 to the cap of the shoulder and C6 to the lateral forearm and, rarely, to the thumb and index fingers. Thus, in general, a patient with pain or paresthesias that radiate into the hand have median or ulnar neuropathy or plexus disease.

Patients with the most common neuromuscular junction disease, myasthenia gravis, complain most commonly of cranial nerve dysfunction such as ptosis or diplopia and secondarily fatigue and weakness with exercise. The other neuromuscular junction illnesses are uncommon and have specific seminal symptoms. A patient with small cell cancer of the lung who has the paraneoplastic antibody induced Lambert-Eaton syndrome has a dry mouth and "load in the pants" gait. The patient has developed antibodies to the L-type calcium channels on the terminal twigs of the muscle fibers at the neuromuscular junction as well as to the salivary glands. These patients get stronger rather than weaker with exercise, as opposed to those with myasthenia gravis. Patients with botulism often present first with nausea and vomiting, ptosis and pupillary dilation in addition to pharyngeal and generalized weakness. On the other hand, tetanus strikes the masseter early and is noted for trismus, the patient reporting that he or she cannot open their mouth fully. Many patients with tetanus in the USA are intravenous drug abusers and come to the hospital late with severe stimulus-sensitive myoclonus.

Most muscle disease affects proximal muscle groups. Patients present with difficulty in getting out of a chair, holding their arms over their head or, rarely, with sore muscles. Patients with metabolic muscle disease present with cramps and, at times, myoglobinuria. After age 50, inclusion body myopathy should be suspected with acquired proximal myopathy, particularly if the forearm flexor muscles are involved.

In summary, each component of the neuraxis will generate a patient's chief complaint. This directs the examiner's attention to the relevant component of the neuraxis that has to be explored. It is surprisingly common to have patients describe their problems with the exact same words. Thus, each patient teaches the examiner.

The age of the patient is extremely important in determining a diagnosis as certain diseases occur at specific ages, which limits the differential diagnosis. In a young person, loss of consciousness for a few minutes is more likely to be a seizure than a cardiac arrhythmia. Double vision in a 20-year-old is more likely to be myasthenia gravis than brainstem vascular disease. A cerebellar tumor prior to age 12 will most likely be a medulloblastoma. A glioma, astrocytoma or ependymoma is more common at 15–20 years of age. If benign and lateral in a middle-aged man, it is likely to be a hemangioblastoma. A cerebellar lesion that occurs between the ages of 40 and 60 years will most often be a metastasis.

Clarifying the symptoms

What is important to the patient and the neurology resident may not be particularly relevant. Always listen carefully to the patient's symptoms and then use positive and negative questions to clarify the issue. In any pain problem, the examiner must identify:

- 1 the mode of onset;
- 2 the quality and severity of the pain;
- 3 its radiations;
- 4 relieving and exacerbating factors;
- 5 associated signs and symptoms.

It is rare that the diagnosis will be missed if this plan is followed. Dizziness is hard to clarify with anyone. Patients describe dizziness as lightheadedness, presyncope or a rotary feeling. Usually, the examiner can tease out if the environment seems to be moving or the patient (subjective vs. objective) and, most importantly, if there are any other associated signs or symptoms such as weakness, numbness or difficulty swallowing. If the symptom is just related to dizziness and there are no associated signs and symptoms, overwhelmingly the cause is peripheral (i.e., from the nerve or the labyrinth). Weakness, cranial nerve involvement and sensory loss make it a brainstem problem. Rarely, dizziness associated with weakness can be in the carotid rather than posterior circulation territory (the intraparietal sulcus receives vestibular input). The cortex receives all sensory projections and blends them into a perception.

Exact radiations of pain or distributions of sensory loss are very important. Numbness around both sides of the mouth is often ischemia of descending tracts of the sensory component of the fifth nerve. At the corner of the mouth and in association with the thumb and index finger, a cheiro-oral pattern is often seen with migraine. A tongue that is numb on one side alone is brainstem ischemia, while bilateral intra-oral numbness is of thalamic origin.

Each process that the patient suffers has a characteristic pattern, which is rarely psychiatric in origin. Patients do not like or pay doctors; they come to you because they are sick.

Mode of onset and progression

Apoplectic deficits in neurologic patients are vascular or seizures. A patient who has a sudden overwhelming headache and then collapses with no focal signs has a subarachnoid hemorrhage. A middle-aged plethoric hypertensive male who collapses with a flaccid hemiparesis has a deep basal ganglionic hemorrhage. The patient who, while at the dinner table, is suddenly stunned and cannot speak has suffered an embolus. If the patient has atrial fibrillation, the embolus will go to the inferior division of the middle cerebral artery and affect Wernicke's area and he or she may speak incessantly, but incoherently.

Sudden loss of consciousness may be preceded by an aura such as smelling "something rotten." This is not an instantaneous perception and is most often a complex partial seizure. Dementia that is slowly progressive over 2 years and is predominantly associated with memory deficit is Alzheimer's disease. If the dementia is rapidly progressive over 3 months without weakness, it will be Creutzfeldt–Jakob disease. If focal signs are present, the most likely diagnosis is a frontal lobe mass lesion.

The examiner must determine if the process is steadily progressive, remittent or increasing in small steps. Relapsing and remitting processes suggest demyelinating disease if in the CNS or chronic inflammatory polyneuropathy (CIDP) if the peripheral nervous system is involved. An examiner may encounter episodic ataxia or a periodic paralysis that causes intermittent paralysis; both are channelopathies (abnormalities of components of calcium or sodium channels).

Chronologic sequence of events

This aspect of history taking will give very helpful information as to pathology. Neurologic function degenerates in the face of mass lesions, not only because of their destructive aspects in the local area of growth, but also by pressure or hydrocephalus. A patient with multi-infarct dementia will have a series of well-documented vascular events. Unfortunately, he or she may be unlucky enough to have concomitant Alzheimer's disease. Demyelinating disease gradually destroys much of the brain even in the face of normal-appearing white matter on MRI (MR spectroscopy demonstrates that it is not). Relapsing–remitting disease responds better than primary or secondary progressive disease to immunomodulation. All neurologic processes have a specific progression of loss of neurologic function which, if identified, leads to changes in therapy as well as corroboration of the initial diagnosis. A patient originally diagnosed with MS resulting from an isolated deficit, but without characteristic involvement of neural structures both in time and space, may have anything from Lyme's disease to metachromatic leukodystrophy. It is always wise to keep evaluating patients in light of the natural history of their diagnosis and response to therapy. Polymyositis that is not responding to therapy with immunosuppressants

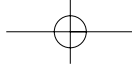
suggests an alternate diagnosis of inclusion body myositis. Similarly, a patient with an akinetic-rigid syndrome with many parkinsonian features, but a poor response to levodopa, should raise suspicion of multiple system atrophy as the correct diagnosis.

Value of negative information

Negative information is crucial in defining the fine points of the clinical history. It is similar to sculpture. Most of the history will outline the general category of disease, but the use of negative information sculpts the fine points. An episodic headache in a male that is severe, periodic, radiates to the eye at the same time during the night suggests cluster headache. If the examiner inquires about the trigeminal aspects of the headache, dilation of conjunctival vessels and tearing, it may be the entity of sudden neuralgiform pain with conjunctival injection and tearing (SUNCT). Most will be cluster headaches as this is common whereas SUNCT is not. A strong family history of migraine in a patient who has fortification scotomata but without headache would suggest a migraine variant (acephalgic migraine). A negative family history will direct the examiner's attention to a possible lesion of the occipital lobe. Inquiring in regard to palinopsia (visual perseveration) and photopsia (spontaneous patterns) are helpful in placing a lesion in the occipital lobe or parietal-occipital junction, respectively. Nowhere in medicine is being a "splitter" (knowing the fine points between different entities) more important than being a "lumper" (knowing the general categories of disease). "Splitters" are smart and "lumpers" are lazy (a usual excuse for saying "Why do I have to know that?"). The reason to know the fine points of entities is to guide therapy and to be sure of the correct diagnosis. A patient with a paralyzed leg equal in extent to the paralysis of the face and arm but with a severe aphasia probably has a myocardial infarction (MI) (first division)/MCA occlusion rather than the precentral branch of the superior division of the MCA from the carotid artery. Intra-arterial urokinase is much more effective for possible therapy than intravenous tissue plasminogen activator (TPA) in this instance.

Excluding irrelevancies

This aspect of the history is very difficult for many physicians. The history guides one from A to B. Patients frequently are driven to recite all of the hospitalizations, physicians and missed diagnoses that have befallen them. It is best to take this mostly irrelevant, written information from the patient and place it on your side of the desk. Otherwise, a great deal of the history will be distraction as he or she fiddles with the papers instead of listening to your questions and trying to give a correct answer. Assure the patient that all of the information they have brought to the office will be examined later. It is best to have the patient directly in front of you as you write notes so they are not distracted. The physician who looks at MRI films while



CHAPTER 1
The History

taking the history finds it difficult to form an independent judgment of the pathology and will no longer use his or her best judgment, skills and examination to form an opinion. Read the films after examining the patient. Unfortunately, this rarely occurs at any level of practice.

Interviewing relatives

The relatives, if present with the patient, can give valuable information as regards the family history, the events leading up to a loss of consciousness or the mode of onset of the neurologic event. If the patient is suspected of having a peripheral neuropathy or spastic paraparesis, looking at the relative's feet for pes cavus and testing their reflexes may be helpful.

