

Block

ONE

Questions

## Setting 1: Community-Based Health Center

You work at a community-based health facility where patients seeking both routine and urgent care are encountered. Many patients are members of low-income groups; many are ethnic minorities. Several industrial parks and local businesses send their employees to the health center for treatment of on-the-job injuries and employee health screening. There is a facility that provides x-ray films, but CT and MRI scans must be arranged at other facilities. Laboratory services are available.

8 • Blueprints Q&A Step 3 Medicine

17. A 19-year-old white man is brought to your clinic by his parents. They are concerned that he has become more "distant." He has lost 20 pounds in the past 4 months and has intermittent abdominal pain and headaches. He has also complained of increasing fatigue. He denies having any past medical problems, or using tobacco, alcohol, or drugs. HR is 110, RR is 18, BP is 90/60, and oxygen saturations are 99% on room air. On examination he appears thin and withdrawn, and his skin has a tanned appearance noted in the skin folds, palmar creases, and along the dentate line of the gums. Lungs are clear, and heart is tachycardic without murmur. Abdomen is soft without hepatosplenomegaly. You order basic laboratory studies that show a normal CBC and a BMP with the following values: sodium 130 mEq/L, potassium of 6.0 mEq/L, chloride 107 mEq/L, bicarbonate 20 mEq/L, BUN 18 mg/dL, creatinine 0.8 mg/dL. What other laboratory study would be the best to help confirm the diagnosis?

- A. Random cortisol
- B. A.M. serum cortisol
- C. P.M. serum cortisol
- D. Cosyntropin stimulation test
- E. Serum glucose

18. A 65-year-old Hispanic woman comes to your clinic with complaints of irritability and depression for the past several months. She also notes an intermittent sensation of numbness around her mouth. She has a history of anxiety disorder and chronic renal insufficiency secondary to poorly controlled hypertension. Past surgeries include an appendectomy and thyroidectomy 1 year ago secondary to a large goiter. On physical examination the patient appears anxious. Vital signs are within normal limits, with the exception of a BP of 190/79 mm Hg. As you recheck her BP, you note carpal spasm. This patient's problem is most likely caused by:

- A. Renal failure
- B. Pseudohypoparathyroidism
- C. Vitamin D deficiency
- D. Malignancy
- E. Hypoparathyroidism

19. A 35-year-old woman presents to your clinic with complaints of headache and muscle weakness. She notes that she just recently checked her BP at the drug store and it read "high." She denies having any other medical problems or using any medications. She also denies using any tobacco, drug, or alcohol. The patient is afebrile, HR is 88, RR is 12, and BP is 180/90 mm Hg. Results of her examination are otherwise noncontributory. Basic laboratory studies reveal the following: sodium 145 mEq/L, potassium 2.5 mEq/L, bicarbonate 30 mEq/L, BUN 10 mg/dL, creatinine 1.0 mg/dL, renin (upright posture) 0.1 ng/mL, and aldosterone (upright posture) 200 ng/dL. What is the likely cause of her symptoms?

- A. Cushing's syndrome
- B. Licorice ingestion
- C. Conn's syndrome
- D. Renal artery stenosis
- E. Renal hypoperfusion

20. A 40-year-old white male kindergarten teacher presents to your clinic with 3 weeks of fatigue and pallor. He denies having fever, chills, or weight loss, but has noted gum bleeding while brushing his teeth. Physical examination reveals normal vital signs with the exception of an HR of 100. He has pale conjunctiva and mucous membranes, but otherwise normal cardiovascular and pulmonary examination results. There is no palpable lymphadenopathy. Abdominal examination results are benign, without evidence of hepatosplenomegaly. A CBC is obtained with the following results: WBC count 2600 (60% neutrophils, 30% lymphocytes, 6% monocytes, remainder eosinophils and basophils), hemoglobin 8.0 g/dL, hematocrit 26%, MCV 85 fL, platelet count 32,000/ $\mu$ L, reticulocytes 0.7%. Choose the test and result that are consistent with his diagnosis:

- A. Iron studies—low iron, increase total iron binding capacity, low ferritin
- B. Iron studies—low iron, low total iron binding capacity, high ferritin
- C. Bone marrow biopsy—hypocellularity of bone marrow with increased fat cells
- D. Bone marrow biopsy—hypercellularity of bone marrow with dysplasia of cell lines
- E. Bone marrow biopsy—hypercellularity of bone marrow with >30% blasts

21. A 63-year-old man presents to the clinic with generalized fatigue and a 10-pound weight loss over the past month. He denies having fevers, chills, weakness, or abdominal pain. Vital signs show an HR of 95, BP 123/78 mm Hg, and RR 16, with oxygen saturations of 98% on room air. Physical examination reveals pale mucous membranes without lesions and no scleral icterus. Cardiac examination shows a regular rhythm with mild tachycardia. Lungs are clear to auscultation bilaterally. Abdomen is soft, nontender, nondistended, and without hepatosplenomegaly. Results of initial laboratory studies are remarkable for hemoglobin of 10.1 g/dL, hematocrit 27%, MCV 71 fL, and RDW 16 (high). The peripheral smear is shown (Figure 21). Which of the following is the next most appropriate step in this patient's care?

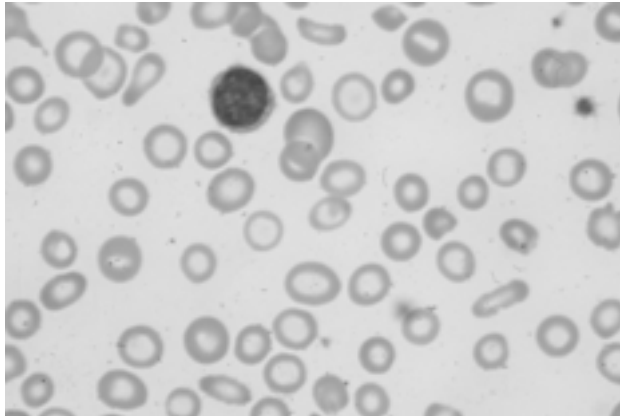


Figure 21 • Image Courtesy of Dr. Brenda Shinar, Banner Good Samaritan Medical Center, Phoenix, Arizona

- A. Start iron therapy
- B. Bone marrow biopsy
- C. Transfusion of packed RBCs
- D. Colonoscopy
- E. Hemoglobin electrophoresis

30 • Blueprints Q&A Step 3 Medicine

16. **D.** This patient likely has Graves' disease as a cause of her hyperthyroidism. RAIU is high in Graves' disease, indicating that the thyroid gland is avidly taking up iodine for the production of thyroid hormone. The RAIU is reported as a number, and it is the first test to order when evaluating a cause for hyperthyroidism. The RAIU helps to distinguish between high uptake causes of hyperthyroidism, such as Graves' disease and toxic multinodular goiter, and low uptake causes of hyperthyroidism, which include thyroiditis and factitious hyperthyroidism. The thyroid scintigraphy is reported as a picture. Thyroid scintigraphy is used to evaluate a pattern of uptake within the thyroid gland, and helps to define any nodules and whether they are "cold" (with less uptake) or "hot" (with more uptake). A person with Graves' disease alone as a cause of hyperthyroidism would have diffuse uptake on scintigraphy without evidence of nodules. Graves' disease is typically seen in women 20–40 years of age. Clinical presentation includes signs and symptoms of hyperthyroidism such as tachycardia, diarrhea, and tremulousness. Clinical findings include a diffuse, nontender goiter, ophthalmopathy (to include lid lag, lid retraction, proptosis, extraocular muscle weakness), and pretibial myxedema (but patients don't have to have all three or even two of the three components to have Graves' disease). Treatment is medical, with the drugs that decrease the production of thyroid hormones such as methimazole or PTU, or with radioactive iodine ablation or surgery. Patients treated with radioactive iodine ablation may eventually become hypothyroid and require thyroid supplementation.

A, B, C, E. These results would not be expected. See explanation for D.

17. **D.** The cosyntropin stimulation test is felt to be the most sensitive test in detecting adrenal insufficiency. Cortisol levels are checked at 0 hour, 30 minutes, and 60 minutes after a dose of ACTH (cosyntropin) is given to assess whether or not the adrenal glands are able to respond to ACTH stimulation. A peak value of less than 18–20 is considered inadequate and suggestive of primary adrenal insufficiency.

A. Random cortisol is not measured secondary to overlap with the normal values from the diurnal nature of the hormone. It is thought to be helpful in determining insufficiency in the critically ill because it should be maximal at all times in a high-stress environment, such as the intensive care unit.

B. An A.M. serum cortisol level is only considered useful if it is <3 (insufficient) or >18 (normal). Levels between 3 and 18 do not help to make a diagnosis.

C. A P.M. serum cortisol is not indicated because it would have little clinical value.

E. Checking serum glucose would be helpful to determine quickly if hypoglycemia were the cause of this patient's symptoms. However, his symptoms have been ongoing and his electrolyte abnormalities do not correlate with hypoglycemia.

18. E. This patient is exhibiting signs and symptoms of hypocalcemia. Clinical manifestations include perioral paresthesias, cramps, Chvostek's sign (tapping of facial nerve to illicit contraction of facial muscles), and Trousseau's sign (inflation of BP cuff eliciting carpal spasm). Other manifestations include irritability, depression, and seizures. Hypoparathyroidism can be isolated, secondary to hypomagnesemia, or can be evident status postthyroidectomy, in which case the parathyroids are accidentally removed or their blood supply is disrupted. Diagnosis is made by checking calcium, albumin, PTH, vitamin D, and other basic electrolytes. Treatment is with calcium replacement. Vitamin D replacement may also be required.
- A. Renal failure can cause hypocalcemia by way of decreased vitamin D production and decreased phosphorus excretion leading to increased calcium deposition in the soft tissue. Clinical manifestations include renal osteodystrophy that can consist of osteomalacia, osteitis fibrosa cystica, and osteoporosis.
- B. Pseudohypoparathyroidism is defined as PTH end organ resistance. This syndrome is also associated with skeletal abnormalities and retardation. Consequently, serum calcium levels are low, serum phosphate levels are elevated, and serum PTH levels are elevated.
- C. Vitamin D deficiency can be caused by decreased intake, inadequate production in the skin, or renal failure. In renal failure there is decreased hydroxylation of calcidiol to calcitriol, the end product of vitamin D. The function of vitamin D is to increase absorption of calcium and phosphate at the level of the intestine. In deficiency, there is reduced absorption of both calcium and phosphate, which leads to increased production of parathyroid hormone (secondary hyperparathyroidism) to improve serum calcium levels, which then lowers serum phosphate levels.
- D. Hypercalcemia of malignancy can be secondary to production of a PTH-rP or local osteoclastic activity at the level of bone. Calcium levels are elevated and phosphate levels can be variable depending on the etiology for the elevated calcium. Endogenous parathyroid hormone levels will be low in response to feedback inhibition from the elevated serum calcium.
19. C. Conn's syndrome is caused by an increase in aldosterone levels secondary to an adrenal adenoma. Symptoms of hyperaldosteronism include diastolic hypertension, headaches, muscle weakness (from hypokalemia), and polyuria. Laboratory findings include hypokalemia, hypernatremia, and metabolic alkalosis. Aldosterone levels are typically elevated secondary to the adenoma, and renin levels are low in response to a negative feedback loop. With those laboratory values, a CT or MRI should be ordered to determine the presence of an adenoma. If no adenoma is found, adrenal vein aldosterone sampling should be obtained. If there is no localization of aldosterone, the elevated aldosterone levels are thought to be secondary to hyperplasia.

32 • Blueprints Q&A Step 3 Medicine

A. Cushing's syndrome is defined as cortisol excess. Clinical signs of cortisol excess include central obesity, buffalo hump, easy fatigability, and easy bruising. Hypertension can also be present. Etiologies include a pituitary adenoma (Cushing's disease), adrenal tumor, or ectopic ACTH production from a cancer. This patient does not have any examination findings suggestive of cortisol excess. Renin and aldosterone levels are low in Cushing's syndrome.

B. Licorice ingestion is a nonaldosterone, exogenous cause of apparent mineralocorticoid excess. Renin and aldosterone levels will be low in this case.

D. Renal artery stenosis can result in secondary hyperaldosteronism, with an elevated renin and aldosterone level. This patient did not have an abdominal bruit on physical examination, and she had normal renal function. Patients with renal artery stenosis may have both of these findings, but the lack of these findings does not rule out the disease.

E. This patient gives no history to suggest renal hypoperfusion, which would lead to elevated renin and aldosterone levels in response to low flow states. This is also referred to as secondary hyperaldosteronism.

20. C. The clinical presentation of aplastic anemia can include fatigue and pallor due to anemia, mucosal bleeding due to thrombocytopenia, and recurrent infections due to neutropenia. Peripheral blood counts will reveal pancytopenia with a normocytic anemia and poor reticulocyte count. Bone marrow aspirate shows all cell lines to be hypocellular, with increase in bone marrow fat cells. The causes of aplastic anemia include chemicals such as benzene and arsenic; drugs such as chloramphenicol and carbonic anhydrase inhibitors; and viral infections including CMV, EBV, and parvovirus. In many cases of aplastic anemia, a cause is never established. Ultimate cure is a bone marrow transplant.

A. These iron studies are characteristic of iron deficiency anemia. This patient has a normocytic anemia, which is not consistent with that diagnosis. In addition, iron deficiency does not cause pancytopenia.

B. These iron studies are characteristic of anemia of chronic disease. Anemia of chronic disease does not cause pancytopenia.

D. This bone marrow aspirate is typical of a myelodysplastic syndrome. Myelodysplastic syndromes have a similar clinical presentation to aplastic anemia because both cause pancytopenia. However, myelodysplastic syndromes cause abnormal features of the cells that can be seen on the peripheral smear. Bone marrow aspirate will usually reveal hypercellularity with dysplasia of marrow precursor cells.

E. This bone marrow aspirate is typical for an acute leukemia. Acute leukemia can present with pancytopenia, but there are often blasts on peripheral smear.

21. **D.** This patient has a microcytic anemia, as evidenced by the low MCV and microcytosis on peripheral smear. There is also a variable RDW, which is revealed by a high value, indicating that this is not a thalassemia. Iron deficiency would be the most likely cause in this patient. It is not enough, however, to say the patient is iron deficient. A reason for the iron deficiency must be found. Gastrointestinal bleeding from a malignancy would be a possible and likely source. Colonoscopy should be performed to rule out this possibility prior to the initiation of iron therapy.

**A.** Iron supplementation will likely be needed, but a cause for the anemia should be sought. In addition, iron studies would be helpful to confirm the diagnosis prior to therapy.

**B.** Bone marrow biopsy is not indicated in this patient. Microcytic anemia should be evaluated with additional studies, including iron studies and hemoglobin electrophoresis. If iron deficiency is confirmed, a source for blood loss should be pursued. Bone marrow biopsy is usually not needed unless other diagnostic studies fail to produce a diagnosis.

**C.** This patient does not have any indications for transfusion therapy at this time. Indications to transfuse would include cardiac or pulmonary symptoms secondary to the anemia.

**E.** Hemoglobin electrophoresis can be used to evaluate for thalassemia, which is in the differential diagnosis for a microcytic anemia. However, it is a much less likely etiology, especially at this age of presentation, and the high RDW also points to iron deficiency as the diagnosis rather than thalassemia.

22. **C.** Erythropoietin level can be used to differentiate polycythemia vera from secondary polycythemia. In polycythemia vera, erythropoietin will be low, and in secondary polycythemia, erythropoietin will be elevated. RBC mass studies can also be useful in confirming the diagnosis of polycythemia vera. RBC mass will be elevated in polycythemia vera, but not in other myeloproliferative disorders. It cannot distinguish polycythemia vera from secondary erythrocytosis because RBC mass can be elevated in both.

**A.** Bone marrow biopsy will show hypercellularity with decreased iron stores. Bone marrow biopsy would be indicated if the serum erythropoietin is normal or an underlying malignancy is suspected.

**B.** Iron studies would not be the next test indicated in this patient. They may be obtained at some point in the workup and to monitor treatment. The treatment of polycythemia vera consists of phlebotomy once or twice weekly until the patient is iron deficient and hemoglobin is <14 g/dL.

**D.** LAP can be elevated on polycythemia vera. This is a nonspecific finding and is not useful for diagnostic purposes.

**E.** This patient has hyperviscosity from polycythemia. It is not a hypercoagulable state due to a defect in the coagulation pathway.