

Chapter

6

Neuro-Ophthalmology

Thomas E. Bournias, MD

Pupil

The pupil is the central portion of the iris plane. It both constricts (miosis) and dilates (mydriasis). Mydriasis is controlled by the dilator muscle, which is controlled primarily by sympathetic innervation. Miosis is controlled by the sphincter muscle, which primarily receives parasympathetic innervation.

■ Sympathetic Innervation

Sympathetic innervation (Figure 6-1) traverses a long path from the brain to the dilator muscle via the first-, second-, and third-order sympathetic innervation. The first-order neuron of the sympathetic chain begins in the ipsilateral posterolateral hypothalamus and traverses through the brain stem to synapse in the intermediolateral gray matter of the spinal cord at the level of C8, T1, and T2 (ciliospinal center of budge). The second-order neuron then exits the spinal cord and travels under the subclavian artery before passing over the pulmonary apex. It then passes through the stellate ganglion, without synapsing, to synapse in the superior cervical ganglion. Then, originating from the superior cervical ganglion, the third-order postganglionic neuron joins the internal carotid plexus, enters the cavernous sinus, and travels with the ophthalmic division of cranial nerve V (CN V) through the superior orbital fissure to the orbit and then to the dilator muscle.

■ Parasympathetic Innervation (Figure 6-2)

The sphincter muscle is composed of a circular band of smooth muscle fibers located near the pupillary margin. It has dual innervation, but it receives its primary innervation from parasympathetic fibers that originate in the nucleus of CN III. The sympathetic innervation to the sphincter muscle appears to serve an inhibitory role dilating the pupil in darkness. The parasympathetic pathway regulates the pupil size in different levels of lighting conditions.

60 • Blueprints Ophthalmology

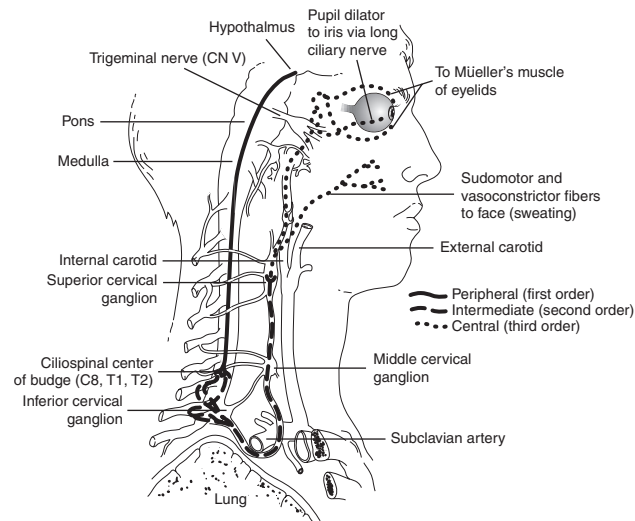


Figure 6-1 • The pathway of the first-, second-, and third-order neurons of the oculomotor pathway from the hypothalamus to the iris dilator muscle. Note the proximity of the apex of the lung to the sympathetic chain. Therefore, a Pancoast tumor may result in an ipsilateral Horner's syndrome.

Afferent Limb

The pupillary response to light originates in the rods and cones. The afferent pupillomotor fibers are transmitted via the optic nerve and hemidecussate at the chiasm. These fibers follow the visual sensory pathway through the optic tracts, exiting just before the lateral geniculate body (where the visual fibers synapse) to enter the brain stem by way of the brachium of the superior colliculus. The pupillomotor fibers synapse at the pretectal nuclei. The pretectal nuclei then project to both ipsilateral and contralateral Edinger-Westphal nuclei in the oculomotor nuclear complex in the midbrain.

Efferent Limb

The efferent pupillary fibers exit the Edinger-Westphal nucleus to join the third cranial nerve. Initially these fibers are located on the superior surface of the nerve. The third nerve rests on the edge of the tentorium cerebri on its way to the cavernous sinus, where the uncal portion of the undersurface of the temporal lobe rests. Here, a supratentorial space-occupying mass may compress the efferent fibers (uncal herniation) and result in a dilated and fixed pupil (Hutchinson's pupil). The third nerve also travels lateral to the posterior communicating artery here and is

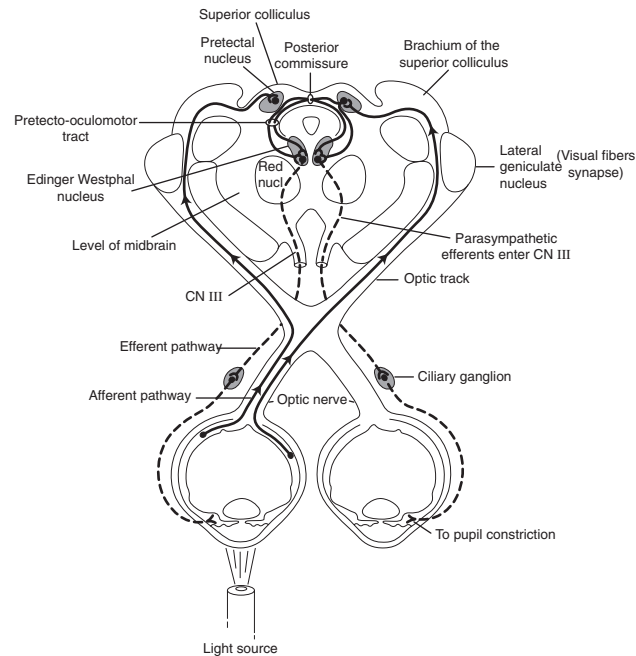


Figure 6-2 • The afferent and efferent parasympathetic pathway of the pupillary reaction to light. — afferent; - - - - efferent

also vulnerable to compression by an aneurysm, especially at the junction of the posterior communicating and the internal carotid arteries.

As the third nerve courses forward in the subarachnoid space and cavernous sinus, the pupillary fibers move down around the outside of the nerve to enter the inferior division of CN III. These efferent fibers then leave the inferior division of the third nerve and synapse at the ciliary ganglion. Parasympathetic postganglionic fibers are then distributed to the iris sphincter and ciliary body by way of the short ciliary nerves. Thus, light information presented to one eye is transmitted to both pupils equally.

An intact parasympathetic pathway results in a normal swinging flashlight test. The examiner projects light on the (for example) right eye and observes both pupils constrict. At this point, the examiner quickly swings the light to the left eye, which will remain constricted (except for some subsequent escape to an intermediate size). Consider an afferent pupillary defect (for example) in the left eye. After shining the light in the right

62 • Blueprints Ophthalmology

eye resulting in constriction of both pupils, the light is swung over quickly to the opposite side, and the previously constricted left pupil will show anywhere from initial constriction with greater escape to immediate dilation (RAPD or Marcus Gunn pupil).

Anisocoria

During distance fixation and with constant, moderate, ambient illumination the pupils tend to be of equal and constant size. There is a small bilateral, symmetric, nonrhythmic variation in size (usually less than 1 mm) termed hippus. When shifting to near fixation, equal miosis of the pupils is noted. Miosis is also noted when bright light is placed before one or both eyes during distance fixation. This "light" miosis is equal to or greater than "near" miosis. About 20% of the population has clearly discernible pupils of unequal size (termed anisocoria).

■ Etiology

- Abnormal pupil is constricted:
 - Unilateral use of miotic eye drops such as pilocarpine
 - Iritis: anterior chamber cell and flare (Plate 1) usually present; may have eye pain or redness
 - Horner's syndrome: mild ipsilateral ptosis usually present with a positive cocaine test
 - Argyll Robertson pupil: secondary to syphilis, typically bilateral but usually with a mild degree of anisocoria
 - Long-standing Adie's tonic pupil: initially pupil is dilated in Adie's, but may constrict over time. It reacts poorly to light but occasionally mildly to prolonged near effort (convergence).
- Abnormal pupil is dilated:
 - Trauma to iris sphincter: may see transillumination defects at pupillary border on slit lamp examination.
 - Adie's tonic pupil: pupil is dilated in initial Adie's.
 - Unilateral use of mydriatic drop such as atropine: will not constrict to pilocarpine during first week.
 - Third-nerve palsy: associated with extraocular muscle palsies and ipsilateral ptosis. Pupil will react to regular strength pilocarpine (1%), but not to weaker strengths.
- Physiologic anisocoria: size difference between the two pupils is usually 1 mm or less. The pupils react normally to light, and anisocoria is the same in both light and dark situations.

■ Diagnostic Evaluation (Table 6-1)

- Ask when anisocoria was first noted and if associated with signs or symptoms or decreased vision. Examine old photographs.

■ TABLE 6-1 Pharmacologic Testing for Anisocoria

Condition	Pupil Pathology	Drug	Normal Pupil	Pathologic Pupil
Horner's syndrome	Constricted	Cocaine 4%–10%	Dilates	Fails to dilate
- Preganglionic	Constricted	Paredrine 1%	Dilates	Dilates
- Postganglionic	Constricted	Paredrine 1%	Dilates	Fails to dilate
Argyll Robertson pupil	Constricted	N/A	—	—
Adie's pupil	Dilated	Pilocarpine 0.05%–0.1%	No reaction	Constricts
CN III palsy	Dilated	Pilocarpine 1%	Constricts	Constricts
Pharmacologic pupil (e.g., atropine)	Dilated	Pilocarpine 1%	Constricts	Fails to constrict

Ascertain if there has been a history of eye drops or ointment use, ocular trauma, or syphilis.

- Ocular examination: Observe the pupillary size and try to determine which is the abnormal pupil. Pupils are normally 4 to 5 mm in younger people (slightly smaller in older individuals). Compare pupil sizes in light and dark if it is not obvious which is the abnormal pupil. If anisocoria is greater in dark, the smaller pupil is abnormal. The larger pupil is abnormal if anisocoria is greater in light. Determine the pupillary reaction to light and, if abnormal, test for convergence. Some conditions, such as dorsal midbrain syndrome (Parinaud's syndrome), Adie's or Argyll Robertson pupil, are associated with light—near dissociation (where the near reflex is intact with an abnormal light reflex). There is no condition in which the light reflex is normal but the near (convergence) reflex is abnormal. Examine the lids for ptosis and ocular motility for evidence of paralysis. Perform a slit lamp examination and evaluate the pupillary margin (to rule out trauma) and anterior chamber (to rule out iritis).
- If the abnormal pupil is small and there is an unequivocal increase in anisocoria in dim illumination with associated ptosis, Horner's syndrome is diagnosed. If the diagnosis is not obvious, Horner's syndrome may be confirmed by a cocaine test (see Horner's Syndrome on next page).
- If the abnormal pupil is large and there is no evidence of a third-nerve palsy (extraocular motility restriction associated with ptosis), then both pupils are tested with one to two drops of diluted pilocarpine 0.125% (prepared by diluting one part of pilocarpine 1% with seven parts saline solution). An Adie's

64 • Blueprints Ophthalmology

pupil constricts significantly more than the normal pupil after 15 minutes (see Adie's Tonic Pupil on p. 67). In a chronic Adie's pupil, the pupil may not react to dilute pilocarpine 0.125%.

- If pharmacologic dilation is suspected (e.g., atropine) or the pupil did not respond to pilocarpine 0.125%, one drop of pilocarpine 1% may be placed in both eyes. A pharmacologically dilated pupil will constrict much less and more slowly than a normal pupil.

■ Treatment/Follow-up

- For further information on managing the above causes of anisocoria, see Horner's Syndrome, Argyll Robertson Pupil, Adie's Tonic Pupil, and Isolated Third-Nerve Palsy on p. 68.

Horner's Syndrome

A defect of the sympathetic pathway resulting in ipsilateral miosis, ptosis, enophthalmos (apparent recession of the globe into the orbit), and possibly anhidrosis (lack of sweating).

■ Etiology

- First-order neuron: stroke (vertebrobasilar artery insufficiency); tumor.
- Second-order neuron: tumor (e.g., lung tumor, metastasis, thyroid adenoma, neurofibroma). Suspect Pancoast's tumor if arm pain present. In children, suspect neuroblastoma, lymphoma, or metastasis.
- Third-order neuron: headache (Raeder's paratrigeminal neuralgia, migraine, cluster), internal carotid dissection (superior cervical ganglion lies near the bifurcation of the carotid artery), herpes zoster virus, Tolosa-Hunt syndrome, otitis media.
- Congenital: trauma (e.g., Erb's palsy from delivery).

■ History

- Pupil size disparity (smaller pupil is abnormal), ipsilateral droopy eyelid (ptosis)
- Often asymptomatic

■ Clinical Manifestations

- Anisocoria (greater in dim illumination because smaller pupil unable to dilate well due to defective sympathetic innervation)
- Ipsilateral drooping of upper eyelid (ptosis) and elevated lower eyelid (reverse ptosis)

- Ipsilateral anhidrosis (loss of sweating ability)
- Iris heterochromia (lighter iris color in affected eye) in congenital cases
- Increased accommodation in involved eye
- Intact light and near reaction

■ Differential Diagnosis

- See Anisocoria above.

■ Diagnostic Evaluation

- Determine the duration of Horner's syndrome (old photographs may help). New-onset Horner's syndrome requires more extensive workup (an old Horner's syndrome is more likely to be benign). Ask about headache, arm pain, or previous stroke. Determine if there was a history of damage to the sympathetic chain such as previous surgery including thoracic, cardiac, thyroid, or neck or any head or neck trauma. Determine if there is a history of stroke, arm pain, or headache.
- Physical examination: Check for palpable supraclavicular nodes, thyroid enlargement, or a neck mass.
- Cocaine test if diagnosis is uncertain: place one drop of cocaine 4% to 10% in both eyes and repeat in 1 minute. After 15 minutes check pupillary size; if no change is present, place an additional drop in both eyes and reevaluate in another 15 minutes. A Horner's pupil will dilate less than the normal pupil (cocaine blocks reuptake of norepinephrine).
- Paredrine test (hydroxyamphetamine 1%): may be used when Horner's syndrome is confirmed to distinguish a first- and second-order (preganglionic) neuron disorder from a third-order (postganglionic) neuron disorder. Wait at least 24 hours if cocaine test was performed. Place one drop of hydroxyamphetamine 1% into both eyes, and repeat 1 minute later. If the Horner's pupil does not dilate to an equivalent amount as the normal eye, a third-order neuron lesion is present. (Paredrine releases norepinephrine from the presynaptic terminal.)
- Some of the following tests may be performed if a new-onset Horner's is discovered, a tumor is suspected, or a preganglionic lesion is present.
 - Chest x-ray or CT of lung with special attention to the apex
 - CT (axial and coronal) or MRI of brain and neck
 - CBC with differential
 - Lymph node biopsy in presence of lymphadenopathy
 - Carotid angiogram, magnetic resonance angiography (MRA), or carotid Doppler ultrasound in cases of neck pain where carotid dissection is suspected

66 • Blueprints Ophthalmology**■ Treatment**

- Management of underlying disorder if possible
- Ptosis surgery if necessary

■ Follow-up

- As soon as possible in acute situation to rule out a life-threatening cause
- As soon as possible in a child with ptosis to treat for possible amblyopia (see amblyopia treatment, p. 57)
- Chronic Horner's syndrome is evaluated routinely.

Argyll Robertson Pupil

A rare syndrome that occurs in some patients with tertiary syphilis involving the central nervous system (CNS). Over time both pupils become small (less than 2 mm) and irregular. This is one of the rare situations where a very miotic pupil may react briskly.

■ Etiology

- Tertiary syphilis [positive fluorescent treponemal antibody, absorbed (FTA-ABS)]

■ History

- Usually asymptomatic

■ Clinical Manifestations

- Small, irregular pupils that react poorly to light but normally to convergence (light-near dissociation). Pupils dilate poorly.
- Initially unilateral, but later becomes bilateral. Often asymmetric.
- Normal vision.

■ Differential Diagnosis

- See Anisocoria above.

■ Diagnostic Evaluation

- Test pupillary reaction to light and convergence (determine if light-near dissociation exists).
- Look for evidence of interstitial keratitis on slit lamp examination.
- Look for uveitis, chorioretinitis, and papillitis on dilated fundus examination.
- Check FTA-ABS and rapid plasma reagin (RPR) or Venereal Disease Research Laboratory (VDRL) results.
- Possible lumbar puncture if positive diagnosis of syphilis.

■ Treatment

- See Chapter 11, Acquired Syphilis, p. 157
- The decision to treat is based on the presence of active disease and if the patient had previously been treated appropriately.

■ Follow-up

- Not emergent.
- Workup patient in a few days to 2 weeks to determine if syphilitic activity is present.

Adie's Tonic Pupil

Dilated pupil that appears to be benign in nature. The pupil may get smaller with time. The cause is unknown, but the ciliary ganglion has been found to have a dramatic reduction in ganglion cells.

■ Etiology

- Idiopathic
- Orbital trauma
- Infection with herpes zoster, varicella, syphilis
- May be bilateral in diabetes, chronic alcoholism, familial dysautonomia (Riley-Day syndrome)

■ Epidemiology

- 70% women
- 80% unilateral, second pupil may become involved later.

■ History

- Anisocoria, larger pupil dilated
- Blurred vision
- May be asymptomatic

■ Clinical Manifestations

- Irregularly dilated pupil.
- Affected pupil demonstrates minimal to no reaction to light and slow constriction to convergence with slow redilation afterwards (light-near dissociation).
- Affected pupil is supersensitive (constricts) to weak cholinergics (e.g., one drop of pilocarpine 0.125%).
- Normal dilation with mydriatics.
- Chronically, the involved pupil may become smaller than the normal pupil.
- Adie's syndrome: when associated with absent deep tendon reflexes (ankles and knees).

68 • Blueprints Ophthalmology**■ Differential Diagnosis**

See Anisocoria above.

■ Diagnostic Evaluation

- See diagnostic evaluation for anisocoria for general workup.
- Examine the suspicious pupil with bright light at the slit lamp to confirm a pupil that reacts slowly and irregularly.
- Measure the size of each pupil as the patient fixates at distance. Check for a supersensitive pupil by placing one drop of pilocarpine 0.125% in both eyes.
- An Adie's tonic pupil constricts significantly more than the normal contralateral pupil. Occasionally, the supersensitivity may not be present immediately after developing an Adie's pupil; therefore, supersensitivity testing may be repeated 2 to 3 weeks later.
- Dilute pilocarpine may yield a positive result in Argyll Robertson pupil and familial dysautonomia.

Note: Parinaud's syndrome: may cause bilateral middilated pupils that react poorly to light but constrict normally during convergence (unlike Adie's), upgaze paralysis, convergence-retraction nystagmus, and lid retraction (Collier's sign). With these signs, perform an MRI to rule out pinealoma or other mid-brain abnormality.

■ Treatment

- May treat with pilocarpine 0.125% two to four times per day to constrict the pupil for cosmetic purposes or to improve accommodation.

■ Follow-up

- Routine follow-up if diagnosis is certain
- If the patient is younger than 1 year, and Adie's pupil or supersensitivity is present, refer the patient to a pediatric neurologist to rule out familial dysautonomia.

Isolated Third-Nerve Palsy

Defect in CN III resulting in motility impairment (external ophthalmoplegia) and possibly impairment of pupillary reaction (internal ophthalmoplegia). Pupillary involvement may occur secondary to aneurysm, tumor, ischemia, trauma, or giant cell arteritis (GCA). The pupil is controlled by the efferent parasympathetics (miosis) that run in the inferior division of CN III, which innervates the medial and inferior recti.

■ History

- Double vision that disappears when one eye is occluded
- Ptosis (droopy eye lid) with/without pain

■ Clinical Manifestations

- Limitation of ocular movements, especially superior, inferior, and nasal.
- Ptosis may be present.
- Pupil may be dilated with diminished reactivity to light.
- Eye may appear to be looking down and/or out.
- May see aberrant regeneration (elevation of the upper lid and possibly constriction of the pupil with superior, medial, or inferior gaze). If this sign occurs spontaneously (primary), it may indicate a cavernous sinus aneurysm or tumor.

■ Differential Diagnosis

- GCA: pupil may or may not be involved but may develop ocular motility dysfunction.
- Myasthenia gravis: no pupil involvement; fluctuation in ptosis and diplopia; ptosis worsens with sustained gaze; positive result on edrophonium chloride (e.g., Tensilon) test.
- Thyroid eye disease: have lid retraction and not ptosis; may have ocular motility disorders. May have proptosis. Also may have injection over recti muscle insertions and resistance on forced-duction testing.
- Orbital inflammatory pseudotumor: idiopathic orbital inflammation with pain on eye movement. Patients may have double vision with restriction of ocular motility. May have proptosis and/or decreased vision.
- Internuclear ophthalmoplegia: unilateral or bilateral adduction deficit with horizontal nystagmus in the opposite abducting eye. A lesion of the medial longitudinal fasciculus. Ptosis is not present. Seen in multiple sclerosis.
- Chronic progressive ophthalmoplegia: pupil is spared. Patients demonstrate progressive bilateral ptosis and ocular motility deficits. May or may not have diplopia.
- Parinaud's syndrome: dorsal midbrain lesion with bilateral inability to look up and pupils demonstrating normal reaction to accommodation but abnormal reaction to light (light-near dissociation). There is no ptosis, and lid retraction and convergence-retraction nystagmus may be present.

■ Diagnostic Evaluation

- Ascertain if there is a history of trauma or medical illness such as diabetes, hypertension, or cancer.

70 • Blueprints Ophthalmology

- Complete ocular examination with careful attention to pupil examination. Check for ptosis and signs of aberrant regeneration.
- Check exophthalmometer for presence of proptosis.
- Check for signs of other cranial nerve abnormalities.
- Order immediate brain CT scan or MRI to rule out a mass/aneurysm if:
 - There is pupillary involvement.
 - The pupil is not involved but:
 - Other cranial nerves are involved.
 - The patient is younger than 50 years without a history of diabetes or hypertension.
 - The third-nerve palsy has been present for more than 3 months without improvement.
 - There is spontaneous aberrant regeneration.
- Check fasting blood sugar/Hb A_{1c} and blood pressure if suspicious of ischemic disease.
- Check ESR if suspicious of GCA.
- Check edrophonium chloride (e.g., Tensilon) test if suspicious of myasthenia gravis (and pupil is not involved).

■ Treatment

- Manage underlying abnormality or vascular disease if present.
- If double vision is present, may patch involved eye (patching not generally done in children under 10 years of age for fear of amblyopia).

■ Follow-up

- Pupil-involved third-nerve palsy: workup as described above and immediate hospitalization.
- Pupil-spared third-nerve palsy: workup as described and, if new, observe for 1 week. Recheck every 6 weeks.
- Normal function should return in about 3 months.
- If function is not restored by 3 months or additional neurologic abnormality results, an MRI of the brain is indicated.

Papilledema

Bilateral optic disc swelling caused by increased intracranial pressure

■ Etiology

- Intracranial tumors (primary and metastatic)
- Pseudotumor cerebri (benign intracranial hypertension): usually occurs in women, often overweight. CT scan or MRI of the brain is normal, but may have exotropia secondary to CN VI palsy.

- Aqueductal stenosis: may produce hydrocephalus
- Subdural and epidural hematoma: from trauma, especially if on anticoagulation therapy
- Subarachnoid hemorrhage: causes severe headache. May develop preretinal and vitreous hemorrhage (Terson's syndrome)
- Brain abscess: especially if HIV positive; may cause fever
- Arteriovenous malformation (AVM)

■ History

- Transient loss of vision (lasting seconds) usually bilateral and caused by changes in posture
- Decrease in visual acuity acutely (if associated with macular edema)
- Severe decrease of visual acuity and visual field defects with chronic papilledema (secondary to optic nerve pallor)
- Double vision (if CN VI palsy present)
- Headache, nausea, vomiting

■ Clinical Manifestations

- Early: bilateral, swollen, hyperemic optic nerves with blurring of the disc margin (Plate 7)
 - Normal pupil response to light and normal color vision.
 - Papillary and peripapillary retinal hemorrhages (often flame shaped) and cotton-wool spots may be present.
 - Dilated, tortuous retinal veins.
 - Absent venous pulsation at optic disc (absent in 20% of normal persons).
 - Visual field testing may reveal an enlarged blind spot.
- Chronic: optic atrophy (Plate 5)
 - Decreased central visual acuity and color vision
 - Esotropia (secondary to unilateral or bilateral sixth-nerve palsy)
 - Collateral vessels on the optic disk
 - Resolution of peripapillary hemorrhages and cotton-wool spots
 - Narrowing of peripapillary retinal vessels with peripapillary gliosis
 - Visual field defects

■ Differential Diagnosis (causes of bilateral disc edema)

- Pseudopapilledema: e.g., optic nerve drusen. Disc margins are sharp and vessels are not obscured. The neuroretinal rim is not hyperemic and the surrounding nerve fiber layer is normal.
- Malignant hypertensive retinopathy (Plate 8): fundus examination reveals bilateral narrowed arterioles with arteriovenous

72 • Blueprints Ophthalmology

nicking. There are associated scattered hemorrhages with cotton-wool spots. Blood pressure is extremely high.

- Ischemic optic neuropathy (ION): sudden, severe, unilateral loss in vision that may soon involve the second eye (e.g., GCA and nonarteritic ION). Optic nerve swelling is pale and not hyperemic.
- Diabetic papillitis: usually bilateral disc edema possibly associated with diabetic retinopathy changes. Typically seen in young persons with type I diabetes.
- Infiltration of the optic nerve: usually unilateral but can be bilateral. Seen in sarcoidosis, leukemia, tuberculosis, metastasis, and other inflammatory diseases. If seen in a leukemia patient, immediate radiation therapy is indicated to preserve vision.
- Graves' ophthalmopathy: other signs of thyroid dysfunction would be evident (see Chapter 11, Thyroid disease, p. 150).
- Leber's optic neuropathy: begins unilaterally but rapidly becomes bilateral. There is a rapid, progressive loss of vision with disc swelling associated with peripapillary telangiectasia that later becomes atrophic. Occurs primarily in men in their second to third decade of life. Family history may or may not be present.

■ Diagnostic Evaluation

- Determine if there is a history of systemic disease, especially hypertension, thyroid disease, and diabetes.
- Ophthalmic examination should include pupillary and color vision testing. Dilated fundus examination should carefully observe the vitreous for signs of inflammation, and the optic nerve appearance should be carefully noted.
- Check blood pressure.
- Immediate CT (axial and coronal) or MRI of the brain (and possibly the orbit) in all cases of bilateral disc edema (papilledema) to rule out a space occupying lesion.
- Lumbar puncture if CT/MRI result is unremarkable.

■ Treatment

- Address underlying cause.

■ Follow-up

- Initially weekly; later less frequently.
- Follow visual acuity and visual field carefully.

Optic Neuritis

An inflammation of the optic nerve of unknown cause associated with rapid deterioration of vision followed by a steady recovery.

■ Etiology

- Idiopathic
- Multiple sclerosis
- Viral infections, such as mononucleosis, herpes zoster, encephalitis, measles, mumps, chickenpox
- Granulomatous inflammations, such as syphilis, sarcoidosis, and tuberculosis
- Intraocular inflammations

■ Epidemiology

- Usually occurs between ages 20 to 45 years
- Occurs in nearly 100% of patients with long-standing multiple sclerosis

■ History

- Visual loss usually deteriorating over days until about 1 week (visual loss may deteriorate rarely over hours and may be subtle to extreme).
- Usually unilateral, 90% with orbital pain especially with eye movement.
- Loss of color vision
- Uhthoff's symptom (increased symptoms with exercise or increased body temperature)
- Pulfrich's phenomenon (altered perception of moving objects)
- May have had a preceding viral syndrome (upper respiratory, gastrointestinal, or other flulike symptoms).
- Other: focal neurologic symptoms (e.g., numbness or tingling in extremities).

■ Clinical Manifestations

- Decreased visual acuity with a relative afferent pupillary defect (RAPD).
- Decreased color vision and visual field defects.
- Swollen optic nerve [may have peripapillary flame-shaped hemorrhages (Plate 9)].
- Disc may appear normal in retrobulbar optic neuritis; usually seen in adults.
- Rarely, may see vitreous cells.

■ Differential Diagnosis

- Ischemic optic neuropathy (ION): sudden, painless loss of vision. Optic nerve swelling primarily pale. Visual field defects are usually inferior altitudinal. Usually no pain with ocular motility.
- Acute papilledema: disc edema is bilateral. Visual acuity and color vision are usually normal unless macular edema is present. Spontaneous venous pulsations absent. No pain with ocular

74 • Blueprints Ophthalmology

motility. No vitreous cells. Visual field testing often reveals enlarged blind spot.

- Severe systemic hypertension: bilateral disc edema with flame-shaped hemorrhages and cotton-wool spots. Blood pressure is elevated (Plate 8).
- Intracranial mass compressing the afferent visual pathway: Disc appears normal but there is loss of color vision with a positive RAPD. Neuroimaging of the brain reveals a mass.
- Orbital tumor compressing the optic nerve: optic nerve swelling (if present) would be unilateral. Proptosis or restriction of extraocular motility may be evident. Vitreous cells are not present.
- Toxic or metabolic optic neuropathy: progressive painless bilateral loss of vision secondary to malnutrition (vitamin B₁₂), alcohol, tobacco, pernicious anemia, or numerous toxins (e.g., heavy metals, ethambutol, isoniazid, chloroquine, digitalis). Optic discs appear pale, especially temporally.
- Leber's optic neuropathy: See discussion under differential diagnosis of papilledema above.

■ Diagnostic Evaluation

- Determine whether acute or gradual loss of vision is present. Inquire if there have been previous episodes or pain with ocular motility. Ask the patient's age.
- Perform ophthalmic examination including pupillary and color vision assessment. Perform dilated fundus examination to look for vitreous cells and swelling or hemorrhage in the retina or optic nerve.
- Visual field testing.
- Check blood pressure and perform neurologic examination looking for abnormalities.
- Consider blood tests such as CBC, ESR, RPR, FTA-ABS, and antinuclear antibody (ANA) if presentation is unusual such as no pain on eye movement or patient's age range is atypical.
- MRI with gadolinium of the brain and orbits for unusual cases and first episodes.

■ Treatment

- Observation if patient has a history of optic neuritis or MS.
- Intravenous steroids (e.g., methylprednisolone 250 mg IV every six hours) for 3 days followed by oral prednisone (e.g., 40–100 mg PO every day) if the patient is seen acutely and there is no previous history of optic neuritis or MS, and subsequent MRI of brain reveals at least one area of demyelination.
- Consider intravenous steroids to accelerate visual recovery in some patients.

- No oral prednisone as a primary treatment because this has been associated with an increased risk of recurrences.

■ Follow-up

- Every 1 to 3 months.
- Follow more closely and check IOP if on steroids.
- Neurology consult if CNS demyelination is seen on MRI.

Arteritic Ischemic Optic Neuropathy (Giant Cell Arteritis)

Ischemia to the optic nerve head as a result of giant cell arteritis (GCA). GCA is an autoimmune disease that affects arteries with an internal elastic lamina. GCA can result in myocardial infarction, stroke, and ocular complications.

■ Epidemiology

- Increased incidence with older age (more than 55 years)
- Usually occurs in whites (rare in blacks)

■ History

- Sudden, painless loss of vision without progression.
- Initially unilateral, but may rapidly become bilateral.
- May experience headache, jaw claudication (pain with chewing), or scalp tenderness.
- May have proximal muscle and joint pain (e.g., polymyalgia rheumatica), anorexia, weight loss, fever.
- Usually occurs in patients older than 50 years.

■ Clinical Manifestations

- Devastating loss of vision with an RAPD.
- Fundoscopic examination reveals pale, swollen optic nerve (often associated with flame-shaped hemorrhages). As optic nerve edema resolves, optic atrophy ensues.
- Central retinal artery occlusion may occur.
- Visual field defects may occur revealing altitudinal or central visual loss.
- Palpated temporal artery may be tender and nonpulsatile.
- May acquire cranial nerve palsies (primarily CN VI).
- ESR may be very elevated.

■ Differential Diagnosis

- Nonarteritic ION. Usually patient is younger with less severe loss of vision. Usually do not have above symptoms of GCA; ESR is usually normal.

76 • Blueprints Ophthalmology

- Inflammatory optic neuritis (papillitis): Usually visual loss is less severe and less sudden. Pain is usually associated with eye movements. No symptoms of GCA. Associated with more hemorrhage of the optic disc. No vitreous cells. Usually younger persons affected.
- Central retinal vein occlusion (CRVO): severe loss of vision with associated RAPD. Optic nerve swelling is present as well as diffuse retinal hemorrhages (Blood and Thunder) extending to periphery.
- Compressive optic nerve tumor: slow progressive loss of visual acuity. No symptoms of GCA. Optic nerve slowly becomes pale.
- Central retinal artery occlusion (CRAO): sudden, severe, painless loss of vision associated with an RAPD. However, optic disc is not swollen. Retinal edema may be observed with a classic cherry-red spot in the fovea.

■ Diagnostic Evaluation

- Try to elicit above symptoms and ascertain the age of the patient, as older patients have a higher risk of developing GCA.
- Ocular examination: color vision testing and pupillary assessment to rule out RAPD. Dilated fundus examination for optic nerve evaluation and to rule out retinal causes of severe loss of vision.
- Stat ESR (Westergren). Upper limit of normal: men = $\text{age}/2$; women = $(\text{age} + 10)/2$.
- Temporal artery biopsy if symptoms or signs suspicious of GCA or ESR elevated.
- ESR may be normal (perform biopsy within 1 to 2 weeks of instituting steroid therapy).
- If biopsy is negative (at least a 2-cm section), a contralateral biopsy may be taken if a high clinical suspicion exists (some physicians prefer initial bilateral temporal artery biopsies because of skip areas and possible false negatives).

■ Treatment

- Once suspected, start intravenous steroids (e.g., methylprednisolone 250 mg IV every 6 hours for 12 doses) in the hospital. Switch to oral prednisone (e.g., 80–100 mg PO every day) after 12 doses.
- An oral antiulcer medication (e.g., ranitidine 150 mg PO twice per day) is often given concurrently with the steroid.
- Obtain temporal artery biopsy, often while the patient is still in the hospital.

- If biopsy is positive, continue oral prednisone. Steroid may be slowly tapered over 3 to 12 months as ESR declines or symptoms improve. Patient's internist should manage complications of steroid therapy, but an ophthalmologist should adjust and taper the steroid level based on clinical findings and the ESR.
- Discontinue steroids after obtaining negative biopsies on adequate specimens.

■ Follow-up

- Evaluate and treat emergently if GCA suspected.
- After diagnosis confirmed by biopsy, initial steroid dosage is continued for 4 weeks until symptoms improve or ESR decreases.
- Taper steroid very slowly over 3 to 12 months.
- Decrease dosage monthly as symptoms reverse or ESR decreases.
- Check ESR monthly with each dosage change.
 - If symptoms return or ESR elevates, steroid dose must be increased.
 - Use minimal steroid dose to achieve desired result.

Nonarteritic Ischemic Optic Neuropathy

Ischemia of the optic nerve head due to compromise of the posterior ciliary vessels.

■ History

- Sudden moderate, nonprogressive loss of vision; painless
- Initially unilateral but may become bilateral

■ Clinical Manifestations

- RAPD and decreased color vision
- Optic disc with flame-shaped hemorrhages and often pale swelling involving only one sector
- Optic atrophy after edema resolves (Plate 5)
- Altitudinal or central visual field defect
- Normal ESR

■ Risk Factors

- Often associated with hypertension, diabetes, arteriosclerosis
- Patients usually 40 to 60 years old

■ Differential Diagnosis

- See Arteritic Ischemic Optic Neuropathy above.

78 • Blueprints Ophthalmology

■ **Diagnostic Evaluation**

- Ask about above symptoms of GCA. Determining age is very important (usually occurs in 40- to 60-year-olds).
- Ocular examination: evaluate pupils for RAPD and check color vision with color plates. Dilated fundus examination to evaluate the optic nerve and to rule out retinal causes of severe visual loss.

■ **Treatment/Follow-up**

- Observation
- Follow-up in 1 month

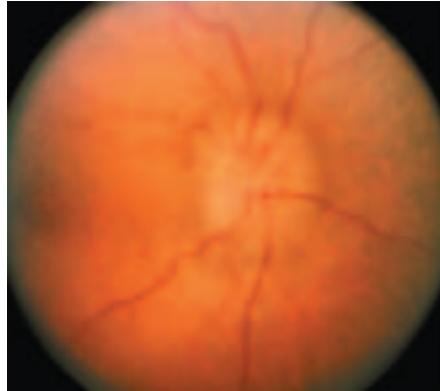

Plate 7 • Disc edema secondary to increased intracranial hypertension demonstrates an elevated disc with a hyperemic neuro-retinal rim and dilated capillaries.

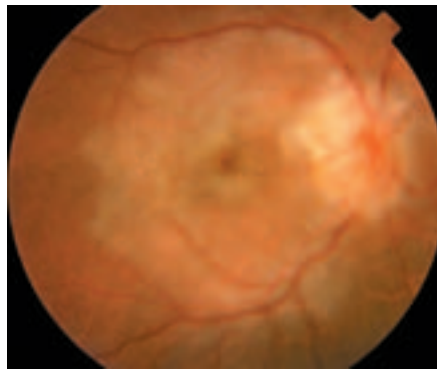

Plate 8 • Disc edema secondary to uncontrolled hypertension. Note the blurred disc margins and hemorrhages and evidence of hypertensive retinopathy. Leaking lipids travel in Henle's layer toward the macula forming a "macular star."

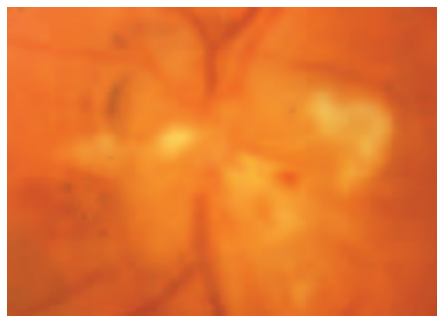


Plate 9 • Disc edema secondary to malignant hypertension, optic neuritis, or ischemic optic neuropathy demonstrates hemorrhagic disc swelling with exudates and cotton-wool spots surrounding the optic nerve. The disc margin is very blurred.