

1 Cardiac Symptoms and Physical Signs

1.1 Common Cardiac Symptoms

Angina

Typical angina presents as a chest tightness or heaviness brought on by effort and relieved by rest. The sensation starts in the retrosternal region and radiates across the chest. Frequently it is associated with a leaden feeling in the arms. Occasionally it may present in more unusual sites, e.g. pain in the jaw or teeth on effort, without pain in the chest. It may be confused with oesophageal pain, or may present as epigastric or even hypochondrial pain. The most important feature is its relationship to effort. Unilateral chest pain (submammary) is not usually cardiac pain, which is generally symmetrical in distribution.

Angina is typically exacerbated by heavy meals, cold weather (just breathing in cold air is enough) and emotional disturbances. Arguments with colleagues or family and watching exciting television are typical precipitating factors.

Stable Angina

This is angina induced by effort and relieved by rest. It does not increase in frequency or severity, and is predictable in nature. It is associated with ST-segment depression on ECG.

Decubitus Angina

This is angina induced by lying down at night or during sleep. It may be caused by an increase in LVEDV (and hence wall stress) on lying flat, associated with dreaming or getting between cold sheets. Coronary spasm may occur in REM sleep. It may respond to a diuretic, calcium antagonist or nitrate taken in the evening.

Unstable (Crescendo) Angina

This is angina of increasing frequency and severity. Not only is it induced by effort but it comes on unpredictably at rest. It may progress to myocardial infarction.

Variant Angina (Prinzmetal's Angina)

This is angina occurring unpredictably at rest associated with transient ST-segment elevation on the ECG. It is not common, and is associated with coronary spasm often in the presence of additional arteriosclerotic lesions.

Other Types of Retrosternal Pain

- Pericardial pain: described in Section 10.1. It is usually retrosternal or epigastric, lasts much longer than angina and is often stabbing in quality. It is related to respiration and posture (relieved by sitting forward). Diaphragmatic pericardial pain may be referred to the left shoulder.
- Aortic pain (Section 14.2): acute dissection produces a sudden tearing intense pain, retrosternally radiating to the back. Its radiation depends on the vessels involved. Aortic aneurysms produce chronic pain especially if rib or vertebral column erosion occurs.
- Non-cardiac pain: may be oesophageal or mediastinal with similar distribution to cardiac pain but not provoked by effort. Oesophageal pain may be provoked by ergonovine, making it a useless test for coronary spasm. Oesophageal spasm causes intense central chest pain, which may be relieved by drinking cold water. Chest wall pain is usually unilateral. Stomach and gallbladder pain may be epigastric and lower sternal, and be confused with cardiac pain.

Dyspnoea

This is an abnormal sensation of breathlessness on effort or at rest. With increasing disability, orthopnoea and PND occur. Pulmonary oedema is not the only cause of waking breathless at night: it may occur in non-cardiac asthma. A dry nocturnal cough is often a sign of impending PND. With acute pulmonary oedema, pink frothy sputum and streaky haemoptysis occur. With poor LV function Cheyne–Stokes ventilation makes the patient feel dyspnoeic in the fast cycle phase.

Effort tolerance is graded by New York Heart Association (NYHA) criteria as follows.

Class I

Patients with cardiac disease but no resulting limitations of physical activity. Ordinary physical activity does not cause undue fatigue, palpitation or angina.

Class II

Patients with cardiac disease resulting in slight limitation of physical activity. They are comfortable at rest. Ordinary physical activity results in fatigue,

palpitation, dyspnoea or angina (e.g. walking up two flights of stairs, carrying shopping basket, making beds). By limiting physical activity, patients can still lead a normal social life.

Class III

Patients with cardiac disease resulting in marked limitation of physical activity. They are comfortable at rest, but even mild physical activity causes fatigue, palpitation, dyspnoea or angina (e.g. walking slowly on the flat). Patients cannot do any shopping or housework.

Class IV

Patients with cardiac disease who are unable to do any physical activity without symptoms. Angina or heart failure may be present at rest. They are virtually confined to bed or a chair and are totally incapacitated.

Syncope

Syncope may be caused by several conditions:

- *Vasovagal* (vasomotor, simple faint): the most common cause. Sudden dilatation of venous capacitance vessels associated with vagally induced bradycardia. Induced by pain, fear and emotion.
- *Postural hypotension*: this is usually drug-induced (by vasodilators). May occur in true salt depletion (by diuretics) or hypovolaemia.
- *Carotid sinus syncope*: a rare condition with hypersensitive carotid sinus stimulation (e.g. by tight collars) inducing severe bradycardia (see Section 7.6).
- *Cardiac dysrhythmias*: most common causes are sinus arrest, complete AV block and ventricular tachycardia; 24-hour ECG monitoring is necessary.
- *Obstructing lesions*: aortic or pulmonary stenosis, left atrial myxoma or ball-valve thrombus, HCM, massive pulmonary embolism. Effort syncope is commonly secondary to aortic valve or subvalve stenosis in adults and Fallot's tetralogy in children.
- *Cerebral causes*: sudden hypoxia, transient cerebral arterial obstruction, spasm or embolism.
- *Cough syncope*: this may result from temporarily obstructed cerebral venous return. Profound bradycardia can be the cause mediated via the vagus.
- *Micturition syncope*: this often occurs at night, and sometimes in men with prostatic symptoms. It may result partly from vagal overactivity and partly from postural hypotension.

The most common differential diagnosis needed is sudden syncope in an adult with no apparent cause. Stokes–Adams attacks and epilepsy are the main contenders (Table 1.1).

A prolonged Stokes–Adams episode may produce an epileptiform attack from cerebral hypoxia. It is not always possible to distinguish the two clinically.

Table 1.1 Differentiation of Stokes-Adams attacks from epilepsy

| <i>Stokes-Adams attacks</i> | <i>Epilepsy</i> |
|--|---------------------------------|
| No aura or warning | Aura often present |
| Transient unconsciousness (often only a few seconds) | More prolonged unconsciousness |
| Very pale during attack | Tonic-clonic phases |
| Rapid recovery | Prolonged recovery; very drowsy |
| Hot flush on recovery | Absent |

Cyanosis

Central cyanosis should be detectable when arterial saturation is <85% and when there is >5g reduced haemoglobin present. It is more difficult to detect if the patient is also anaemic. Cardiac cyanosis may be caused by poor pulmonary blood flow (e.g. pulmonary atresia), right-to-left shunting (e.g. Fallot's tetralogy) or common mixing situations with high pulmonary blood flow (e.g. TAPVD).

Cyanosis from pulmonary causes should be improved by increasing the F_{iO_2} . The child breathes 100% O_2 for 5 min. The arterial P_{O_2} should increase to >21 kPa (160 mmHg) if the cyanosis is pulmonary in origin. Cyanosis caused by right-to-left shunting should change little in response to 100% O_2 and certainly <21 kPa (160 mmHg).

Peripheral cyanosis in the absence of central cyanosis may be the result of peripheral vasoconstriction, poor cardiac output or peripheral sludging of red cells (e.g. polycythaemia).

Embolism

Both systemic and pulmonary embolisms are common in cardiac disease. Predisposing factors in cardiology are shown in Table 1.2.

Table 1.2 Predisposing factors to pulmonary and systemic emboli

| <i>Pulmonary emboli</i> | <i>Systemic emboli</i> | <i>Either or both</i> |
|---------------------------------------|--|----------------------------|
| Prolonged bed rest | Atrial fibrillation | Myocardial infarction |
| High venous pressure | Aortic stenosis (calcium) | Dilated cardiomyopathy |
| Central lines | Mitral stenosis AF > SR | CCF |
| Femoral vein catheterization | Infective endocarditis | Polycythaemia |
| Pelvic disease (tumour, inflammation) | LA myxoma | Diuretics |
| Tricuspid endocarditis | HCM | Procoagulable state |
| Deep vein thrombosis | Prosthetic aortic or mitral valves | Eosinophilic heart disease |
| | Floppy mitral valve | |
| | Closed mitral valvotomy or valvuloplasty | |
| | Mitral annulus calcification | |

Oedema

Factors important in cardiac disease are: elevated venous pressure (CCF pericardial constriction), increased extracellular volume (salt and water retention), secondary hyperaldosteronism, hypoalbuminaemia (liver congestion, anorexia and poor diet), venous disease and secondary renal failure.

Acute oedema and ascites may develop in pericardial constriction. Protein-losing enteropathy can occur, with a prolonged high venous pressure exacerbating the oedema.

Other Symptoms

These are discussed in the relevant chapter:

- Palpitation: principles of paroxysmal tachycardia diagnosis – see Section 8.1
- Haemoptysis: mitral stenosis – see Section 3.2
- Cyanotic attack: catheter complications – see Section 16.3.

1.2 Physical Examination

Hands

It is important to check for the following:

- Dilated hand veins with CO₂ retention
- Temperature (?cool periphery with poor flows, hyperdynamic circulation)
- Peripheral cyanosis
- Clubbing: cyanotic congenital heart disease, infective endocarditis
- Capillary pulsation, aortic regurgitation, PDA
- Osler's nodes, Janeway's lesions, splinter haemorrhages (Figure 1.1), infective endocarditis
- Nail-fold telangiectases: collagen vascular disease
- Arachnodactyly: Marfan syndrome (see Figure 14.12)

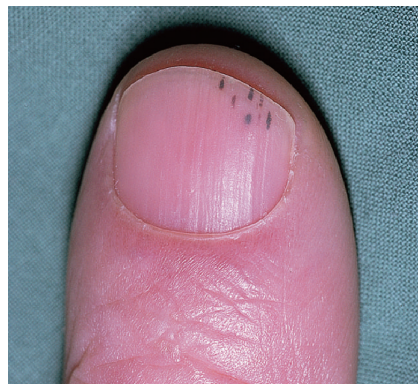

Figure 1.1 Splinter haemorrhages in a man with prosthetic valve endocarditis.

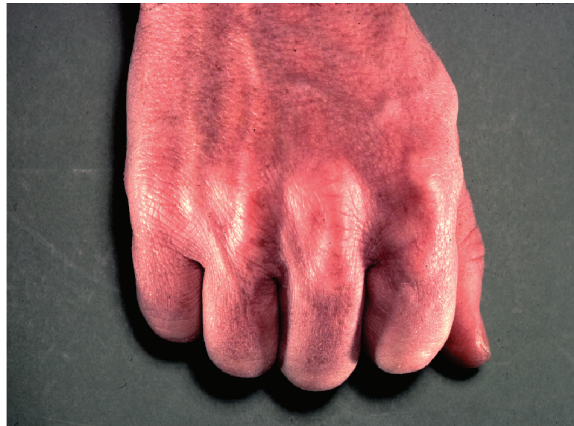

Figure 1.2 Hypercholesterolaemia: knuckle xanthomas.

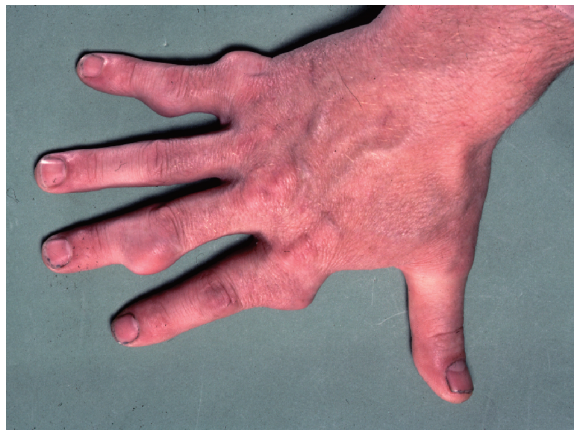

Figure 1.3 Familial hypercholesterolaemia: large xanthomas; serum cholesterol 14.1 mmol/l.

- Polydactyly, syndactyly, triphalangeal thumbs: ASD
- Tendon xanthomas: hypercholesterolaemia (Figures 1.2–1.5)
- Peripheral digital infarcts: hyperviscosity, cryoglobulinaemia (Figure 1.6).

Facial and General Appearance

- Down syndrome (AV canal)
- Elf-like facies (supravalvar aortic stenosis)
- Turner syndrome (coarctation, AS)
- Moon-like plump facies (pulmonary stenosis)
- Noonan syndrome (pulmonary stenosis, peripheral pulmonary artery stenosis)
- Mitral facies with pulmonary hypertension

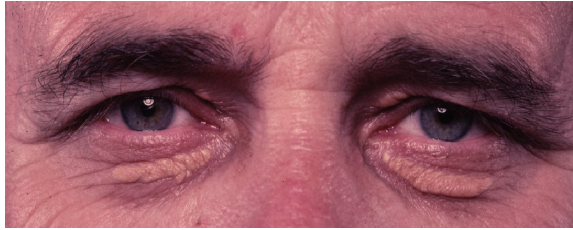


Figure 1.4 Xanthelasma.

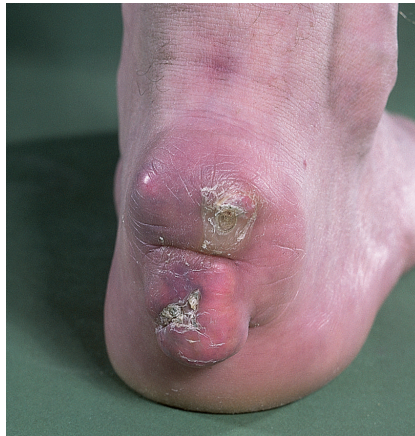

Figure 1.5 Tendon xanthomas: severe familial hypercholesterolaemia with massive cholesterol deposition in Achilles' tendon.

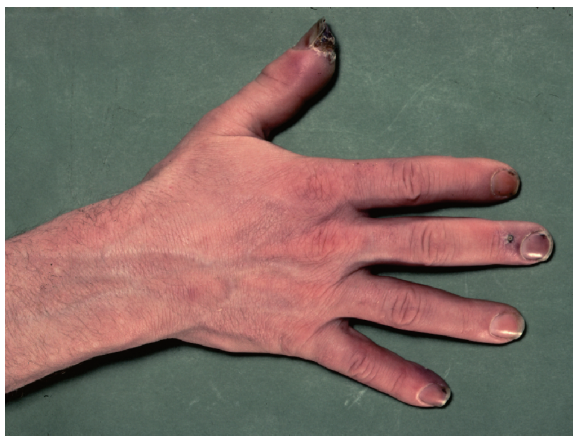

Figure 1.6 Peripheral digital infarcts: cryoglobulinaemia.

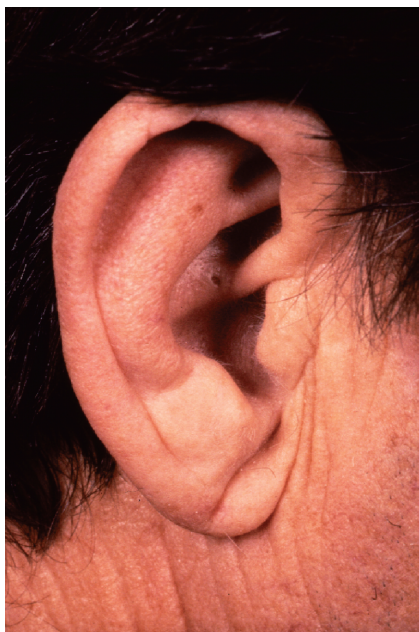

Figure 1.7 Ear-lobe crease: in a young patient may be a sign of coronary disease.

- Central cyanosis
- Differential cyanosis in PDA + pulmonary hypertension or interrupted aortic arch
- Xanthelasma (see Figure 1.4)
- Ear-lobe crease in the young patient (Figure 1.7) association with coronary disease
- Teeth: must be checked as part of general CVS examination
- Dyspnoea at rest. ?Accessory muscles of respiration.

The Jugular Venous Pulse

Waveform examples are shown in Figure 1.8. The JVP should fall on inspiration. Inspiratory filling of the neck veins occurs in pericardial constriction (Kussmaul's sign). The waves produced are as follows:

- 'a' wave: atrial systole. It occurs just before the carotid pulse and is lost in AF. Large 'a' waves indicate a raised RVEDP (e.g. PS, PHT). Cannon 'a' waves occur in: junctional tachycardia, complete AV block, ventricular ectopics (atrial systole against a closed tricuspid valve).
- 'c' wave: not visible with the naked eye. Effect of tricuspid valve closure on atrial pressure.
- 'x' descent: fall in atrial pressure during ventricular systole caused by downward movement of the base of the heart.

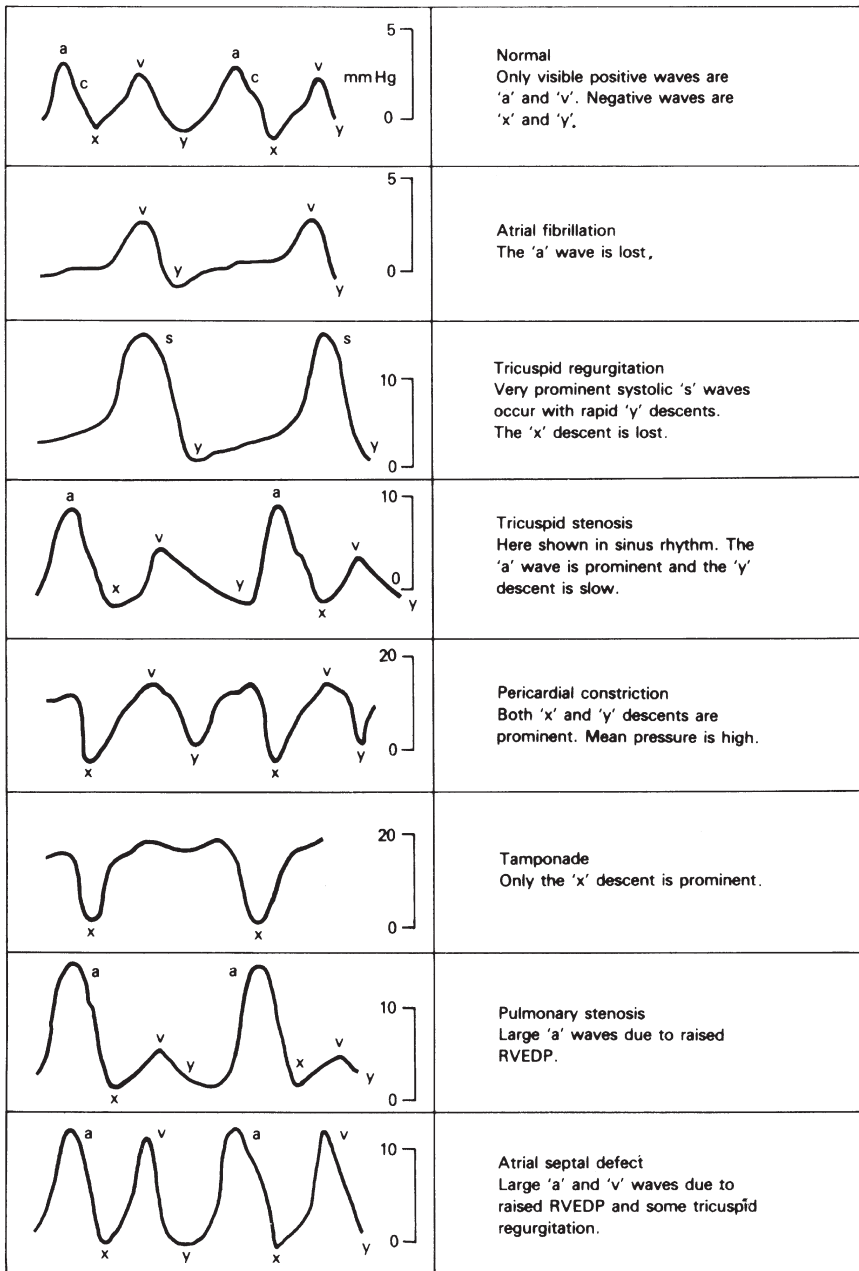


Figure 1.8 Examples of waveforms seen on jugular venous pulse.

- 'v' wave: atrial filling against a closed tricuspid valve.
- 'y' descent: diastolic collapse after opening of the tricuspid valve. Slow 'y' descent in patients with tricuspid stenosis or mechanical tricuspid valve replacements.
- 's' wave occurs in tricuspid regurgitation. Fusion of 'x' descent and 'v' wave into a large systolic pulsation can occur with rapid 'y' descent.

The normal range of JVP is -7 to $+3$ mmHg. The patient sits at 45° and the sternal angle is used as a reference point.

Distinction between the JVP and the Carotid Pulse

Distinction of the JVP from the carotid pulse involves the following five features:

- 1 Timing
- 2 The ability to compress the JVP
- 3 The ability to obliterate the JVP
- 4 The demonstration of hepatojugular reflux, the alteration of the JVP with position
- 5 The site of the pulsation itself.

Although transient pressure on the liver is classically used to augment the JVP, pressure anywhere on the abdomen will have the same effect. The congested liver is often tender and is pulsatile in severe tricuspid regurgitation.

Transient obliteration of the JVP to confirm that a pulse is venous is not easy. The internal jugular vein is wide at the base of the neck and using the point of a finger to obliterate it is often unsuccessful and thereby misleading. Use the whole of the side of the index finger pushed firmly and briefly against the side of the base of the neck. In addition the fact that a pulse is palpable does not necessarily mean that it is arterial. Strong venous pulsations are also palpable.

Using the external jugular vein to decide on the height of the JVP is not always reliable. In some patients there may be a slight positional kink between the junction of the external jugular vein with the subclavian vein. The external jugular vein may thus appear full when the JVP (taken from the internal jugular vein) is in fact normal.

The Carotid Pulse

Waveform examples are shown in Figure 1.9. There are three components to the carotid pulse: percussion wave, tidal wave and dicrotic notch.

Percussion Wave

This is a shock wave transmitted up the elastic walls of the arteries.

Tidal Wave

This is reflection of the percussion wave with a forward-moving column of blood. It follows the percussion wave and is not usually palpable separately.


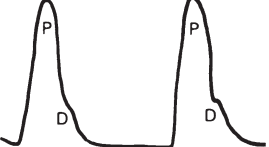





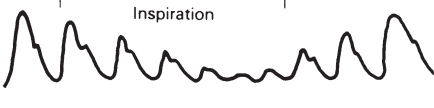
| | |
|---|--|
|  | <p>Normal P = Percussion wave transmitted up the elastic arterial walls. D = Dicrotic notch of aortic valve closure.</p> |
|  | <p>Collapsing pulse Run off from the aorta as in aortic regurgitation or AV fistula. Wide pulse pressure. Low diastolic pressure. Dicrotic notch low or absent. Very brisk upstroke.</p> |
|  | <p>Anacrotic pulse Aortic valve stenosis. Slow rising pulse with delayed percussion wave and sometimes a palpable judder on the upstroke. A = Anacrotic notch.</p> |
|  | <p>Bisferiens pulse Mixed aortic valve disease with significant regurgitation. There may be an additional upstroke judder. Percussion wave is followed by a pronounced tidal wave (T). Similar pulse seen in HCM.</p> |
|  | <p>Dicrotic pulse Also a double pulse but second wave is due to palpable dicrotic notch. Seen in febrile states, typhoid, vasodilatation with normal aortic valve.</p> |
|  | <p>Small volume collapsing pulse Only palpable wave is a small but quickly rising percussion wave. Seen in mitral regurgitation, or VSD (ventricular run-off).</p> |
|  | <p>Pulsus alternans Alternating big and small beats, often best appreciated following a ventricular ectopic. Indicates very poor LV function. Commonest in LV failure, DCM, aortic stenosis.</p> |
|  | <p>Pulsus paradoxus An excessive reduction in pulse pressure during inspiration (more than 10mmHg). Occurs in tamponade, pericardial constriction and status asthmaticus.</p> |

Figure 1.9 Examples of carotid pulse waveforms.

Dicrotic Notch

This is timed with aortic valve closure.

All the pulses are felt, radials and femorals simultaneously (coarctation). Any pulse may disappear with dissection of the aorta. Right arm and carotid pulses are stronger than left in supravalvar aortic stenosis (see Section 3.4).

An absent radial pulse may occur:

- after a peripheral embolus
- after a Blalock shunt on that side
- after brachial artery catheterization with poor technique on that side
- after a radial artery line for pressure monitoring, or after the use of the radial artery for cardiac catheterization
- with subclavian artery stenosis.

Palpation

This checks for: thrills, apex beat, abnormal pulsation and palpable sounds. Systolic thrill in the aortic area suggests aortic stenosis. Feel for thrills in other sites as follows.

- *Left sternal edge*: VSD or HCM
- *Apex*: ruptured mitral chordae
- *Pulmonary area*: pulmonary stenosis
- *Subclavicular area*: subclavian artery stenosis.

Diastolic thrills are less common: feel for apical diastolic thrill in mitral stenosis with patient lying on left side and breath held in expiration. A left sternal edge diastolic thrill is occasionally felt in aortic regurgitation.

Apex beat and cardiac pulsations

Heart is displaced, not enlarged (e.g. scoliosis, pectus excavatum?). Normal apex beat is in the fifth left intercostal space in the midclavicular line. It is palpable but does not lift the finger off the chest. In abnormal states distinguish:

- normal site but thrusting, e.g. HCM, pure aortic stenosis, hypertension, all with good LV
- laterally displaced and hyperdynamic, e.g. mitral and/or aortic regurgitation, VSD
- laterally displaced but diffuse, e.g. DCM, LV failure
- high dyskinetic apex, e.g. LV aneurysm
- double apex (enhanced by 'a' wave), in HCM, hypertension
- left parasternal heave; RV hypertrophy, e.g. pulmonary stenosis, cor pulmonale, ASD
- dextrocardia with apex in fifth right intercostal space.

Abnormal pulsations are very variable, e.g. ascending aortic aneurysm pulsating in aortic area, RVOT aneurysm in pulmonary area, collateral pulsation round the back in coarctation, pulsatile RVOT in ASD, pulsatile liver (felt in the epigastrium and right hypochondrium) in severe tricuspid regurgitation.

Palpable heart sounds represent forceful valve closure, or valve situated close to the chest wall, e.g. palpable S_1 (mitral closure) in mitral stenosis, P_2 in pulmonary hypertension, A_2 in transposition, or both S_1 and S_2 in thin patients with tachycardia.

1.3 Auscultation

Heart Sounds

First and second heart sounds are produced by valve closure. Mitral (M_1) and aortic (A_2) are louder than and precede tricuspid (T_1) and pulmonary (P_2) heart sounds. Inspiration widens the split.

A widely split second sound in mitral regurgitation and VSD is the result of early ventricular emptying and consequent early aortic valve closure. However, the widely split sound is rarely heard because the loud pansystolic murmur usually obscures it. A summary is shown in Table 1.3.

Third Sound (S_3)

This is pathological over the age of 30 years. It is thought to be produced by rapid LV filling, but the exact source is still debated. Loud S_3 occurs in a dilated LV with rapid early filling (mitral regurgitation, VSD) and is followed

Table 1.3 The first and second heart sounds

First sound (S_1) = $M_1 + T_1$

| Loud | Soft | Variable | Widely split |
|-------------------|---|-------------------------------|---------------------|
| Short PR interval | Long PR interval | Third-degree AV block | RBBB |
| Tachycardia | Heart block | AF | LBBB |
| Mitral stenosis | Delayed ventricular contraction (e.g. AS, infarction) | Nodal tachycardia or VT VT | VPBs |

Second sound (S_2) = $A_2 + P_2$

| Loud A_2 | Widely split | Reversed split | Single |
|------------------------------|----------------------|-----------------------|----------------------|
| Tachycardia | RBBB | LBBB | Fallot's tetralogy |
| Hypertension | PS (soft P_2) | Aortic stenosis | Severe PS |
| Transposition | Deep inspiration | PDA | Pulmonary atresia |
| | Mitral regurgitation | RV pacing | Eisenmenger syndrome |
| | VSD | | Large VSD |
| | Hypertension | | |

Loud P_2 **Fixed split**

| | |
|-----|-----|
| PHT | ASD |
|-----|-----|

by a flow murmur. It also occurs in a dilated LV with high LVEDP and poor function (post-infarction, DCM). A higher-pitched early S_3 occurs in restrictive cardiomyopathy and pericardial constriction.

Fourth Sound (S_4)

The atrial sound is not normally audible but is produced at end-diastole (just before S_1) with a high end-diastolic pressure or with a long PR interval. It disappears in AF. It is most common in systemic hypertension, aortic stenosis, HCM (LV S_4), pulmonary stenosis (RV S_4) or after an acute MI.

Triple Rhythm

A triple/gallop rhythm is normal in children and young adults but is usually pathological over the age of 30 years. S_3 and S_4 are summated in SR with a tachycardia.

S_3 and S_4 are low-pitched sounds. Use the bell of the stethoscope and touch the chest lightly.

Added Sounds

- *Ejection sound*: in bicuspid aortic or pulmonary valve (not calcified), i.e. young patients
- *Midsystolic click*: mitral leaflet prolapse
- *Opening snap, mitral*: rarely tricuspid (TS, ASD, Ebstein's anomaly)
- *Pericardial clicks* (related to posture).

Innocent Murmurs

Probably 30% of healthy young children have a heart murmur but <1% will have congenital heart disease. This is usually the result of a pulmonary flow murmur heard best at the left sternal edge radiating into the pulmonary area.

Characteristics of Innocent Murmur

- Ejection systolic: diastolic or pansystolic murmurs are pathological. The only exceptions are a venous hum or mammary soufflé.
- No palpable thrill.
- No added sounds (e.g. ejection click).
- No signs of cardiac enlargement.
- Left sternal edge to pulmonary area. May be heard at the apex.
- Normal femoral pulses.
- Normal ECG: chest radiograph or echocardiogram may be necessary for confirmation.

The venous hum is a continuous murmur, common in children, reduced by neck vein compression, turning the head laterally, bending the elbows back or lying down. It is at its loudest in the neck and around the clavicles. It may reappear in pregnancy.

Pathological Murmurs

These are either organic (valve or subvalve lesion) or functional (increased flow, dilated valve rings, etc.). They are discussed under individual conditions in subsequent chapters.

They should be graded as just audible, soft, moderate or loud. Grading on a 1–6 basis is unnecessary and unhelpful. The murmur should also be classified as to site, radiation, timing (systolic or diastolic, and which part of each), and behaviour with respiration and position. Many murmurs can be accentuated with effort. Alteration of the murmur with position (e.g. squatting) is important in HCM, mitral prolapse and Fallot's tetralogy. The quality of the murmur itself should also be described, e.g. low- or high-pitched, rasping, musical or honking in quality.

Some systolic murmurs can be accentuated by particular manoeuvres. Pansystolic murmurs of VSD and mitral regurgitation are increased by hand grip, and decreased by amyl nitrate inhalation. The systolic murmur of hypertrophic obstructive cardiomyopathy is typically accentuated during the Valsalva manoeuvre and by standing suddenly from a squatting position. The murmur in HCM is reduced by passive leg elevation, hand grip and squatting from a standing position (see Section 4.2).

Accurate documentation of the murmur is important because murmurs may change over time. With a closing VSD the murmur shortens from a pansystolic to an ejection systolic murmur (see Section 2.1). With a floppy mitral valve, a soft late systolic mitral murmur may lengthen to become a pansystolic murmur as the mitral leak becomes worse (see Section 3.3).

Finally, it is important to remember that the loudness of a murmur bears no relationship to the severity of the valve lesion. In summary any of the following features suggest that the murmur is organic/pathological:

- Symptoms
- Cyanosis
- Thrill
- Large heart clinically or on chest radiograph
- A diastolic murmur
- A very loud murmur
- A pansystolic murmur
- Added sounds: ejection clicks, opening snaps, etc. (not S₃ which is normal in young people).

Special Points in Neonates and Infants

- A murmur heard immediately after birth is usually the result of a stenotic lesion. Murmurs from a small VSD or PDA are usually heard a few days later, and from a large VSD still later, as the pulmonary vascular resistance falls. The absence of a murmur does not exclude congenital heart disease. Under-sized neonates may have an innocent murmur that arises from relatively hypoplastic pulmonary arteries waiting to grow. This sort of murmur usually disappears by the age of 6 months.

- Does the child have other features? For example:
 - Turner syndrome: coarctation or atretic aortic arch
 - Noonan syndrome: pulmonary stenosis
 - Down syndrome: AV canal
 - Williams syndrome: supraaortic stenosis, pulmonary artery stenoses.
- Clubbing will not be apparent until the child has been cyanosed for ≥ 6 months. Cyanosis in a neonate always needs investigation.
- Pectus excavatum rarely causes any cardiac embarrassment, but may cause slight displacement of the heart on a chest radiograph. Sometimes associated later with a straight-back syndrome and floppy mitral valve. Pectus carinatum (pigeon chest) is not caused by cardiac enlargement. It may sometimes be the result of a large main pulmonary artery in large left-to-right shunts.
- Tachypnoea, hepatomegaly, sweating forehead and Harrison's sulci all suggest cardiac failure that is most likely to be caused by a left-to-right shunt.
- Midline liver, asplenia, polysplenia, etc. suggest complex congenital heart disease.
- Poor pulses in the legs suggest coarctation or hypoplastic left heart syndrome. Bounding pulses in the legs: PDA, truncus arteriosus or aortic regurgitation.