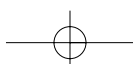
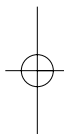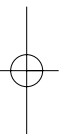


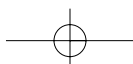
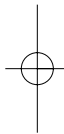
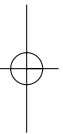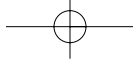


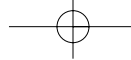
Part 1

Focus on

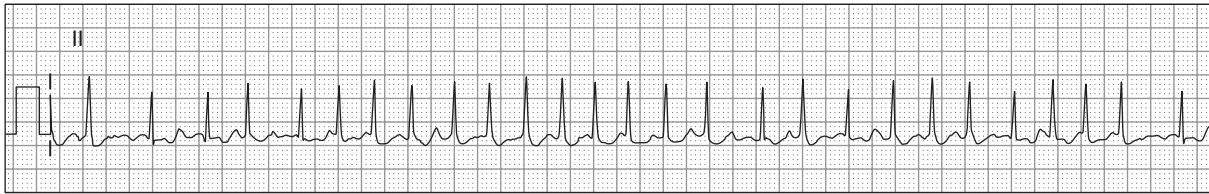dysrhythmias



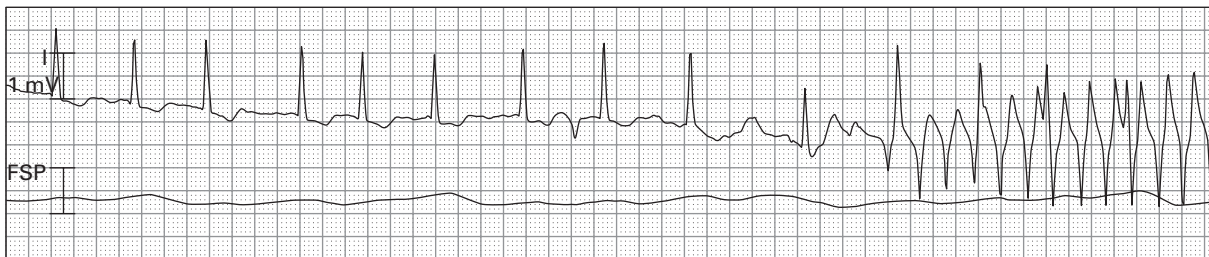



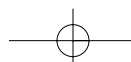
Case histories



1. 63 year old woman with palpitations, weakness, and dyspnea

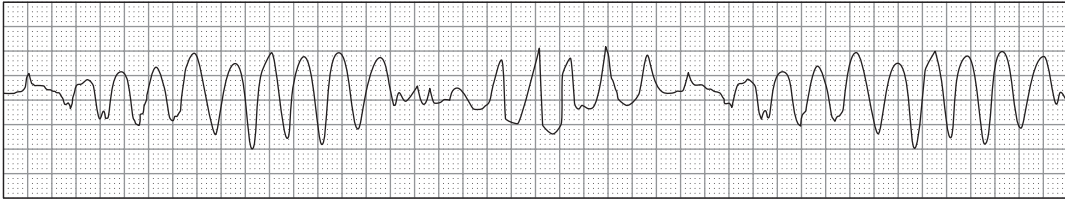


2. 71 year old febrile man with pneumonia

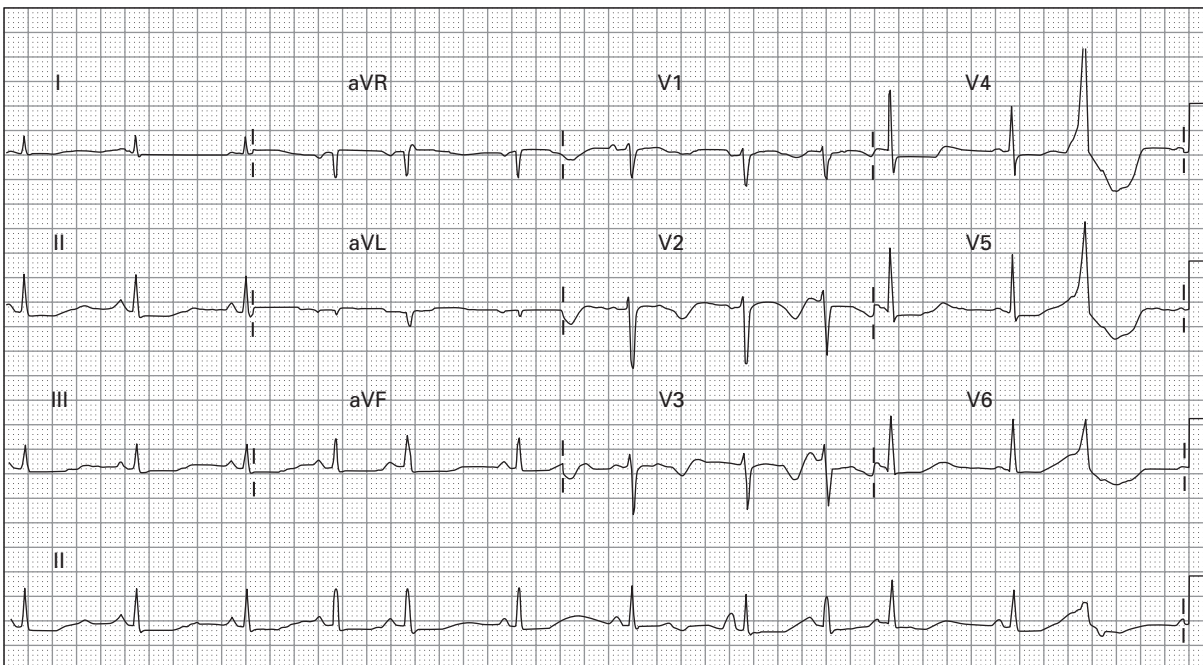


ECGs FOR THE EMERGENCY PHYSICIAN 2

a)



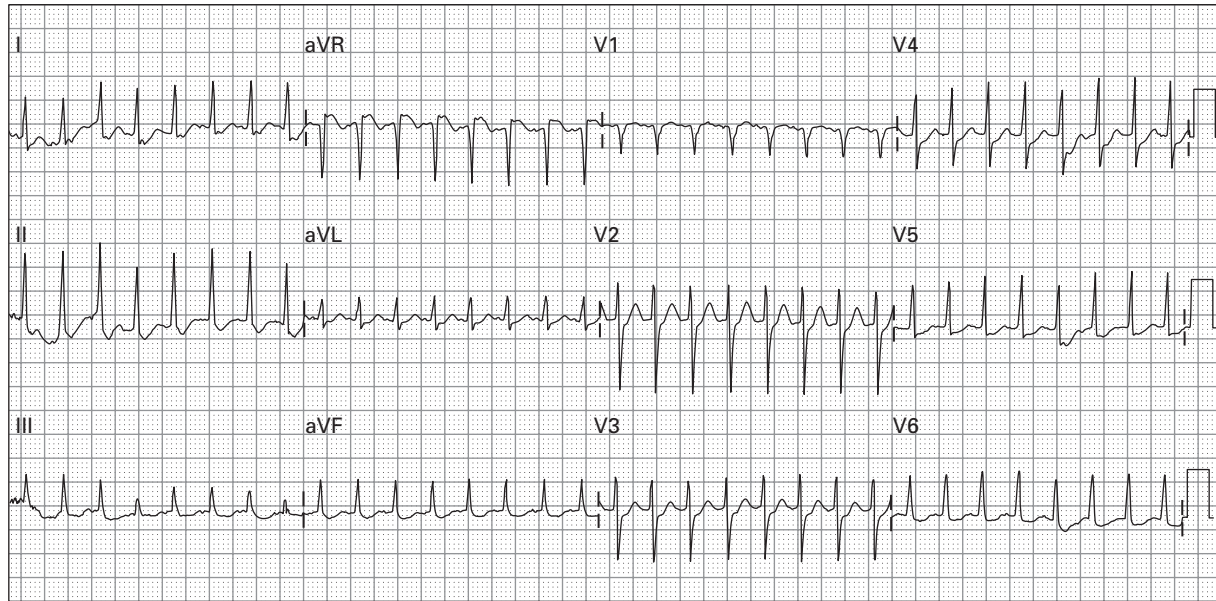
b)



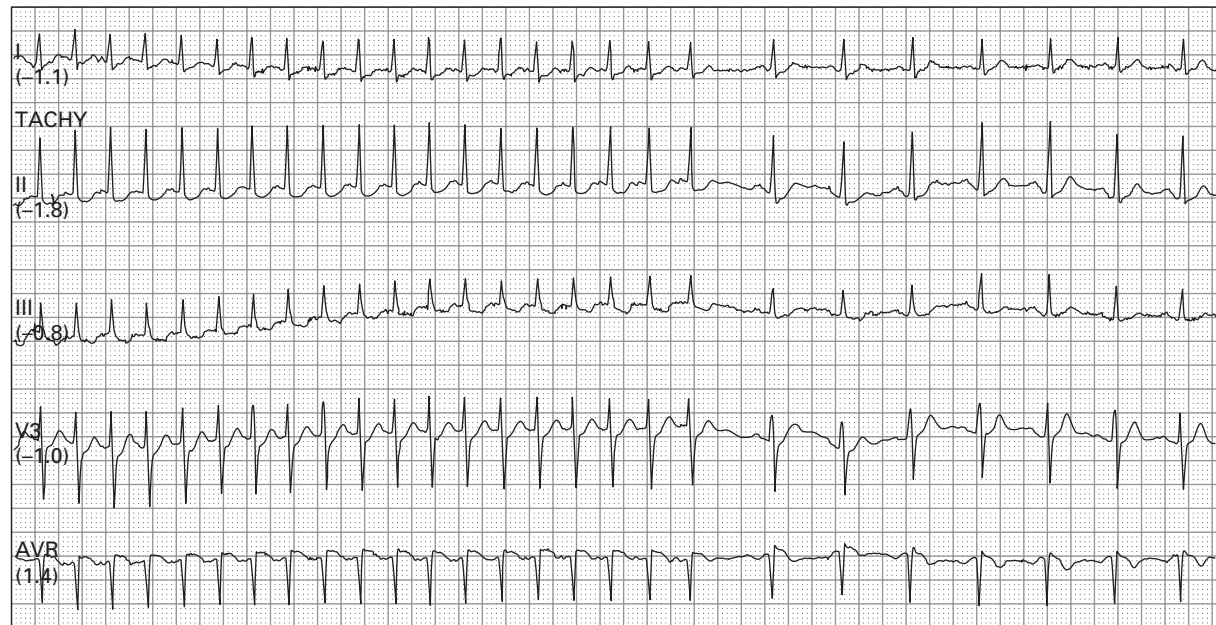
3. 54 year old dehydrated woman with gastroenteritis and recurrent syncope, a) during an episode of "syncope", b) after spontaneous conversion

PART 1: CASE HISTORIES

a)

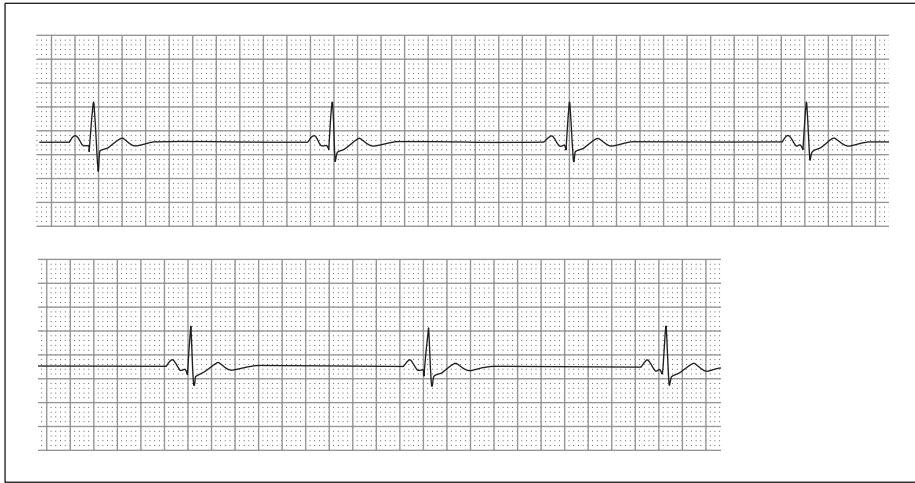


b)

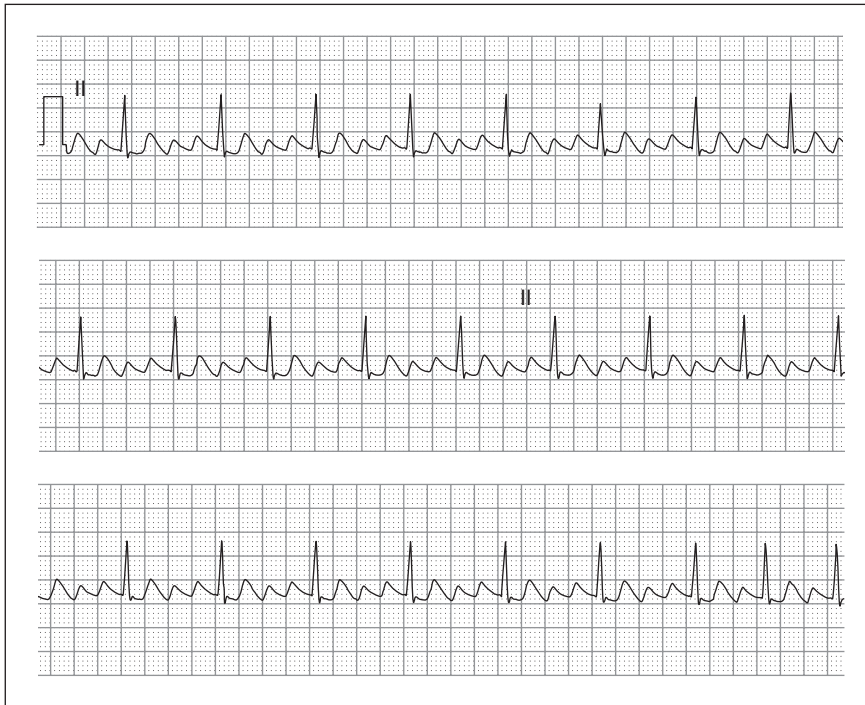


4. a) 18 year old woman with palpitations, dizziness, and hypotension, b) during treatment

ECGs FOR THE EMERGENCY PHYSICIAN 2

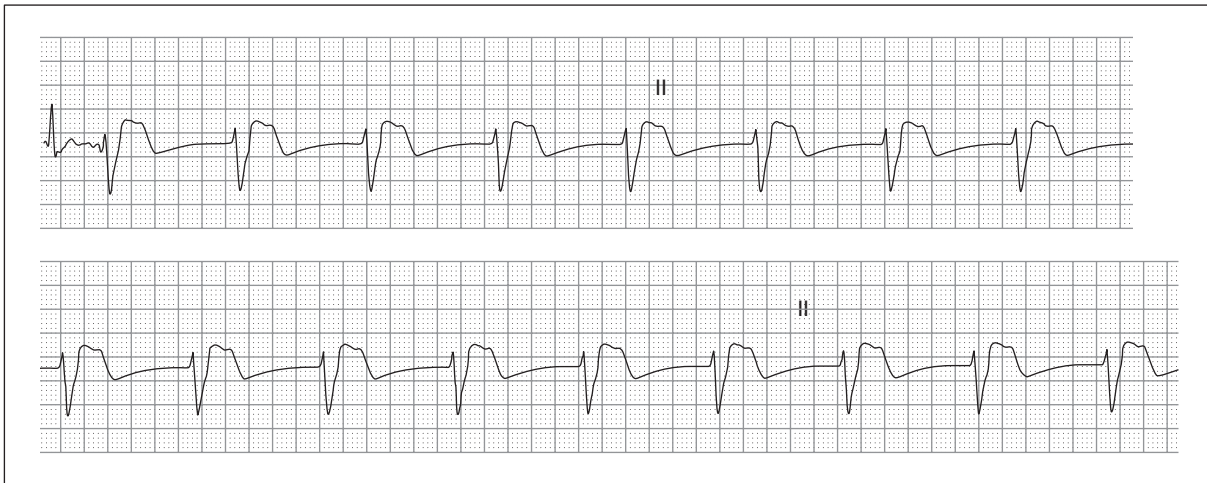


5. 68 year old man with hypertension, managed with three medications, presenting with profound weakness

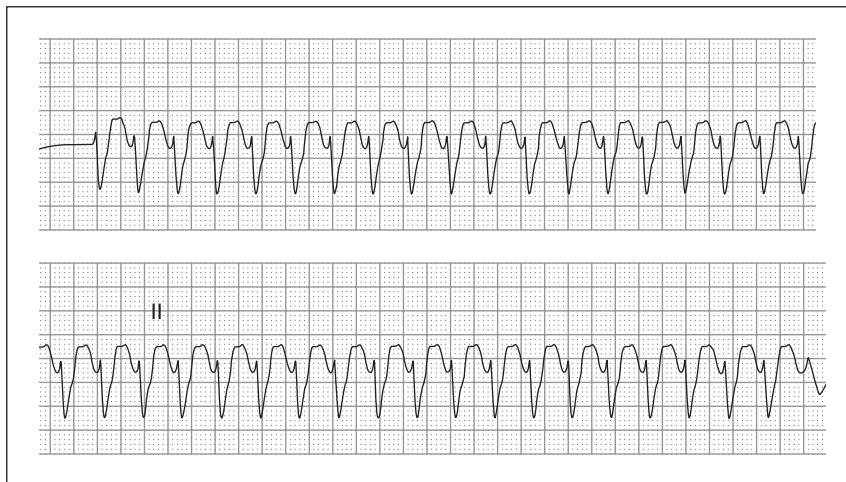


6. 57 year old woman with palpitations and exercise intolerance

PART 1: CASE HISTORIES

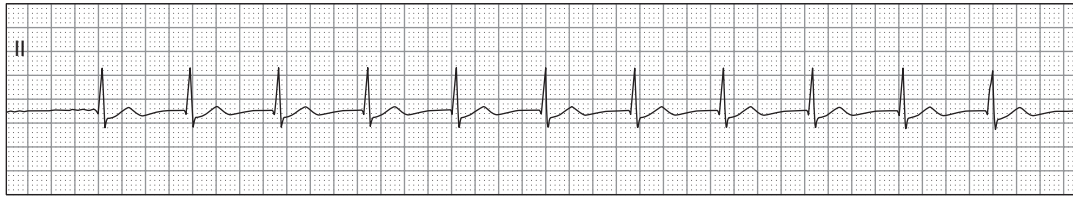


7. 42 year old man 30 minutes after receiving fibrinolytics for an acute myocardial infarction

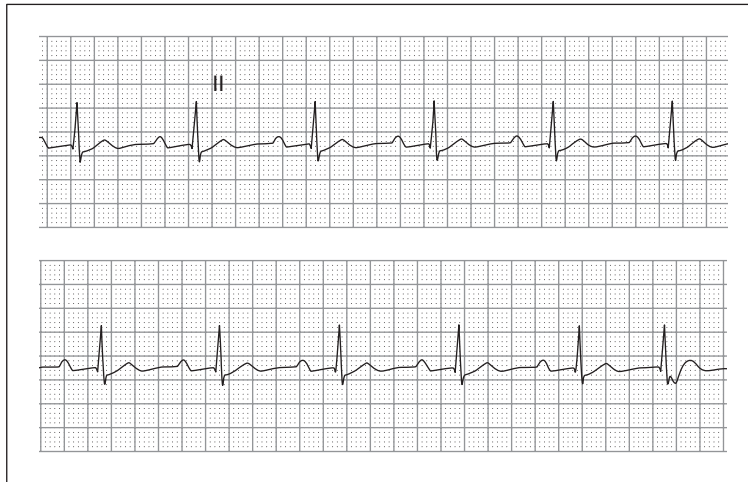


8. 53 year old man with past myocardial infarction presenting with hypotension and acute pulmonary edema

ECGs FOR THE EMERGENCY PHYSICIAN 2

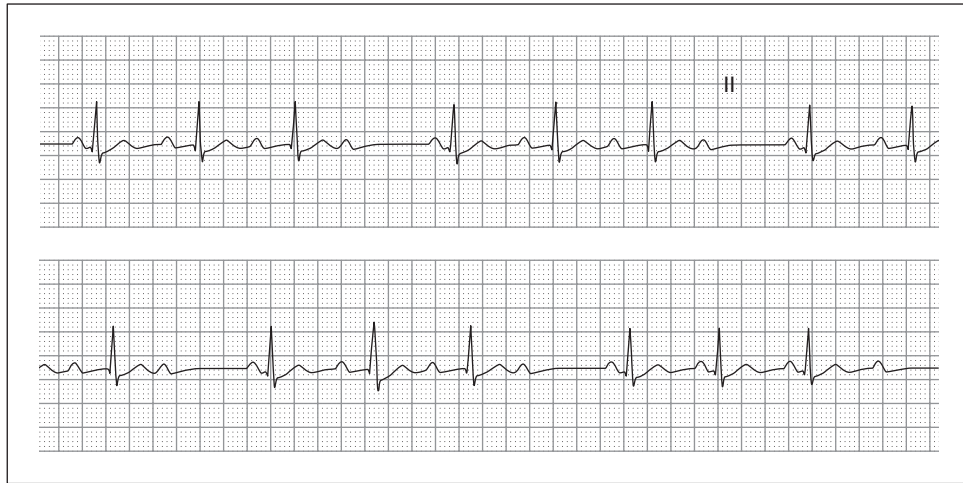


9. 79 year old woman with hypertension and chronic congestive heart failure complaining of weakness and dyspnea

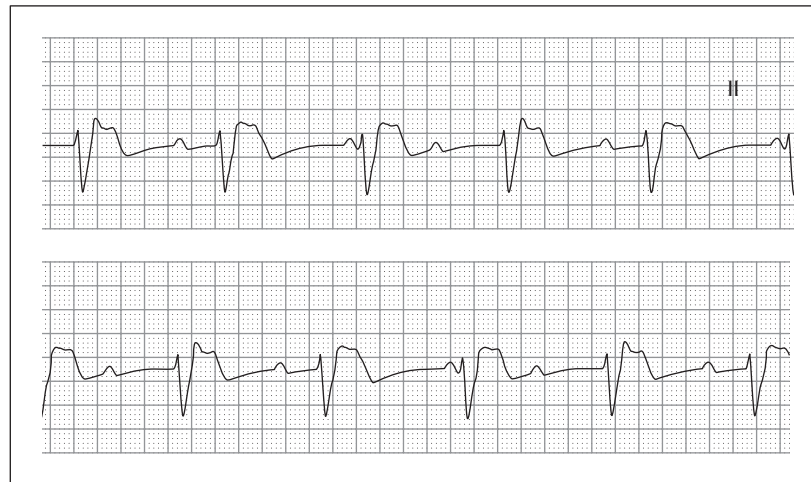

10. 29 year old man presenting with an ankle fracture; the patient is a long-distance runner

PART 1: CASE HISTORIES

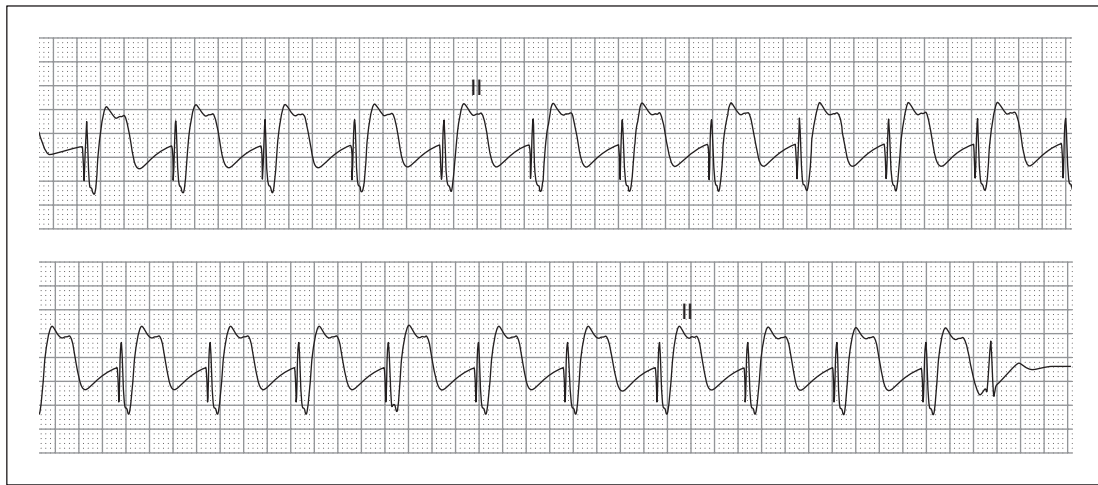


11. 71 year old woman with syncope

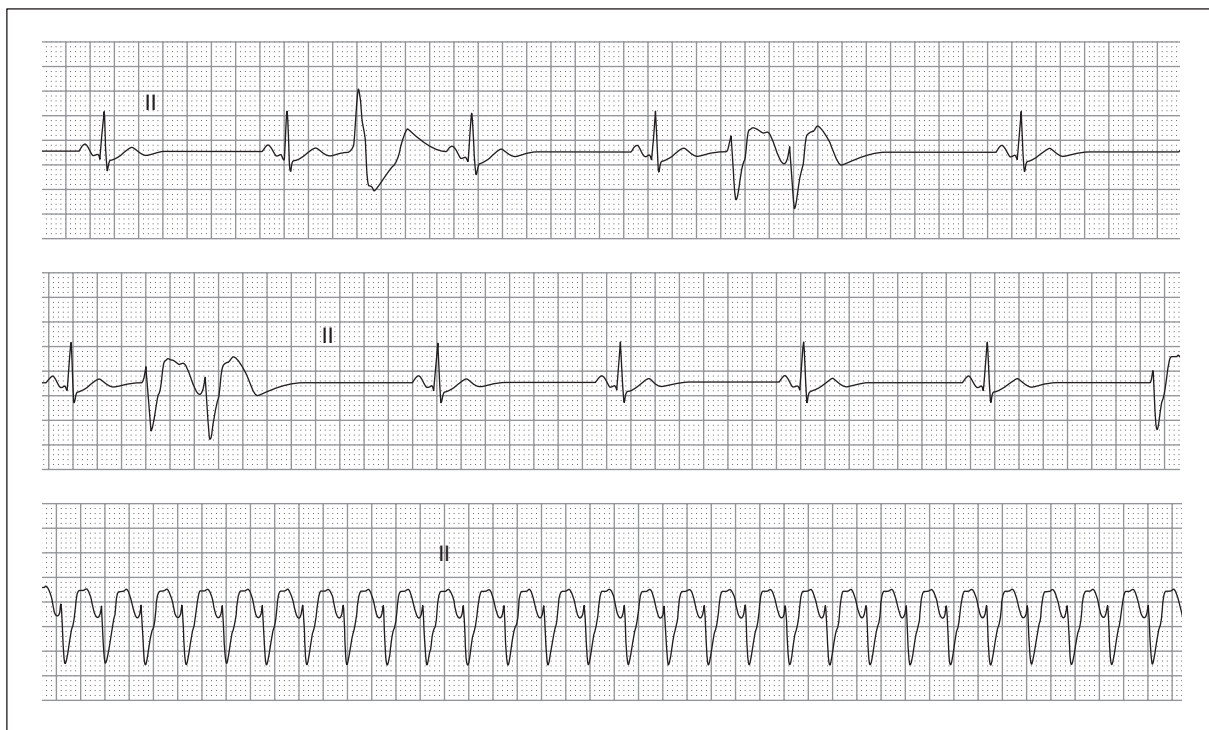


12. 79 year old man with progressive weakness

ECGs FOR THE EMERGENCY PHYSICIAN 2

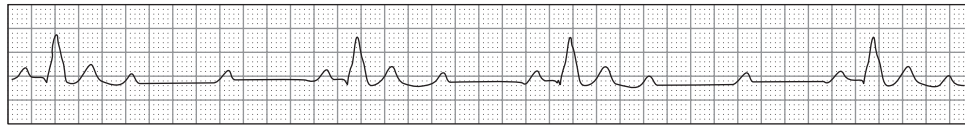


13. 59 year old woman being resuscitated during a cardiac arrest

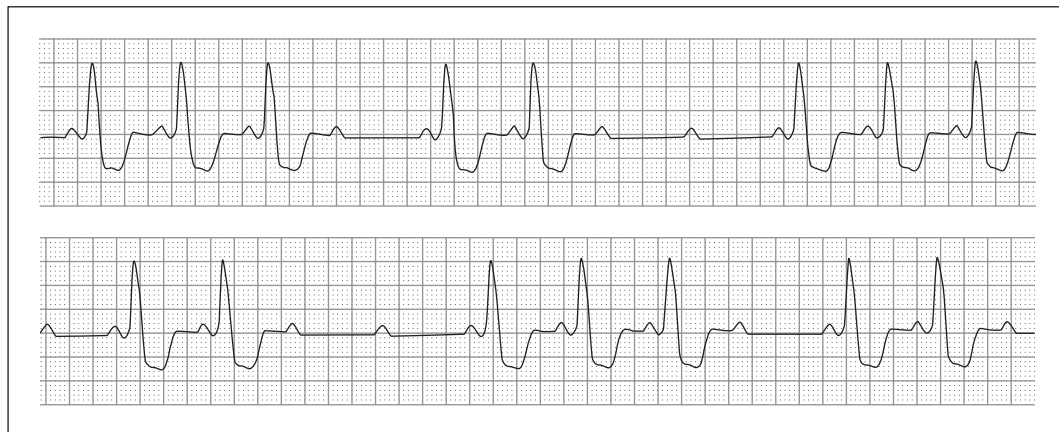

14. 68 year old woman with sudden loss of consciousness

PART 1: CASE HISTORIES

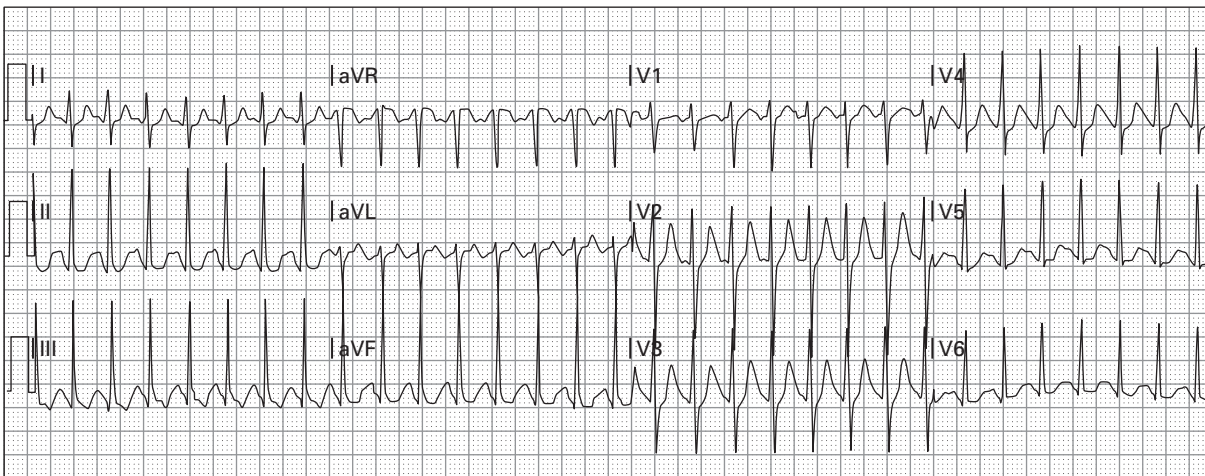
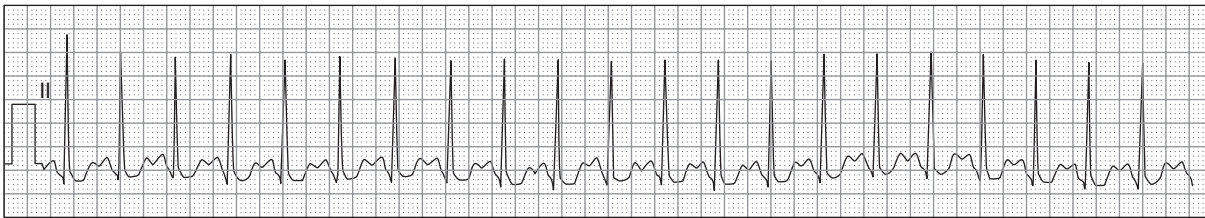


15. 66 year old man with a history of sick sinus syndrome and hypertension who notes extreme dizziness



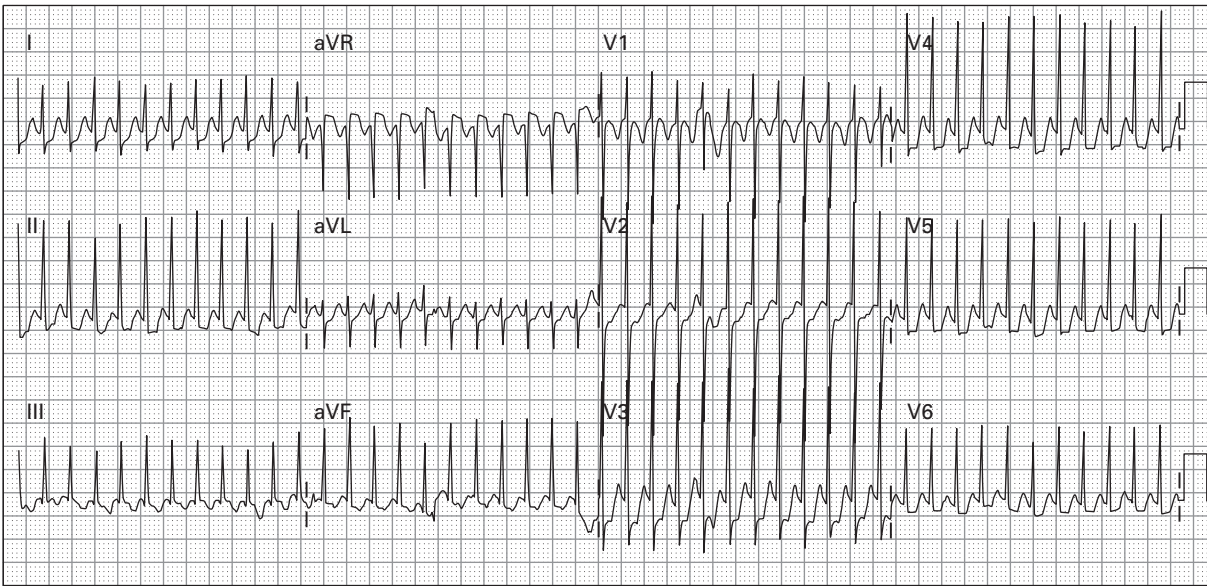
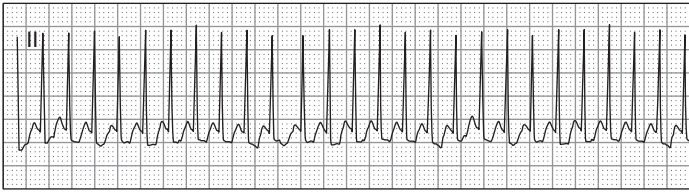
16. 56 year old woman with recently diagnosed acute myocardial infarction

ECGs FOR THE EMERGENCY PHYSICIAN 2



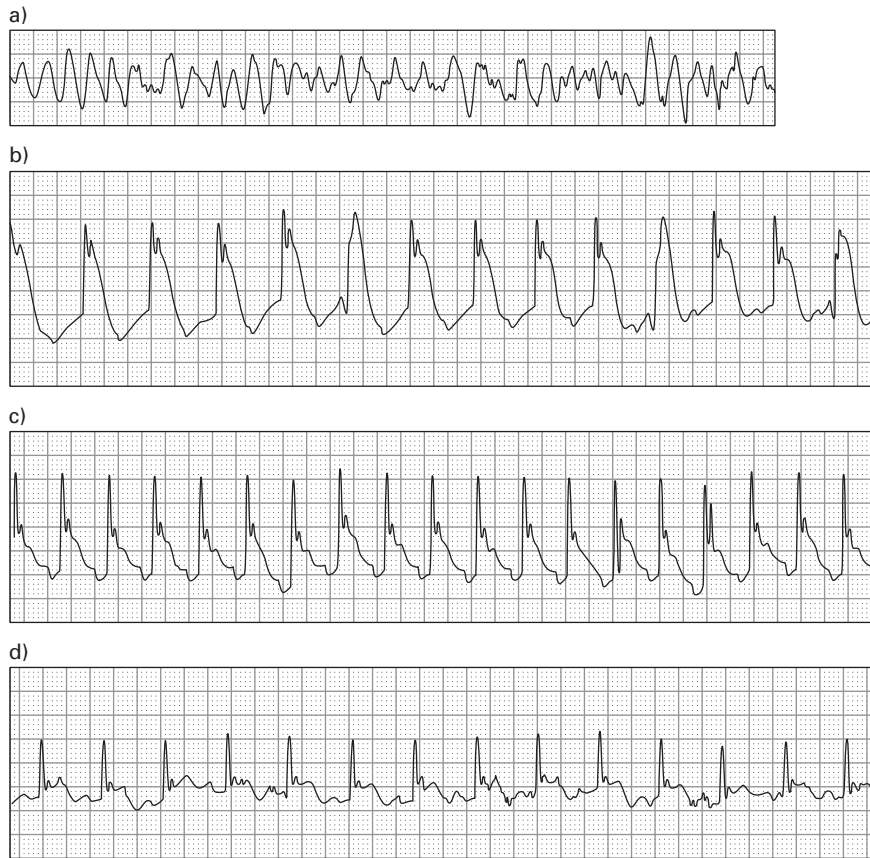17. 26 year old woman with extreme anxiety after cocaine ingestion (nasal)

PART 1: CASE HISTORIES

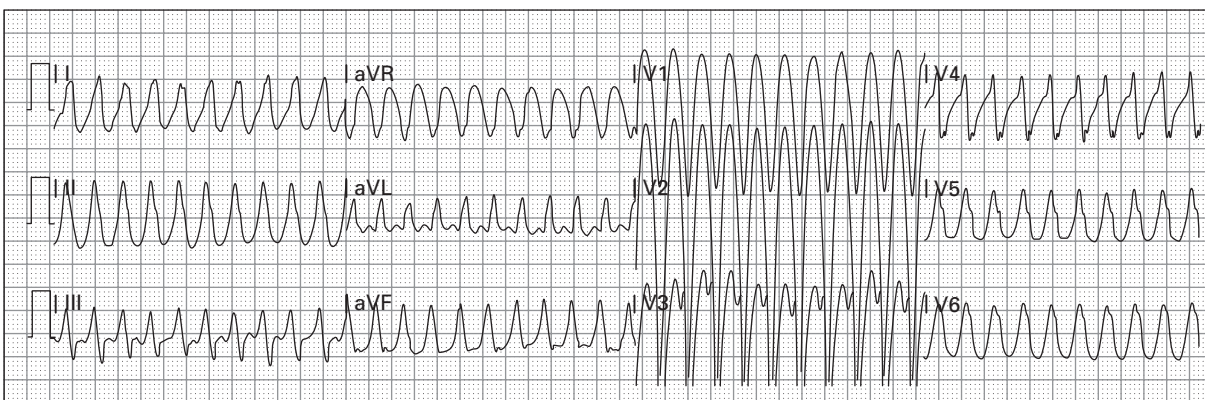
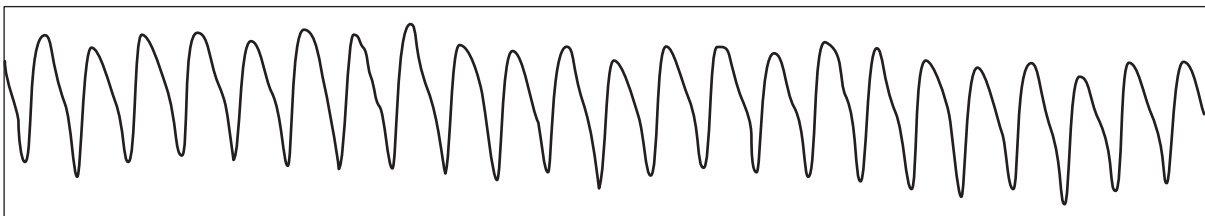


18. 18 month old child with fussiness and poor feeding

ECGs FOR THE EMERGENCY PHYSICIAN 2

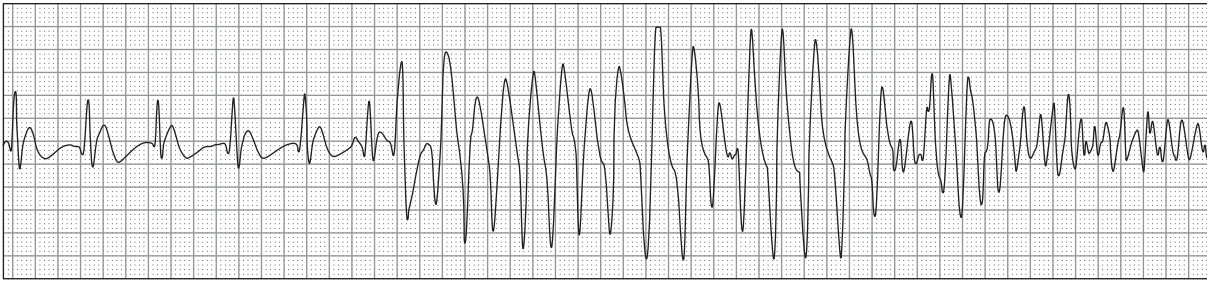


19. a)–d) 54 year old man with chest pain suddenly becomes unresponsive

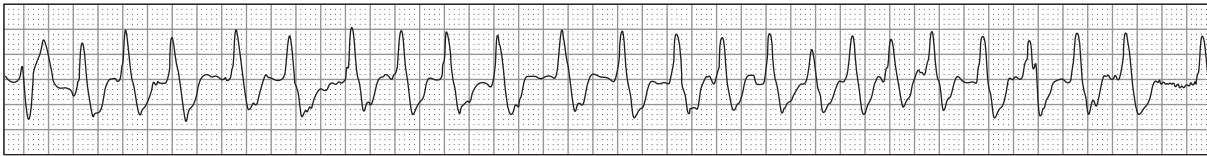


20. 60 year old man with dyspnea, profound weakness, and hypotension

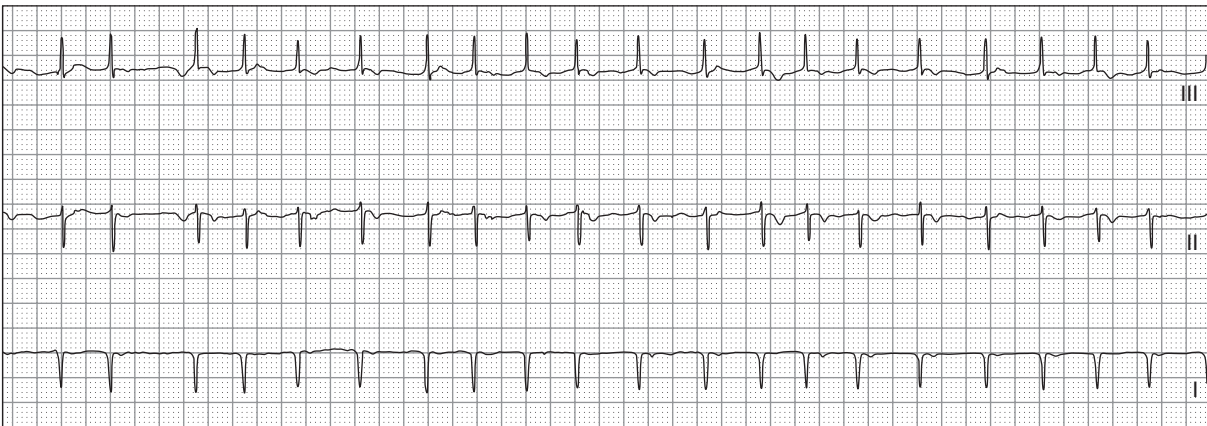
PART 1: CASE HISTORIES



21. 65 year old woman with chest pain suspected of acute myocardial infarction and sudden loss of consciousness

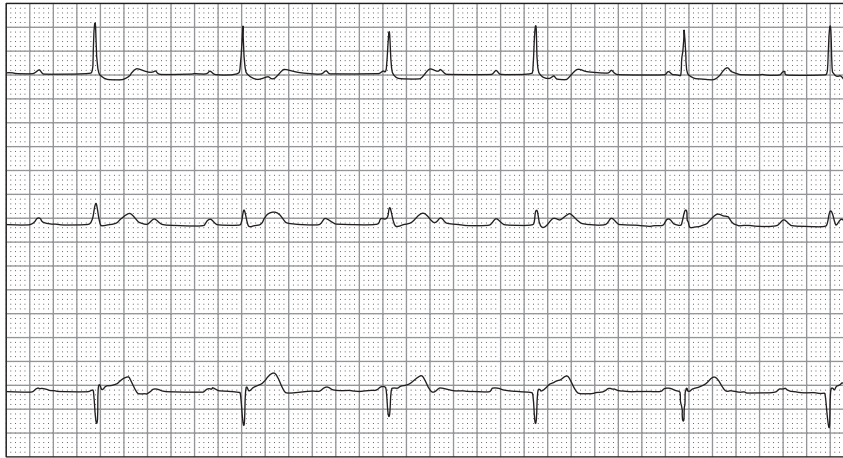


22. 67 year old woman with the sensation of a rapid heart beat

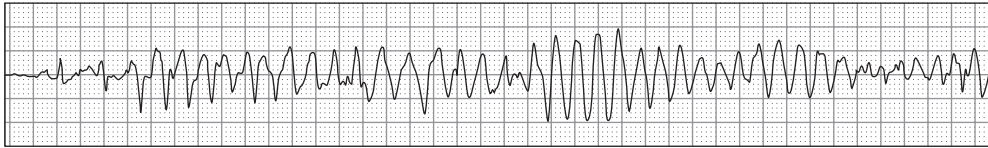


23. 65 year old man with chronic obstructive pulmonary disease and acute dyspnea

ECGs FOR THE EMERGENCY PHYSICIAN 2



24. 75 year old woman with a decreased level of consciousness



25. 16 year old boy presents after a syncopal episode, now with recurrent sudden loss of consciousness