




Select a chapter from the list below:

Contents

[Print Page](#)

- [1 Introduction and Historical Bibliography](#)
- [2 Comparative Dermatology](#)
- [3 Anatomy and Organization of Human Skin](#)
- [4 Functions of the Skin](#)
- [5 Diagnosis of Skin Disease](#)
- [6 Epidemiology of Skin Disease](#)
- [7 Histopathology of the Skin: General Principles](#)
- [8 Molecular Biology](#)
- [9 Inflammation](#)
- [10 Clinical Immunology, Allergy and Photoimmunology](#)
- [11 Wound Healing](#)
- [12 Genetics and Genodermatoses](#)
- [13 Prenatal Diagnosis of Genetic Skin Disease](#)
- [14 The Neonate](#)
- [15 Naevi and other Developmental Defects](#)
- [16 Pruritus](#)
- [17 Eczema, Lichenification, Prurigo and Erythroderma](#)
- [18 Atopic Dermatitis](#)
- [19 Contact Dermatitis: Irritant](#)
- [20 Contact Dermatitis: Allergic](#)
- [21 Occupational Dermatoses](#)
- [22 Mechanical and Thermal Injury](#)






Select a chapter from the list below:

Contents

[Print Page](#)

- [1 Introduction and Historical Bibliography](#)
- [2 Comparative Dermatology](#)
- [3 Anatomy and Organization of Human Skin](#)
- [4 Functions of the Skin](#)
- [5 Diagnosis of Skin Disease](#)
- [6 Epidemiology of Skin Disease](#)
- [7 Histopathology of the Skin: General Principles](#)
- [8 Molecular Biology](#)
- [9 Inflammation](#)
- [10 Clinical Immunology, Allergy and Photoimmunology](#)
- [11 Wound Healing](#)
- [12 Genetics and Genodermatoses](#)
- [13 Prenatal Diagnosis of Genetic Skin Disease](#)
- [14 The Neonate](#)
- [15 Naevi and other Developmental Defects](#)
- [16 Pruritus](#)
- [17 Eczema, Lichenification, Prurigo and Erythroderma](#)
- [18 Atopic Dermatitis](#)
- [19 Contact Dermatitis: Irritant](#)
- [20 Contact Dermatitis: Allergic](#)
- [21 Occupational Dermatoses](#)
- [22 Mechanical and Thermal Injury](#)



Search
⌵ □ ✕

SEARCH

Search term or phrase
Help

psoriasis

AND

▼

child

OR

▼

Search in:

Search the complete text

- Exclude references
- Exclude figures

Restrict search to headings

Restrict search to references

Restrict search to figures

Highlight search words in the text

Results will be displayed in Chapter order (under the chapter headings) and then in alphabetical order by section heading.

Close

Search



15 Naevi and other Developmental Defects

[<< Chapter Contents](#)

[Print Page](#)

- Definitions
- Aetiology
- Classification of naevi
- Blaschko's lines
- Epidermal naevi
 - Verrucous epidermal naevus
 - Sebaceous naevus
 - Follicular naevi
 - Apocrine naevi
 - Eccrine naevi
 - Becker's naevus
 - Inflammatory epidermal naevi
 - Other naevoid epidermal disorders
 - The epidermal naevus syndromes
- Dermal and subcutaneous naevi

Epidermal naevi

The term epidermal naevus is used for naevi composed of keratinocytes. Recently, the molecular causes of certain epidermal naevi have been elucidated, enabling us to differentiate between them. However, the older literature does not differentiate between, for example, epidermolytic and non-epidermolytic naevi, and therefore clinical descriptions must be read in this light.

Probably all epidermal naevi comprise an abnormal clone of cells, reflecting genetic mosaicism arising from somatic mutation (see above). The clinical implications of mosaicism are firstly that it is unlikely to recur in the same family, and secondly that there is a theoretical risk of the condition being passed on to the patient's offspring in a severe or even lethal generalized form. Curiously these predictions are not always borne out, as is discussed under the individual headings.

Verrucous epidermal naevus

syn. naevus verrucosus; naevus unius lateris

Definition

... ..

[Previous](#)

[Next](#)



25 Virus Infections

[<< Chapter Contents](#)

[Print Page](#)

- Varicella (chickenpox) and zoster (shingles)
- Cytomegalovirus
- Epstein-Barr virus
- Human herpesvirus 6
- Human herpesvirus 7
- Human herpesvirus 8
- Herpes B virus
- Kaposi's varicelliform eruption including eczema herpeticum
- Human papillomaviruses
- Warts
- HPV-associated epidermal dysplasia and neoplasia
- Epidermodysplasia verruciformis
- HPV in immunosuppression

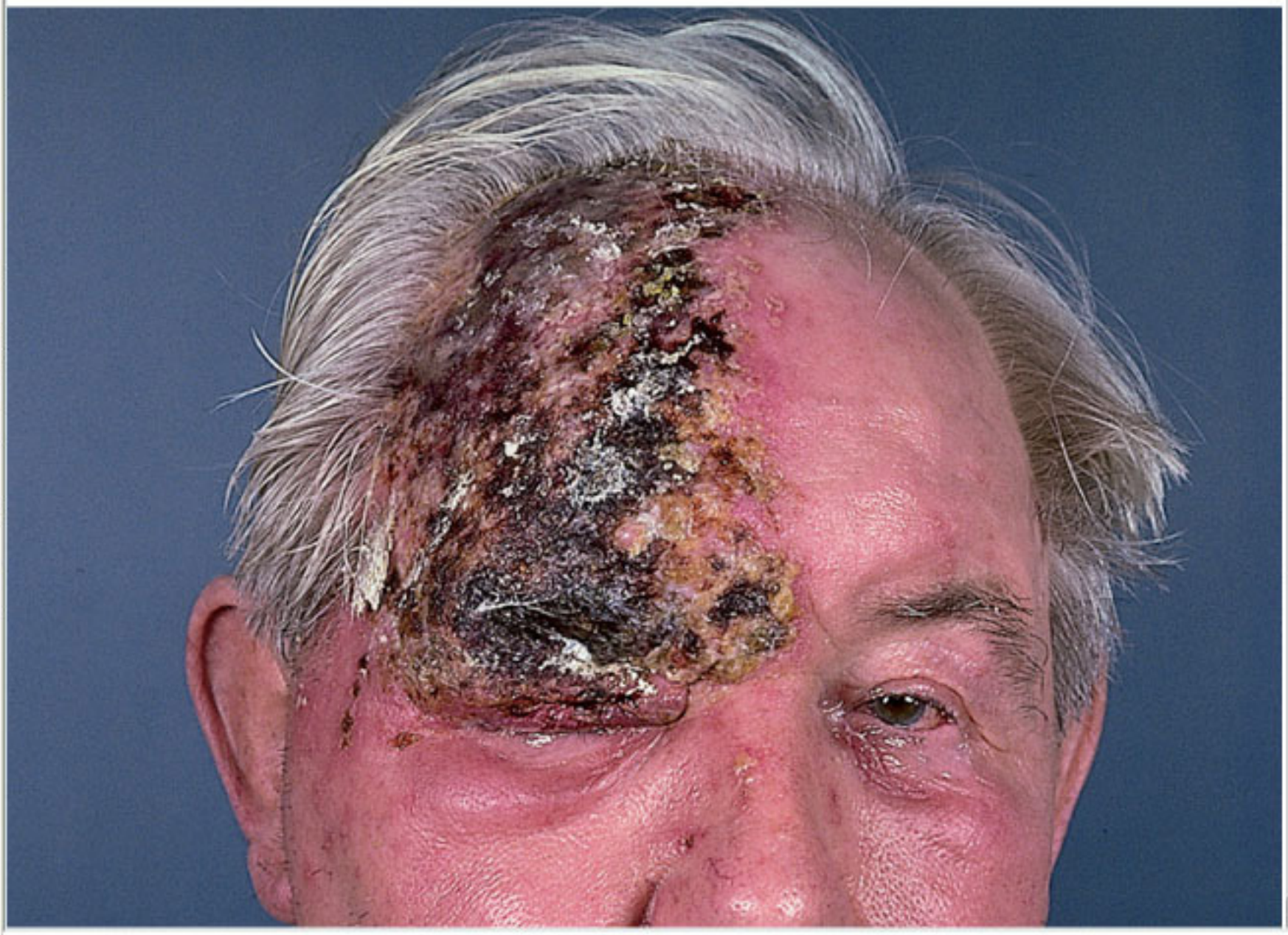In ophthalmic nerve vesicles on the side complications include palsies, proptosis and ulceration, so-called Argyll Robertson pupil. Zoster of the maxillary while with involvement floor of the mouth symptom [24].

Herpes zoster oticus
The facial nerve, not pinna and meatus these fibres cause be minimal and limited infected is debated spaces of the face.

[Previous](#)

Figures & Tables

Fig. 25.14 Ophthalmic zoster. (Courtesy of York District Hospital, York, UK.)



[Close](#)

[Print](#)