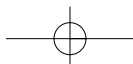


# 5 Exodontics



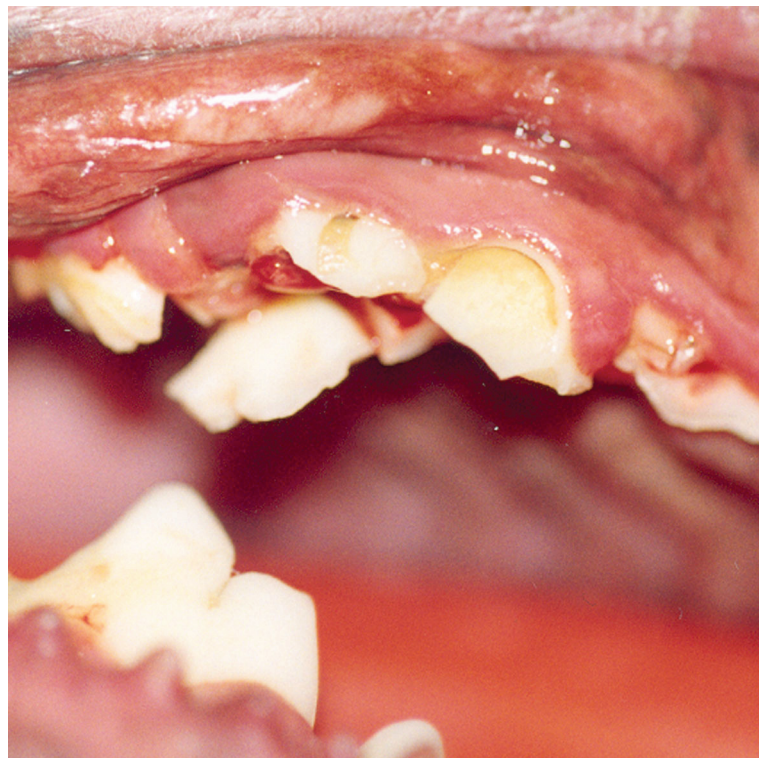
Tooth extraction is final. In selected cases teeth can be replaced using implants however for most pet owners this procedure is cost prohibitive.

Adequate analgesia must be given to patients about to undergo tooth extraction (see Chapter 11 – Pain Management.)

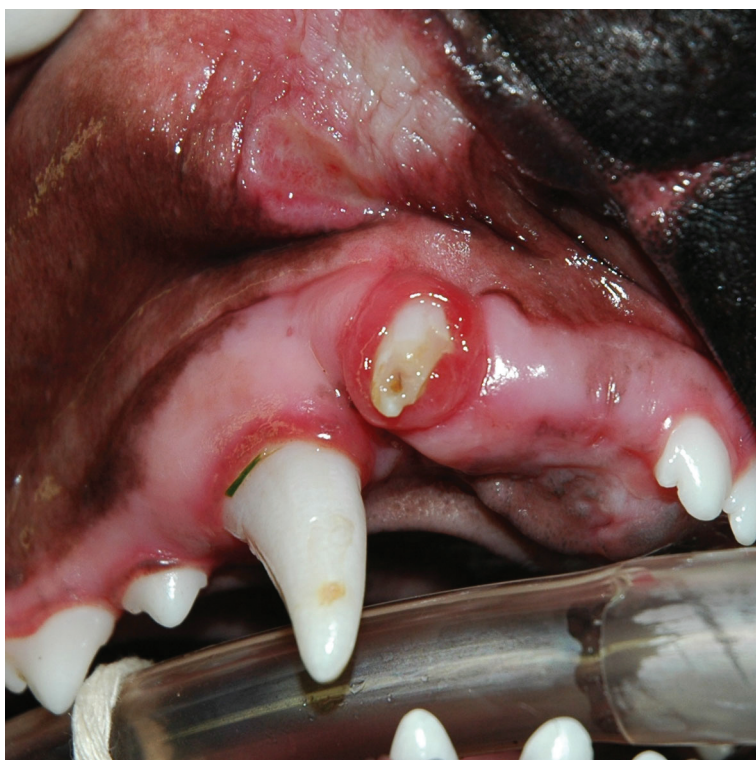### Indications for tooth extraction

- fractured teeth which cannot be restored
- teeth affected by caries (lesions so severe that restoration is not possible)
- persistent deciduous teeth
- supernumerary teeth causing crowding
- maloccluding teeth
- teeth in a jaw fracture line (which are not providing fixation stability)
- periodontally compromised teeth
- severe chronic gingivo-stomatitis
- malformed teeth causing gingivitis and periodontal disease
- luxated or subluxated teeth (including intruded teeth) not amenable to treatment
- retained (unerupted) teeth
- teeth affected by odontoclastic resorption

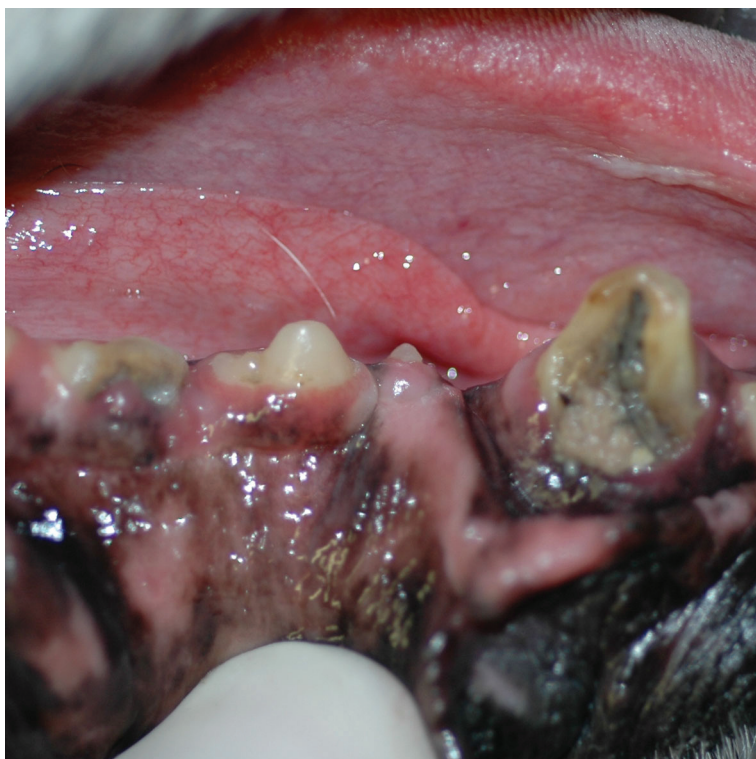Figures 5.1–5.22 are a series of indications for extraction.



**Figure 5.1** This patient was kicked in the mouth by a horse and suffered multiple fractures of its teeth.

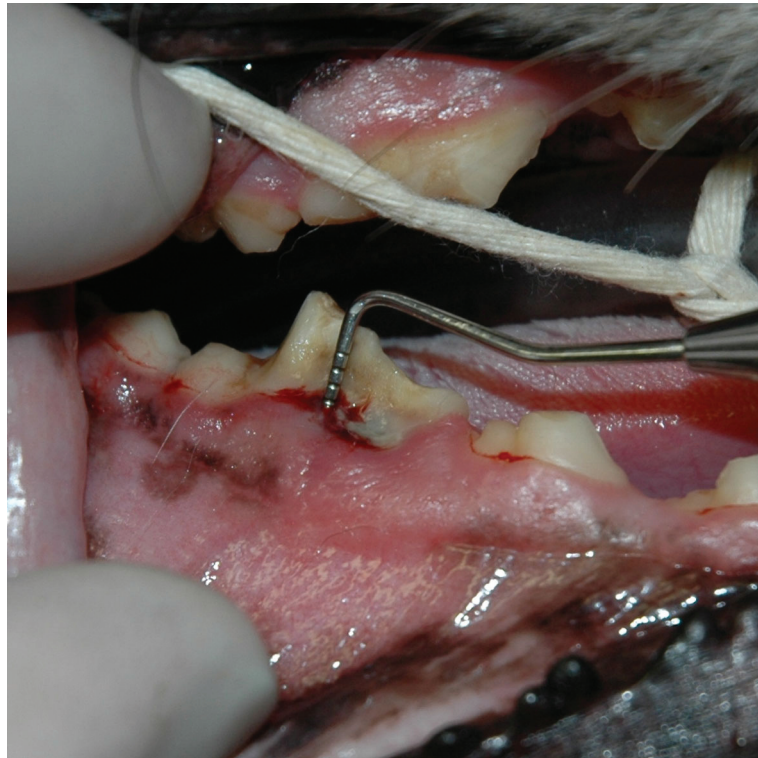

**Figure 5.2** The lateral incisor was damaged and the middle incisor is missing in this patient. There was no history of trauma but these injuries must have occurred before the animal was three months of age judging by the enamel defects on the canine.

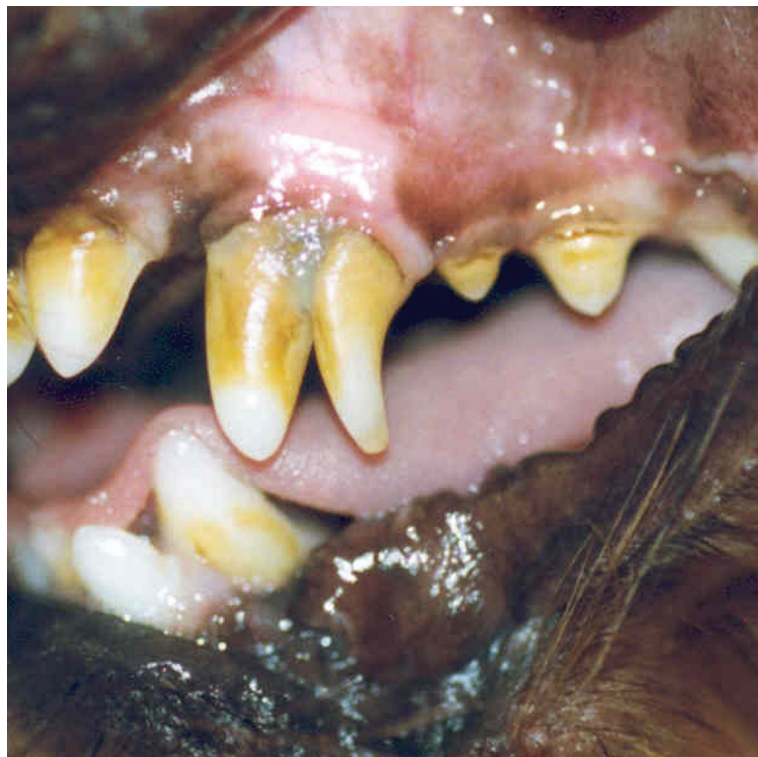

**Figure 5.3** The mandibular right canine and third premolar are fractured with chronic pulp exposure. Restoration and root canal therapy is contraindicated in these teeth, where the fractures extend sub-gingivally.

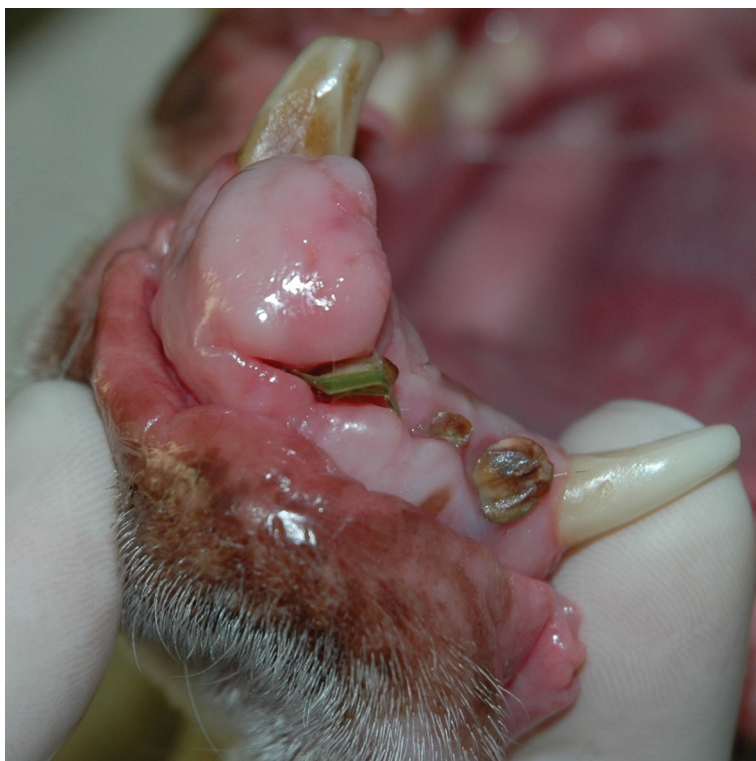## Small Animal Dentistry



**Figure 5.4** This mandibular carnassial tooth had a slab fracture extending sub-gingivally. The periodontal probe indicates a probing depth in excess of about 12 mm (this probe is graduated to 15 mm).



**Figure 5.5** Persistent deciduous canine teeth should be extracted before they compromise the permanent dentition as they have in this case.



**Figure 5.22** Teeth associated with oral tumours are most commonly extracted.

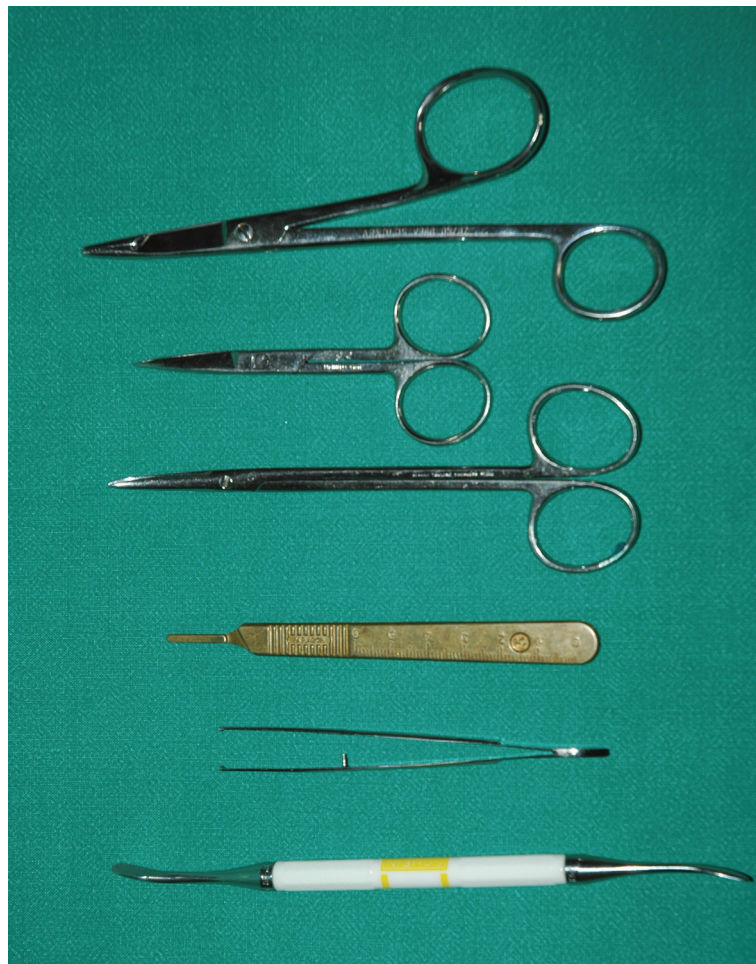### Equipment required

Scalpel blade (15 or 15C) and handle, periosteal elevator, high-or slow-speed handpiece and burs for sectioning teeth and alveoloplasty, dental luxation instruments and elevators, fine rat-toothed forceps, material and surgical scissors, needle holder and monofilament absorbable suture material (Figure 5.23).

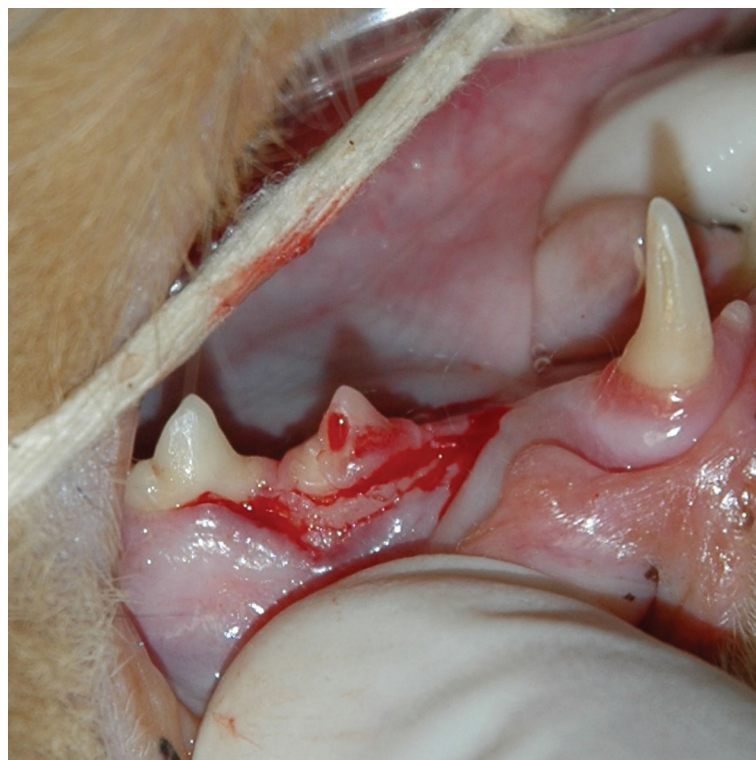
### Planning

Once the diagnosis of dental disease requiring tooth extraction has been made, the procedure must be well planned to prevent subsequent problems. For example, the alveolar buccal bulge of the maxillary canine keeps the upper lip out of the path of the mandibular canine when the mouth is being closed. Occasionally when maxillary canines are extracted and the alveolar buccal bulge is removed the mandibular canine will trap the upper lip resulting in formation of an eosinophilic granuloma or ulcer in cats. This condition is treated by rounding of the mandibular canine tip, crown shortening and sometimes root canal therapy or extraction of the offending tooth. Maintaining the maxillary canine buccal alveolar bulge will prevent this.

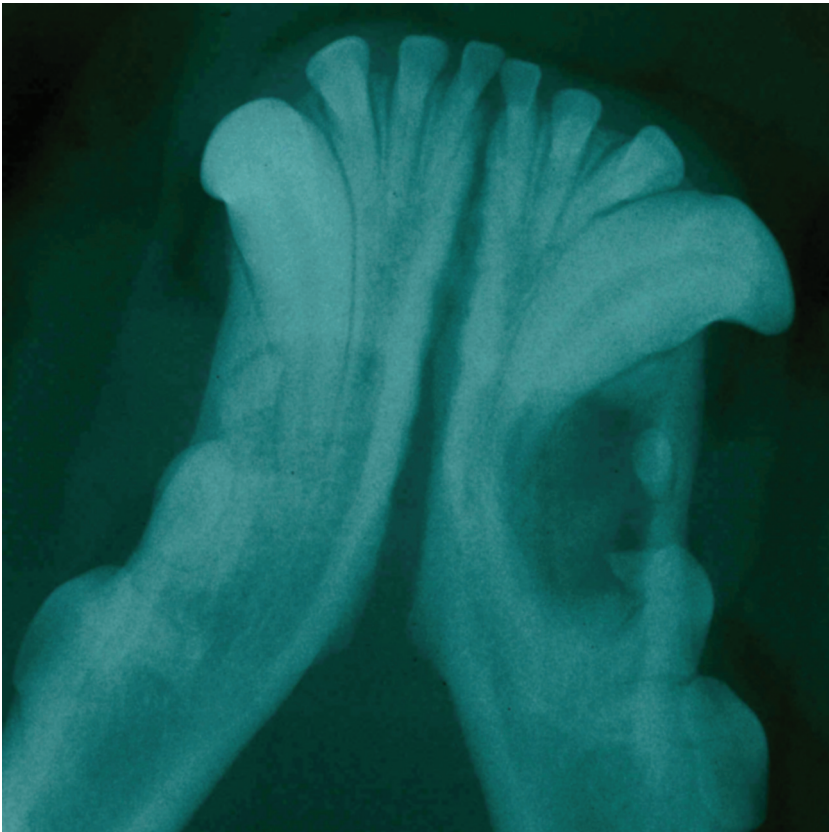
Pre-operative radiographs of the affected teeth are essential, enabling visualisation of the shape, length and presence of roots. If the roots have been completely resorbed and replaced by bone there is no need to create a large flap and remove buccal alveolar bone in order to extract non-existent roots. In these cases the treatment of choice is an envelope flap (Figure 5.24) raised to expose the neck of the tooth, followed by crown amputation and reduction of



**Figure 5.23** A surgical extraction kit should comprise: periosteal elevator, Adson's tissue forceps, No. 3 scalpel handle, Metzenbaum surgical scissors, material scissors and a needle holder.



**Figure 5.24** An envelope flap raised to perform crown amputation extraction technique on a tooth affected by FORL (feline odontoclastic resorptive lesions), the roots of which have undergone replacement resorption.



**Figure 5.25** A dentigerous cyst associated with an unerupted mandibular left premolar 1 in a Boxer dog.

replacement bone to 1 mm below the alveolar margin, and tension-free closure of the flap. Note: if there are root remnants present, this procedure is not indicated and the root remnants must be extracted.

Some teeth have supernumerary roots and unless this was revealed on a pre-operative radiograph the extra root will not be extracted. This can result in development of a root abscess. Radiographs should also be taken of edentulous (toothless) regions to rule out the presence of root remnants and retained (unerupted) teeth. This is especially important in Boxer dogs which appear to be missing premolar 1 in any quadrant. These teeth are often associated with dentigerous cysts which require surgical excision and extraction of the tooth (Figure 5.25). Failure to excise the cyst and extract the tooth may result in fracture of the affected mandible. The tooth and associated tissues must be submitted for histopathological examination to rule out neoplasia.

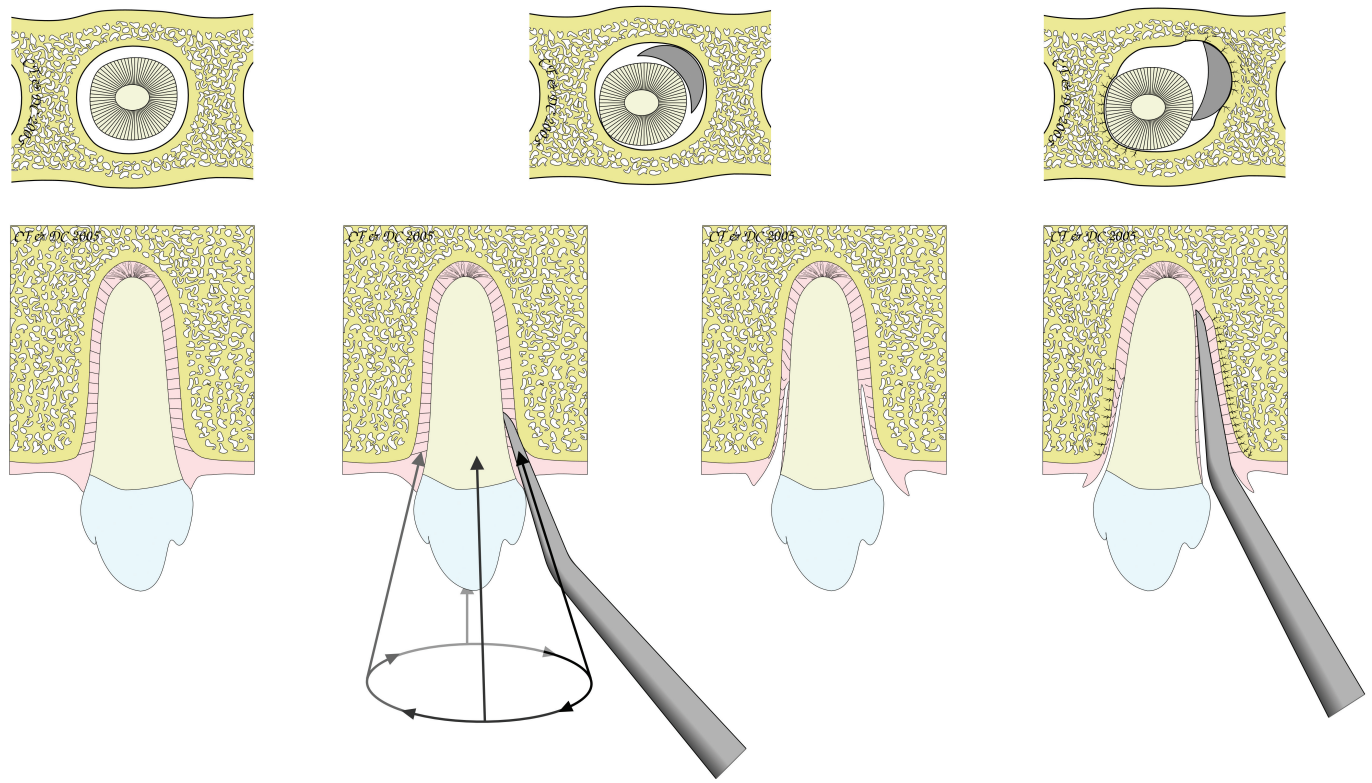
Important structures and areas susceptible to injury must be considered when planning extractions and surgical flaps (Figure 5.26).

Teeth may be extracted by one of two procedures, viz. simple (closed) extraction technique or surgical (open) extraction technique.

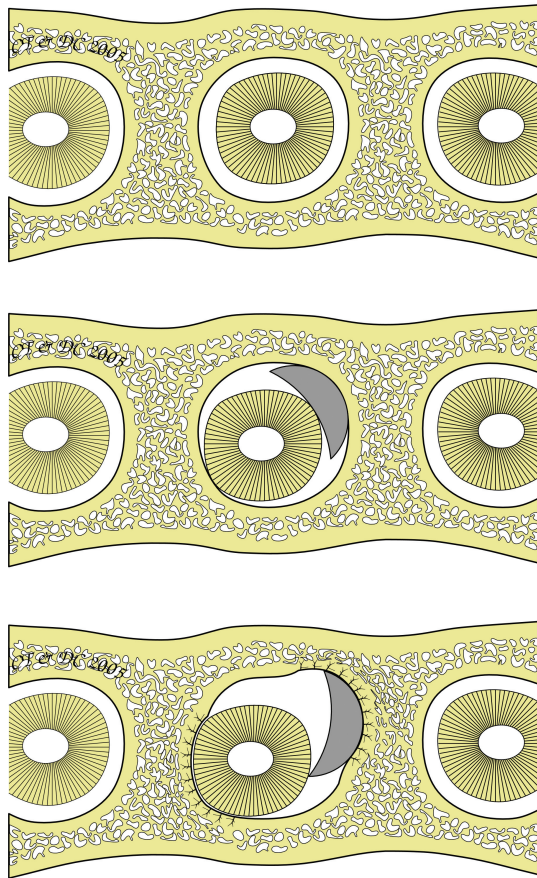
Generally speaking single-rooted teeth and those multi-rooted teeth which are severely periodontally compromised may be extracted using the simple extraction technique.

### The simple (closed) extraction technique

In this technique the tooth is extracted without a surgical flap being raised. A scalpel blade (15 or 15C) is used to sever the gingival attachment by placing

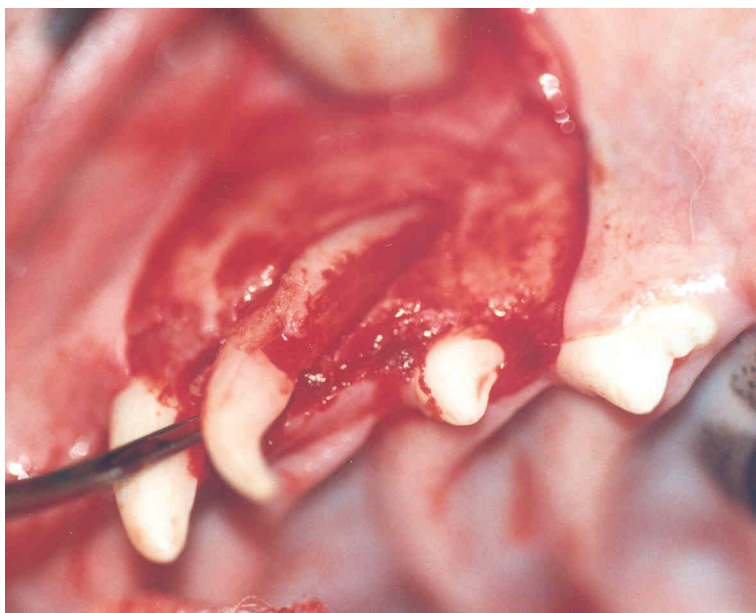


**Figure 5.32** The luxation instrument is used to sever the periodontal ligament circumferentially around the tooth.

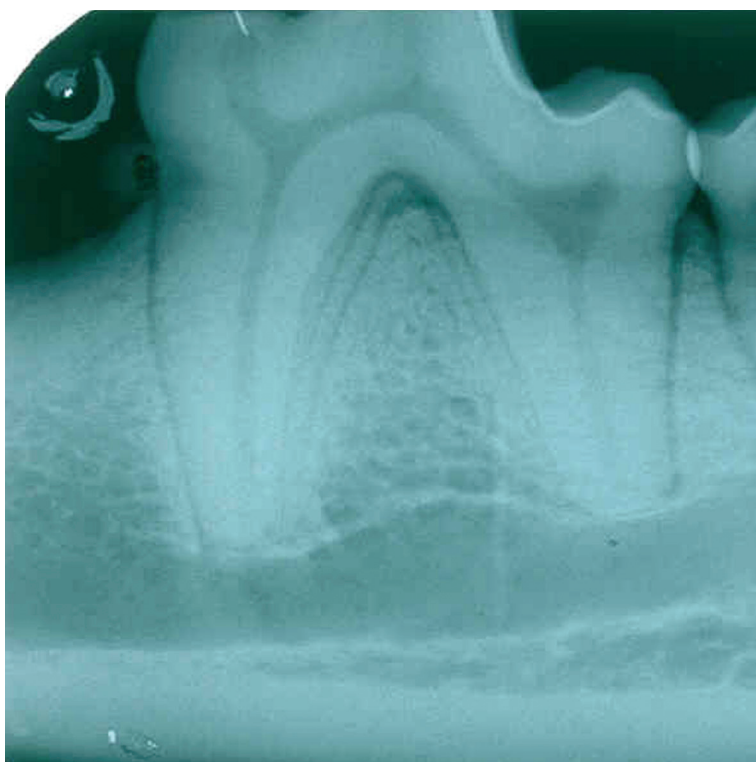


**Figure 5.33** The Luxator® creates space for the elevator to fit into by compressing the alveolar bone.





**Figure 5.68** Do not place a Luxator® between the crowns of the deciduous and permanent teeth as it may cause damage to the enamel organ or mineralising enamel and present as enamel defects or discolouration when the permanent tooth erupts.



**Figure 5.69** The carnassial teeth have longitudinal developmental grooves (distally on the mesial root and mesially on the distal root) which improve anti-rotational stability. These can complicate extraction of these teeth.

### Possible complications associated with extractions

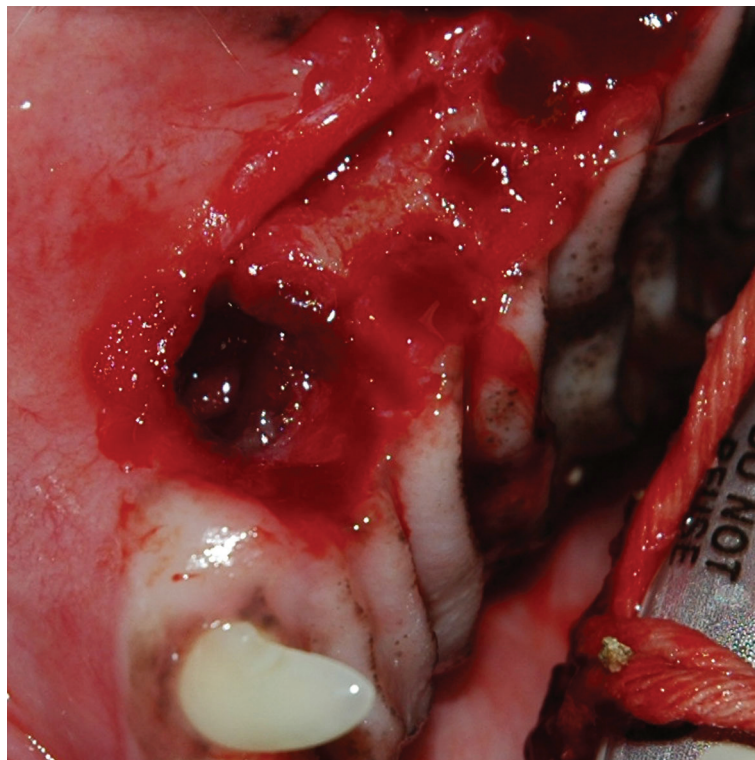
The mandibular molar 1 and maxillary carnassial tooth roots can have a developmental groove running from the furcation to the apex of the root (Figure 5.69). These grooves provide additional anti-rotational support to these teeth and can result in their extraction taking longer than expected.

## Small Animal Dentistry

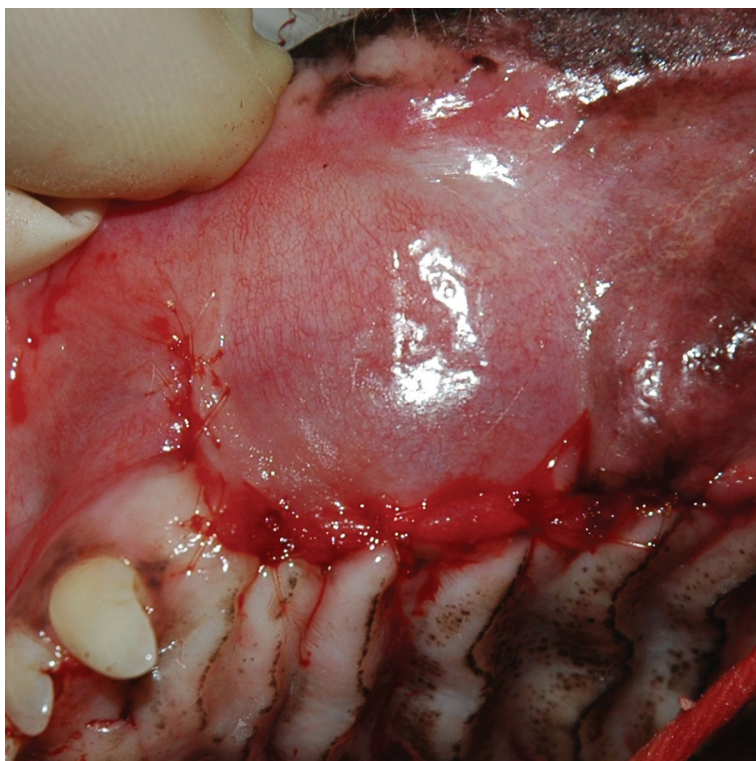
On pre-operative radiographs the developmental groove in a mandibular molar 1 appears as parallel lines at the distal aspect of the mesial root. Removing additional furcation bone will facilitate extraction of these roots.

In geriatric animals the periodontal ligament space is narrower than in young animals and the alveolar bone more dense. This can complicate extraction as access to the periodontal ligament space is limited and the alveolar bone is not easily compressed during luxation and elevation. It is therefore necessary to perform a wider and deeper alveolotomy to create space for the Luxator<sup>®</sup> and elevator. Greater patience is also required to prevent iatrogenic root / crown fractures. It is also advisable to remove more buccal alveolar bone in geriatric animals to expose a greater length of root prior to luxation and elevation. Periodically, roots in geriatric animals may be ankylosed to the alveolus although this may not be readily visible radiographically (because of the two-dimensional view).

Iatrogenic oro–nasal communication often occurs when periodontally compromised maxillary teeth are extracted as a result of bone loss affecting the palatal alveolar wall. Sometimes the only separation between the tooth and the nasal passage is inflamed soft tissue which tears loose during extraction. Bleeding is usually noticed from the ipsilateral nostril. Primary closure of these acute communications is the treatment of choice (Figures 5.70 and 5.71). In some cases it is necessary to debride inflamed epithelialised tissue (pocket wall) from the alveolus before the defect is closed using an advancement flap. See Chapter 7 – Oral Surgery, for details.



**Figure 5.70** A mucoperiosteal flap was raised to extract the maxillary left canine and premolars and an oro-nasal communication resulted at the canine alveolus. The nasal passage was visible through the alveolus.



**Figure 5.71** The acute oro–nasal communication was repaired by tension-free closure of the mucoperiosteal flap and healed uneventfully.

### Further reading

- Crossley, D.A. and Penman, S. (Eds) (1995) *Manual of Small Animal Dentistry*. BSAVA Publications, Cheltenham, UK.
- Holstrom, S.E., Frost P. and Eisner, E.R. (1998) *Veterinary Dental Techniques for the Small Animal Practitioner* (2nd ed). W.B. Saunders Company, Philadelphia.
- Robinson, P.D. (2000) *Tooth Extraction – A Practical Guide*. Elsevier Science Ltd, Edinburgh.
- Wiggs, R.B. and Lobprise, H.B. (1997) *Veterinary Dentistry Principles and Practice*. Lippincott–Raven, Philadelphia.