

Chapter 26.11

Kawasaki Disease

Tomisaku Kawasaki

Kawasaki disease (KD) is an acute febrile mucocutaneous lymph node syndrome with multisystem vasculitis mainly affecting infants and small children less than 5 years of age.

Kawasaki disease is now known to have a worldwide distribution, having been observed on all continents and in all ethnic groups. Although originally believed to be a benign illness, KD is now known to be associated with coronary artery lesions in about 20% of cases. If untreated, patients develop coronary artery changes with a range of severity from asymptomatic coronary artery dilatation or aneurysm to giant coronary artery aneurysms with thrombosis, myocardial infarction and sudden death.

Since the disease was first reported in 1967, significant advances have been made in its clinical, pathological and epidemiological characterization. However, the aetiology, pathogenesis and mechanism of therapeutic effectiveness of intravenous high-dose gammaglobulin (IVGG) in the reduction of coronary artery aneurysm formation remain

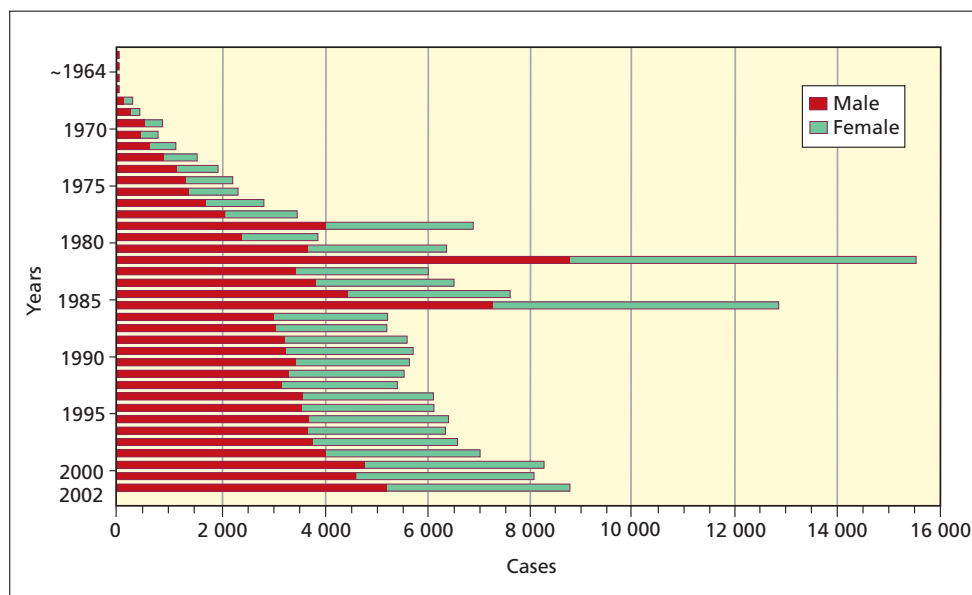
unknown. KD appears now to have replaced acute rheumatic fever as the leading cause of acquired heart disease in children in Japan and the USA.

Epidemiology

By the end of December 2000, 16 nationwide surveys [1–5] of KD had been carried out in Japan and 169 117 patients with KD were registered, the largest number throughout the world. Since about 1970, the incidence of KD has been increasing (Fig. 26.11.1).

In Japan, nationwide epidemics of KD occurred in 1979, 1982 and 1986. There were no epidemics between 1987 and 2002. Since 1987, the annual incidence of KD in Japan has plateaued at 5000–6000. Until 1980 the incidence of KD among children in the general population less than 4 years of age was less than 50 per 100 000. Since then, this figure has steadily increased: between 1981 and 1993 the annual incidence rose to 70–90 per 100 000, between 1994 and 1999 it increased to more than 100, and between 1999 and 2002 the number jumped from 119.6 to 151.2 per 100 000.

Fig 26.11.1 Number of patients with KD registered in Japan by year and sex.



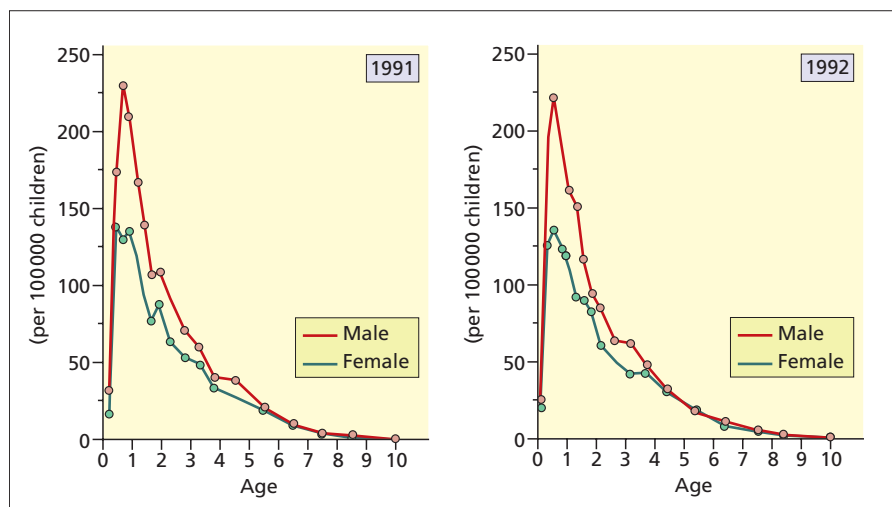


Fig 26.11.2 Incidence of KD in Japan by year and sex.

The average male–female ratio is 1.4:1. The age distribution shows a peak at between 9 and 11 months of age; 50% of affected children are less than 2 years of age and 80% are less than 4 (Fig. 26.11.2). Sibling incidence ranged from 0.7% to 0.9% in the lowest year and between 1.3% and 1.4% in the highest year. The recurrence rate over the past 10 years has been 3–4%. The fatality rate was more than 1% until 1974, but fell to 0.1–0.2% between 1974 and 1993. Between 1994 and 2002, the rate was 0.02–0.09%, with the exception of 1997, when it was 0.14%.

Research in the USA [6,7] has shown that the incidence of KD is highest among children of Asian extraction and lowest among children of Caucasian extraction. Thus, the incidence of KD is low in Europe [8,9]. Reports of KD are more numerous from the more industrialized countries than from the developing countries.

REFERENCES

- 1 Yanagawa H, Nakamura Y, Yashiro M. Results of 16 nationwide surveys of Kawasaki disease in Japan [in Japanese]. *Acta Paediatr Jpn* 2002; 65: 332–42.
- 2 Yanagawa H, Shigematsu I, Kusakawa S *et al.* Epidemiology of Kawasaki disease in Japan. *Acta Paediatr Jpn* 1979; 21: 1–10.
- 3 Yanagawa H, Nakamura Y, Yashiro M *et al.* A nationwide incidence survey of Kawasaki disease in 1985–86 in Japan. *J Infect Dis* 1988; 158: 1296–301.
- 4 Yanagawa H, Kawasaki T, Shigematsu I. Nationwide survey on Kawasaki disease in Japan. *Pediatrics* 1987; 80: 58–62.
- 5 Yanagawa H, Yashiro M, Nakamura Y *et al.* Results of 12 nationwide epidemiological incidence surveys of Kawasaki disease in Japan. *Arch Paediatr Adolesc Med* 1995; 149: 779–83.
- 6 Bell DM, Brink EW, Nitzkin JL *et al.* Kawasaki syndrome: description of two outbreaks in the United States. *N Engl J Med* 1981; 304: 1568–75.
- 7 Taubert KA, Rowley AH, Shulman ST. Nationwide survey of Kawasaki disease and acute rheumatic fever. *J Pediatr* 1991; 119: 279–82.
- 8 Salo E, Pelkonen P, Pettay O. Outbreak of Kawasaki syndrome in Finland. *Acta Paediatr Scand* 1986; 75: 75–80.
- 9 Tizard EJ, Suzuki A, Dillon MJ. Clinical aspects of 100 patients with Kawasaki disease. *Arch Dis Child* 1991; 66: 185–8.

Pathology

The disease follows an acute inflammatory course lasting 4–6 weeks. Features of recurrent angiitis are rare, and

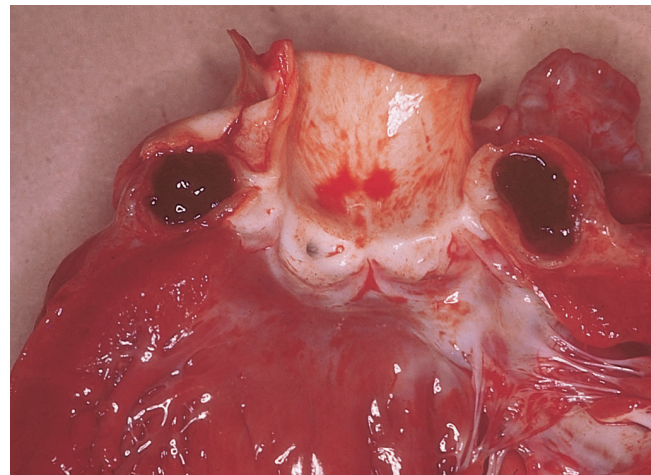


Fig 26.11.3 Autopsy of the heart. Coronary artery aneurysms with thrombosis.

fibrinoid necrosis is mild or hardly ever seen. Coronary aneurysms (Fig. 26.11.3) are present at autopsy in more than 90% of cases [1–3]. In pathological investigations KD can be divided into angiitis and lesions of organs exclusive of vessels.

The course of angiitis can be classified into four stages according to the duration of illness [3].

Stage 1

Stage 1 occurs 1–2 weeks after onset. Characteristic features of stage 1 are acute perivasculitis and vasculitis of the microvessels, such as arterioles, capillaries and venules, and vasculitis of the veins and small arteries including vasa vasorum of the three main coronary arteries. Another feature is inflammation of intima, externa and perivascular areas in the large and medium-sized arteries. There is also oedema and infiltration with leucocytes and lymphocytes. Aneurysm and stenosis are not evident.

Stage 2

Stage 2 occurs 2–4 weeks from onset. One characteristic feature is a reduction in inflammation in the microvessels, small arteries and veins compared with stage 1. Another feature is inflammatory changes of intima, media, externa and perivascular areas in the medium-sized arteries with focal panvasculitis. Aneurysms with thrombi and stenosis can be seen in the medium-sized arteries, especially the coronary arteries. Infiltrating cells include neutrophils, eosinophils, lymphocytes, atypical lymphocytes, plasma cells, monocytes, fibroblasts and fibrocytes. Inflammatory changes of various stages can be seen, from oedema (exudative stage) and cell infiltration with necrosis (infiltrative stage) to cellular granulation with an increase in the number of capillaries.

Stage 3

Stage 3 occurs 4–7 weeks from onset. The characteristic feature is subsidence of inflammation in the microvessels, small arteries and veins. There is granulation in the medium-sized arteries due to masked intimal thickening.

Stage 4

This occurs more than 7 weeks after onset. There is scar formation and intimal thickening with aneurysms, thrombi and stenosis in the medium-sized arteries. In general, there is no acute inflammation in the vessels.

These findings persist until adult age, and have been seen in some autopsied patients 10 years after onset.

Angiitis is divided into three categories:

1 Angiitis in middle-sized and large arteries external to the organs. Arteritis is most frequently seen in the coronary arteries (90%) and iliac artery (17–38%). It is less frequently seen in the mesenteric, renal, main pulmonary, aortic, coeliac, intercostal, subclavian, carotid, hepatic, lumbar, pancreatic and splenic arteries.

2 Angiitis in the arteries in the organs, including the heart, skin, kidneys, tongue, testes, ovaries, gastrointestinal tract, liver, salivary glands, spleen, brain and gall bladder.

3 Angiitis in the veins.

Lesions other than those in the vessels include myocarditis (interstitial myocarditis with mild necrosis) involving the conduction system, pericarditis or endocarditis. Cholecystitis, cholangitis, pancreatic ductitis, sialoadenitis, meningitis and lymphadenitis are frequently observed, and pathological changes can be seen in all of these conditions.

Pathological changes can also be seen in the intestines, liver, pancreas, lungs, bronchi, kidneys, ganglia, spleen, thymus, prostate, fatty tissue and muscle. All of these lesions are frequently seen in stages 1 and 2 but rarely in stage 4.

Ischaemic heart disease occurs in stages 1–4. Acute myocardial infarction may not be histologically detectable

in some autopsied cases. When sudden death cases are autopsied immediately, arterial obstruction can be seen, but myocardial lesions such as necrosis have not yet had time to occur.

Among ischaemic heart disease cases there is fibrosis and/or necrosis of over one-third of the thickness of the left ventricular wall, with marked stenosis or obstruction of the major coronary arteries. These changes are probably due to residual myocardial infarction rather than to myocarditis.

The major causes of death in each stage are as follows. In stage 1, the major cause is myocarditis, including inflammation of the conduction system. In stages 2 and 3, the major causes are ischaemic heart disease, rupture of an aneurysm and myocarditis. In stage 4, the major cause is ischaemic heart disease.

Arterial lesions were categorized by Amano *et al.* [4], according to the degree of inflammatory change and to the duration of the disease. Six characteristic types of lesions were identified in the arterial system: (a) degeneration of the endothelial cells; (b) oedema and degeneration of the media; (c) necrotizing panarteritis; (d) granulation formation; (e) scar formation; and (f) aneurysm formation. Amano *et al.* [5] observed the above as a pathological feature of KD. The six types of arteritis changes were not equally distributed throughout the entire arterial system. Typically these six types of lesions were simultaneously observed not only in various areas of the arterial tree in the same patient but also in different portions of one artery.

In America, Landing and Larson [6,7] suggested that there were ‘early’ and ‘late’ stages of arterial lesions found in autopsies of patients dying at various time intervals after clinical onset of their acute KD. It is thought that Fujiwara and Hamashima’s stages [3] can also be divided into ‘early’ and ‘late’; stages 1 and 2 could be ‘early’ and stages 3 and 4 could be ‘late’. The types observed by Amano *et al.* could also be thought of in terms of stages. Types (a), (b), (c) and (f) would be ‘early’, whereas types (d) and (e) would be ‘late’.

Landing and Larson [7] pointed out that there was a surprisingly high incidence of ‘late-stage’ arterial lesions in patients dying within 2 weeks of onset of clinical acute KD. They also pointed out that there was a possible increase in frequency of early-stage arterial lesions in patients dying within 10–12 weeks of the onset of the acute disease. In addition, they noted that rarely late-stage aneurysms of the arteries could be detected in patients with no history of an acute phase of disease. Landing and Larson [7] suggested that there may be several patterns of clinical features and pathological features in KD:

1 a single ‘peak’ of acute clinical disease and of lesions, with subsequent regression/healing (including scarring) of injured tissues/organs;

2 an acute phase of illness followed by a period of clinical improvement (‘convalescence’) and then a second phase of acute illness (the two-peak or ‘camel back’ course).

3 an episode of clinically evident acute disease, followed by a clinically unapparent phase of continued or increased injury of the arteries;

4 a clinically unrecognized or unrecognizable first phase of disease followed by a clinically more overt 'second wave' of disease activity;

5 a single peak of clinically unapparent disease or two peaks of disease activity, neither clinically appreciated.

Landing and Larson combined pathological findings and considerations of the clinical cause in order to establish their five categories. Their hypothesis can be of use for both clinicians and pathologists.

REFERENCES

- 1 Tanaka N. Kawasaki disease (acute febrile infantile mucocutaneous lymph node syndrome) in Japan: relationship with infantile periarteritis nodosa. *Pathol Microbiol* 1975; 43: 204–18.
- 2 Tanaka N, Sekimoto K, Naoe S. Kawasaki disease: relationship with infantile periarteritis nodosa. *Arch Pathol Lab Med* 1976; 100: 81–6.
- 3 Fujiwara H, Hamashima Y. Pathology of the heart in Kawasaki disease. *Pediatrics* 1978; 61: 100–7.
- 4 Amano S, Hazama F, Hamashima Y. Pathology of Kawasaki disease. 1. Pathology and morphogenesis of the vascular changes. *Jpn Circ J* 1979; 43: 633–43.
- 5 Amano S, Hazama F, Hamashima Y. Pathology of Kawasaki disease. 2. Distribution and incidence of the vascular lesions. *Jpn Circ J* 1979; 43: 741–8.
- 6 Landing BH, Larson EJ. Are infantile periarteritis nodosa with coronary artery involvement and fatal mucocutaneous lymph node syndrome the same? Comparison of 20 patients from North America with patients from Hawaii and Japan. *Pediatrics* 1977; 59: 651–62.
- 7 Landing BH, Larson EJ. Pathological features of Kawasaki disease (mucocutaneous lymph node syndrome). *Am J Cardiovasc Pathol* 1987; 1: 215–29.

The pattern of clinical course in relation to the pathological features

A small but significant fraction of patients with acute KD show exacerbation or recrudescence of signs and symptoms during the subacute or convalescent phase of the disease, within a few to several weeks after initial clinical onset. These patients, who show a 'camel back' clinical course, have a poorer prognosis than patients who show only a single-peak course [1–3].

REFERENCES

- 1 Kawasaki T, Kubo N, Sakata G *et al.* Two autopsy cases of infantile polyarteritis nodosa and their clinical findings: in relation to Kawasaki disease. Part 1 [in Japanese]. *Chiryō J Ther* 1970; 52: 633–44.
- 2 Kawasaki T, Kubo N, Sakata G *et al.* Two autopsy cases of infantile polyarteritis nodosa and their clinical findings: in relation to Kawasaki disease. Part 2 [in Japanese]. *Chiryō J Ther* 1970; 52: 811–18.
- 3 Landing BH, Larson EJ. Pathological features of Kawasaki disease (mucocutaneous lymph node syndrome). *Am J Cardiovasc Pathol* 1987; 1: 215–29.

Immunopathology of the skin lesion of Kawasaki disease

In the acute phase of KD, within 5 days after onset, more than 90% of patients develop polymorphous exanthemata

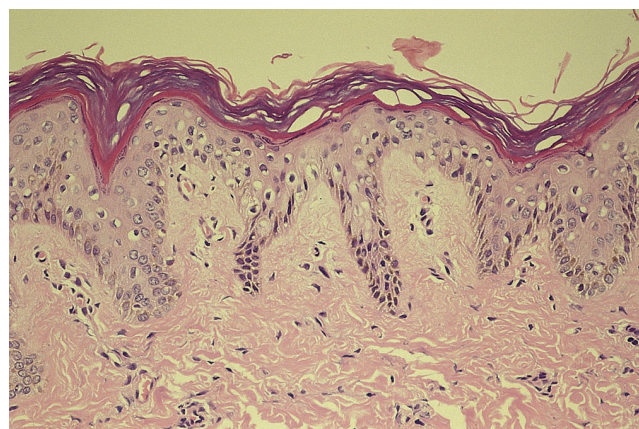


Fig 26.11.4 Skin histology (of erythema), showing a sparse mononuclear cell infiltrate in the papillary dermis around small dilated blood vessels.

on the body trunk or extremities. The most common form of rash is a generalized urticaria-like erythema with large, irregular plaques. The second most common form is a maculopapular morbilliform erythema. In rare cases, the rash is scarlatiniform erythroderma that is similar to erythema marginatum in character or multiforme-like with iris lesions.

Histopathologically, the lesion (Fig. 26.11.4) reveals marked oedema of dermal papillae, focal intercellular oedema of the basal cell layer and very slight perivascular infiltration of mononuclear cells in the papillary dermis, with the dilatation of small vessels [1,2].

Immunopathologically [3], most of the infiltrates are CD4⁺ T lymphocytes and CD13⁺ macrophages. There are few CD8⁺ T lymphocytes. The expression of the DR locus of human leucocyte antigen is detected not only on the epidermal keratinocyte surface but also on the walls of the small blood vessels and the infiltrating cells around these blood vessels. There are no CD20⁺ B lymphocytes.

Sato *et al.* [4] used four monoclonal antibodies against cytokines: anti-interferon- γ (IFN- γ) and anti-interleukin 2 (IL-2), anti-IL-1 α and anti-TNF- α . As a result, they suggest that (a) IL-1 α and TNF- α are strongly positive in all patients with acute KD; and (b) IL-2 and IFN- α are weakly or partially positive. No cytokines were detected in the convalescent phase. They concluded that IL-1 α and TNF- α may be involved in the pathogenesis of the inflammation of skin in acute KD.

REFERENCES

- 1 Hirose S, Hamashima Y. Morphological observations on the vasculitis in the mucocutaneous lymph node syndrome. A skin biopsy study of 27 patients. *Eur J Pediatr* 1978; 129: 17–27.
- 2 Kawasaki T. Skin lesion of Kawasaki syndrome. In: Urabe H, ed. *Proceedings of the 4th International Pediatric Dermatology*. Tokyo: University of Tokyo Press, 1986: 51–2.
- 3 Sugawara T, Furukawa S, Yabuta K *et al.* Immunopathology of the skin

lesions of Kawasaki disease. In: Shulman ST, ed. *Kawasaki Disease*, New York: A. R. Liss, 1987: 185–92.

4 Sato N, Sagawa K, Sasaguri Y *et al.* Immunopathology and cytokine detection in the skin lesions of patients with Kawasaki disease. *J Pediatr* 1993; 122: 198–203.

Superantigen: aetiological agent of Kawasaki disease?

Table 26.11.1 compares scarlet fever, toxic shock syndrome (TSS) and KD. These three diseases share similar features but there are important differences. The skin rash in scarlet fever is red, punctate, diffuse or finely papular erythema. The TSS rash is diffuse, macular erythroderma; during the state of shock, the erythroderma fades. In KD, the rash is polymorphous, as discussed above.

It has been suggested that superantigens may play an important role in the aetiology of KD. Abe *et al.* [1,2] and Leung *et al.* [3] have suggested that TSS toxin type 1 (TSST-1), streptococcal pyogenic exotoxin (SPE) B and C are the aetiological superantigens of KD. TSST-1 is the aetiological agent of TSS, and SPE-A, SPE-B and SPE-C [4] are the aetiological agents of scarlet fever.

Leung’s group base their hypothesis on the expansion of T-cell receptors’ (TCRs) Vβ regions, so Leung’s group suggests that a kind of superantigen is the aetiological agent of KD. However, some other researchers [5–8] have recently reported that the TCR Vβ region does not always expand during the acute stage of KD. Thus, whether or not superantigens are the aetiological agents of KD remains controversial.

REFERENCES

1 Abe J, Kotzin BL, Jujo K *et al.* Selective expansion of T cells expressing T-cell receptor variable regions Vβ2 and Vβ8 in Kawasaki disease. *Proc Natl Acad Sci USA* 1992; 89: 4066–70.
 2 Abe J, Kotzin BL, Meissner C *et al.* Characterization of T cell repertoire changes in acute Kawasaki disease. *J Exp Med* 1993; 177: 791–6.
 3 Leung DYM, Meissner HC, Fulton DR *et al.* Toxic shock syndrome toxin-secreting *Staphylococcus aureus* in Kawasaki disease. *Lancet* 1993; 342: 1385–8.
 4 Abe J, Forrester J, Nakahara T *et al.* Selective stimulation of human T cells with streptococcal erythrogenic toxins A and B. *J Immunol* 1991; 146: 3747–50.
 5 Melish ME, Parsonett J, Marchette N. Kawasaki syndrome is not caused by toxic shock syndrome toxin 1 staphylococci [Abstract]. *Pediatr Res* 1994; 35: 187A.

6 Pietra BA, De Inocencio J, Giannini EH *et al.* TCR Vβ family repertoire and T-cell activation markers in Kawasaki disease. *J Immunol* 1994; 153: 1881–8.
 7 Terai M, Miwa K, Williams T *et al.* The absence of evidence of staphylococcal toxin involvement in the pathogenesis of Kawasaki disease. *J Infect Dis* 1995; 172: 558–61.
 8 Sakaguchi M, Kato H, Nishiyori A *et al.* Characterization of CD4+ T-helper cells in patients with Kawasaki disease: preferential production of tumor necrosis factor-alpha by Vβ2- or Vβ8- CD4+ T-helper cells. *Clin Exp Immunol* 1995; 99: 276–82.

Clinical features and diagnosis [1–7]

In the absence of a diagnostic test for KD, the diagnosis is established by the presence of six principal symptoms [3] (Table 26.11.2):

1 Fever of unknown aetiology persisting for 5 days or more. In general, the patient has remittent or continuous fever ranging from 38°C to 40°C but with no prodromal symptoms such as coughing, sneezing or rhinorrhoea. The duration of fever is usually 1–2 weeks in untreated patients. The fever subsides more rapidly when IVGG is administered with aspirin compared with therapy with aspirin alone. In KD, the longer the fever continues, the higher the possibility of coronary artery aneurysms. If fever continues for 10 days or more, severe coronary artery lesions are liable to remain. If fever of unknown origin continues for 1 week to 10 days or longer, and if one or two of the principal symptoms are present, then

Table 26.11.2 Diagnostic guidelines for KD.

- Fever persisting for at least 5 days
- Changes in peripheral extremities:
 - Initial stage: reddening of palms and soles, indurative oedema
 - Convalescent stage: membranous desquamation from fingertips
- Polymorphous exanthema
- Bilateral conjunctival congestion
- Changes in the lips and oral cavity: reddening of lips, strawberry tongue, diffuse injection of oral and pharyngeal mucosa
- Acute non-purulent cervical lymphadenopathy

At least five principal symptoms should be satisfied for the diagnosis of KD. However, patients with four of the principal symptoms can be diagnosed as having KD when coronary aneurysm is recognized by two-dimensional echocardiography or coronary angiography.

Table 26.11.1 Comparison of scarlet fever, TSS and KD.

	Scarlet fever	TSS	KD
Nature of rash	Diffuse, erythema (red punctate or finely papular)	Diffuse, macular erythroderma	Polymorphous erythema
Conjunctival hyperaemia	–	?	?
Erythema of the oral mucosa	–	?	?
Strawberry tongue	?	?	?
Hypotension or shock	–	?	–
Desquamation from fingertips	?	?	?
Aetiological agent	Group A <i>Streptococcus</i> , SPE-A, SPE-B, SPE-C	<i>Staphylococcus aureus</i> , TSST-1	?
Age	> 3 years old	All ages	< 5 years old
Recurrence	Rare	30%	3–4%

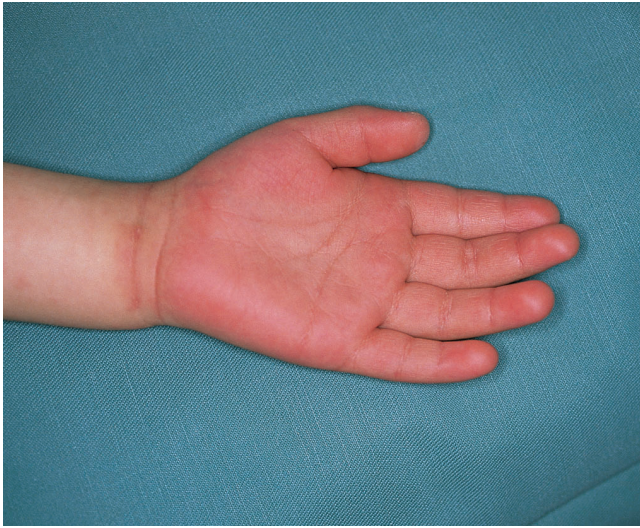

Fig 26.11.5 Palmar erythema.

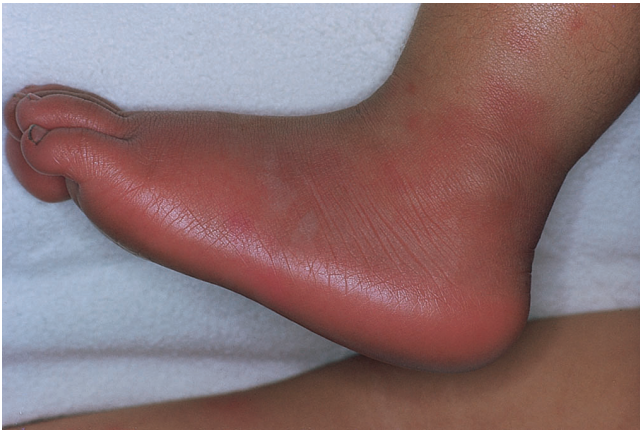

Fig 26.11.6 Erythema of the sole of the foot.

atypical KD can be assumed and IVGG treatment should be considered.

2 Changes in peripheral extremities. The findings on the hands and feet in KD are distinctive. Within 5 days of onset, erythema of the palms and soles (Fig. 26.11.5) and/or indurative oedema of the hands and feet (Fig. 26.11.6) occur. Sometimes the degree of swelling is great and the skin is shiny and looks as though it is about to burst. After the fever subsides, erythema and swelling disappear in most cases. From 10 to 15 days after the onset, there is fissuring between the nails and the tips of the fingers (Fig. 26.11.7), after which membranous desquamation spreads over the palm up to the wrist in many cases.

3 Polymorphous erythema. From the first to the fifth day after the onset of fever, polymorphous erythema (Fig. 26.11.8) appears on the body and/or extremities. The exanthema can present in many forms: an urticarial exanthema with large erythematous plaques, a morbilliform maculopapular rash or, in rare cases, erythema multiforme-

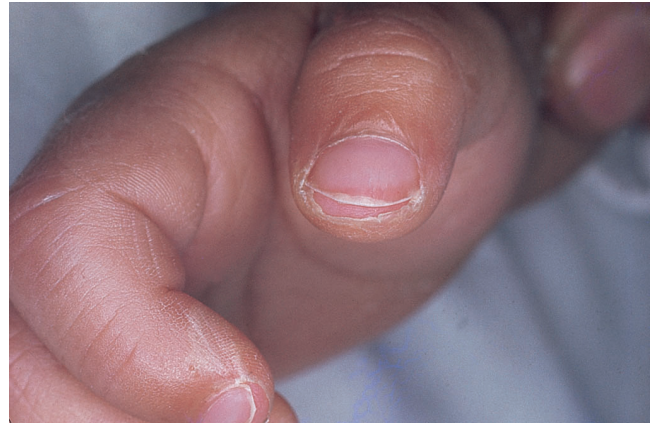

Fig 26.11.7 Desquamation of the fingertips.

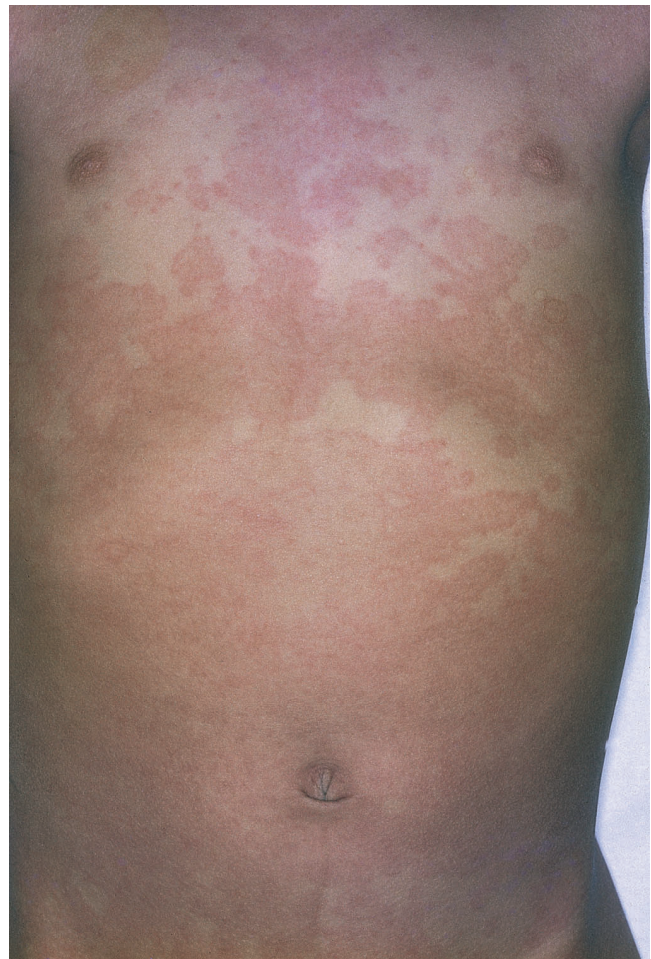

Fig 26.11.8 Polymorphous erythematous rash.

like with central clearing or iris lesions. In each case, the exanthema is a different combination of these forms. Each lesion becomes increasingly large, and often lesions coalesce. If the rash shows scarlatiniform erythroderma, careful differentiation is necessary between KD and scarlet

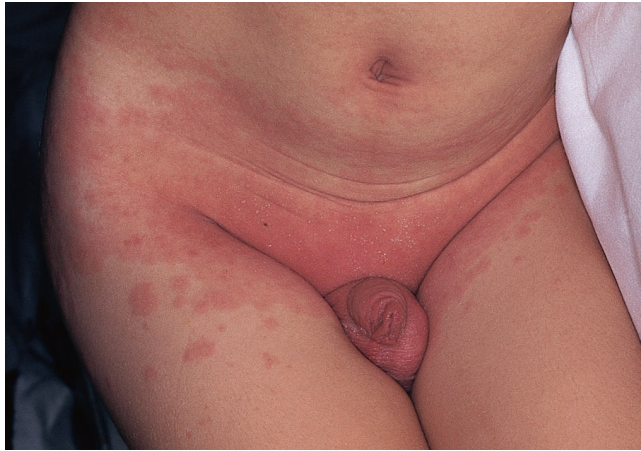

Fig 26.11.9 Diffuse erythema with small aseptic pustules.

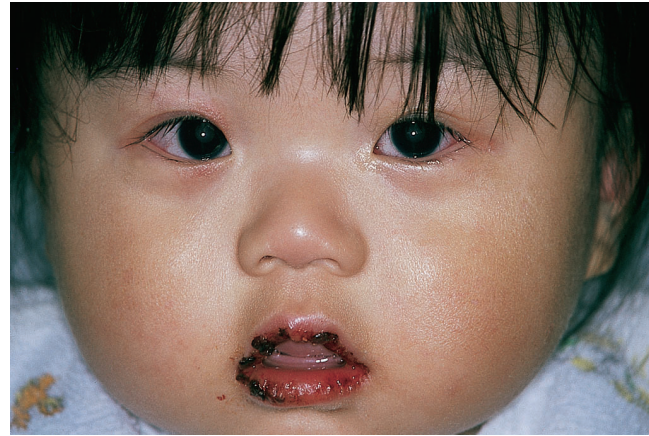


Fig 26.11.11 Typical appearance of acute KD: redness, dryness and bleeding of the lips with bilateral conjunctival hyperaemia.

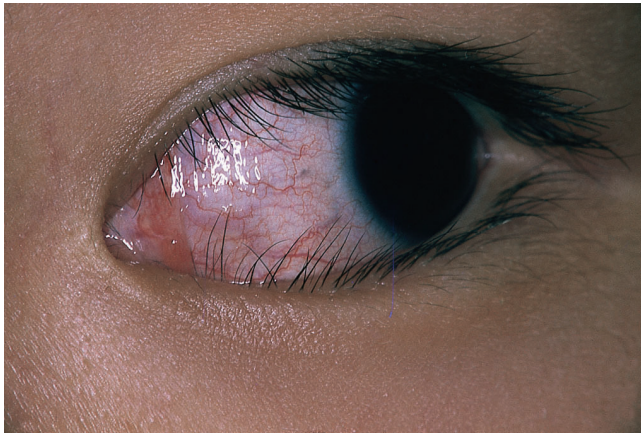


Fig 26.11.10 Conjunctival injection, no exudate.

fever or TSS [7] (Table 26.11.1). There is no vesicle or bullae formation except at the bacille Calmette–Guérin (BCG) inoculation site. However, about 5% of patients show small aseptic pustules on the knees, buttocks or other body sites (Fig. 26.11.9). Desquamation may occur in the perineal region as well as on the hands and feet.

4 Bilateral injection of ocular conjunctivae. Within 2–4 days of onset, conjunctival injection develops (Fig. 26.11.10). It is not associated with exudate. Each capillary vessel is clear because of individual capillary dilatation; careful slit-lamp examination early in the course of the disease may reveal anterior uveitis. Conjunctival injection usually subsides within 1–2 weeks but sometimes continues for more than a few weeks. With IVGG treatment, conjunctival injection may improve quickly following treatment.

5 Changes in lips and oral cavity. Changes in lips and oral cavity are characterized by redness, dryness, fissuring, peeling and bleeding of the lips, diffuse erythema of the oropharyngeal mucosa, strawberry tongue without pseudomembrane formation, aphthae or ulcerations. Redness of the lips may often continue for 2–3 weeks after the

disappearance of other symptoms. Bilateral injection of the eyes together with changes in the lips combine to give the characteristic appearance of KD (Fig. 26.11.11). This appearance can be an important aid to diagnosis.

6 Acute non-purulent cervical adenopathy. Cervical adenopathy is seen in less than 50% of KD patients in the USA and 60–70% in Japan, whereas the other principal symptoms are each observed in 90% or more of all patients. The size of the swelling ranges from 1.5 to 5 cm in diameter and is always a firm, non-fluctuant and painful mass (Fig. 26.11.12). The nodes are unilateral or bilateral and may be misdiagnosed as mumps. In some patients cervical lymph node adenopathy is the most striking clinical symptom of KD, appearing 1 day before the onset of fever or together with fever.

If five or six of the principal symptoms are present, a diagnosis of KD can be made. However, patients with only four of the principal symptoms can be diagnosed as having KD when coronary aneurysm is recognized by two-dimensional echocardiography or coronary angiography (Table 26.11.2).

REFERENCES

- 1 Kawasaki T. Febrile oculo-oro-cutaneo-acrodesquamatos syndrome with or without acute non-suppurative cervical lymphadenitis in infancy and childhood: clinical observations of 50 cases [in Japanese]. *Jpn J Allerg* 1967; 16: 178–222.
- 2 Kawasaki T, Kosaki F, Okawa S *et al.* A new infantile acute febrile mucocutaneous lymph node syndrome (MCLS) prevailing in Japan. *Pediatrics* 1974; 54: 271–6.
- 3 Kawasaki T. Clinical features of Kawasaki syndrome. *Acta Paediatr Jpn* 1983; 25: 79–90 [overseas edition].
- 4 Melish ME, Hicks RV, Larson EJ. Mucocutaneous lymph node syndrome in the United States. *Am J Dis Child* 1976; 130: 599–607.
- 5 Melish ME. Kawasaki syndrome (the mucocutaneous lymph node syndrome). *Am Rev Med* 1982; 33: 569–85.
- 6 Hicks RV, Melish ME. Kawasaki syndrome. *Pediatr Clin N Am* 1986; 35: 1151–75.
- 7 Behrman RE, Kliegman R, eds. *Nelson Essentials of Pediatrics*. Philadelphia W.B. Saunders, 1990.

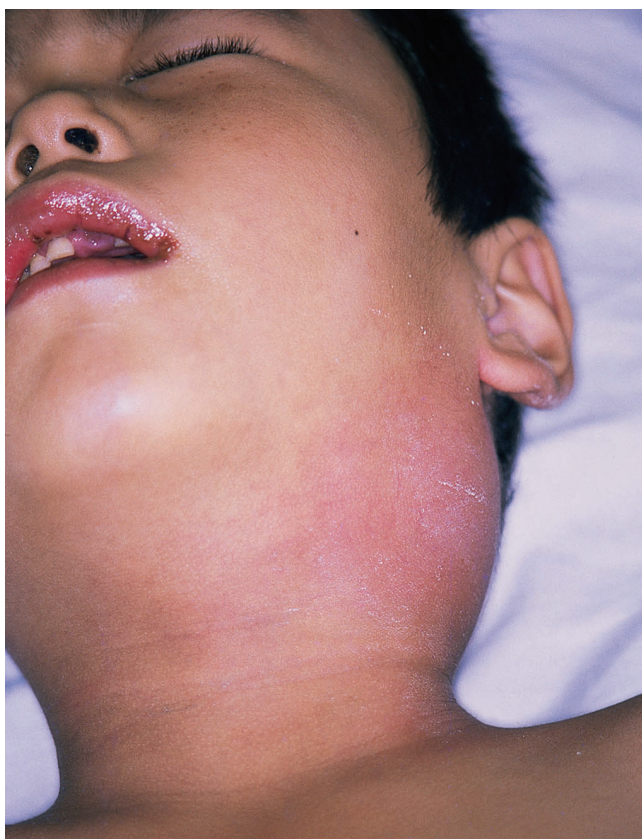

Fig 26.11.12 Huge cervical lymphadenopathy.

Atypical cases

It is said that there are no cases without exceptions, and the same can be said about KD. Diagnosis is easy in typical cases, but atypical cases are sometimes difficult for clinicians.

Kawasaki disease can be considered to form a spectrum, with, at one end, patients who exhibit all six principal symptoms and, at the other end, patients with none of the six symptoms. Atypical KD patients with coronary complications that are either fatal or with remaining aneurysms do occur, and these are difficult cases to diagnose [1–3].

Prolonged fever is one symptom that occurs in atypical cases. Consequently, in a patient with fever of unknown origin, a diagnosis of KD should always be considered. In such patients, especially infants and small children, fingertip desquamation, even in the absence of the other principal symptoms, is a strong indicator of KD. Mild conjunctival injection with prolonged fever can also be a manifestation of KD, and possible coronary complications should be investigated by two-dimensional echocardiography. A third atypical presentation that strongly suggests KD is pallor and red lips in association with prolonged fever.

Prolonged fever in combination with any one of the principal symptoms should suggest KD and prompt careful investigation for coronary complications [4].

It is to be hoped that the aetiology of KD will be resolved and that early diagnosis will be possible; this is likely if the aetiological agent turns out to be a microorganism. Until then, we must rely on diagnosis from the presenting symptoms, and in atypical cases the guidelines outlined above should be followed (Table 26.11.2).

REFERENCES

- 1 Fukushima J, Nihill MR, McNamara DG. Spectrum of cardiovascular lesions in mucocutaneous lymph node syndrome: analysis of eight cases. *Am J Cardiol* 1980; 45: 98–107.
- 2 Rowley AH, Gonzalez-Crussi F, Gidding SS *et al*. Incomplete Kawasaki disease with coronary artery involvement. In: Shulman ST, ed. *Kawasaki Disease*. New York: A. R. Liss, 1987: 357–65.
- 3 Sonobe T, Kawasaki T. Atypical Kawasaki disease. In: Shulman ST, ed. *Kawasaki Disease*. New York: A. R. Liss, 1987: 367–78.
- 4 Kawasaki T. Comment and discussion: atypical cases. In: Kawasaki T, Shigematsu I, Yanagawa H. *Proceedings of the Third International Kawasaki Disease Symposium*. Tokyo: Japan Heart Foundation, 1988: 294.

Laboratory findings

There are no specific and no diagnostic laboratory findings in KD. A moderate to marked leucocytosis with a shift to the left, elevation of the erythrocyte sedimentation rate and positive C-reactive protein (CRP) are common. CRP is a globulin that forms a precipitate with the C-polysaccharide of the pneumococcus. The thrombocytosis that occurs in the acute phase of KD ranges from 50×10^4 to 150×10^4 and begins to rise in the second week, peaking at about 3 weeks, but persists for several months after onset in some cases. This thrombocytosis is a minor characteristic feature in KD [1]. Aseptic microscopic pyuria is frequently seen in the acute phase in KD and almost always disappears in the convalescent phase.

Immunoregulatory abnormalities, such as imbalance of T-cell population, polyclonal B-cell activation, activated monocytes/macrophages and increased cytokines such as TNF- α , IF- γ , IL-1, IL-2, IL-6, IL-2 receptors and intercellular adhesion molecule type 1 (ICAM-1), also occur. However, these cytokines are present in many other disease states that are not associated with the development of arteritis. It therefore appears that 'cytokine activation must act in concert with some other unknown mediator(s) of vascular injury' [2]. The implications of the described immune abnormalities and cytokine activation for the pathogenesis and treatment of KD are unclear [3].

REFERENCES

- 1 Kawasaki T. Clinical features of Kawasaki syndrome. *Acta Paediatr Jpn* 1983; 25: 79–90 [overseas edition].
- 2 Rowley AH, Gonzalez-Crussi F, Shulman ST. Kawasaki syndrome. *Curr Prob Paediatr* 1991; 21: 387–415.

3 Terai M, Shulman ST. Immunological features of Kawasaki disease: controversial issues. *Clin Immunol News* 1995; 15: 93–6.

Cardiovascular complications

The most important clinical problem in KD is cardiovascular lesions, which may cause sudden death or develop into coronary artery disease [1,2].

In the early phase of the illness, pericarditis, myocarditis, endocarditis and coronary arteritis are present and exhibit mild to severe manifestations in most KD patients. The earliest manifestations occur within 10 days of onset and include myocarditis, occasionally with congestive failure, manifested by severe tachycardia and gallop rhythm and/or distant heart sounds, severe arrhythmia rarely leading to cardiac arrest, pericarditis with effusion and mitral and/or aortic regurgitation. Electrocardiographic changes show flattening and depression of the ST segment, flattening or inversion of the T wave, decreased voltage and conduction disturbances, including heart block.

In Japan, between 1979 and 1982, both two-dimensional echocardiography and coronary angiography were performed just after the acute stage of the illness. Since 1983, patients have undergone two-dimensional echocardiography, which has become the most useful non-invasive method of evaluating coronary aneurysms. Patients found to have medium-sized to large aneurysms have undergone coronary angiography.

From studies involving daily echocardiography, Hirose *et al.* [3] documented increasing echodensity of the coronary artery wall as early as 7 days after the onset of fever in all patients tested. They also demonstrated that coronary dilatation is first detected after, on average, 10 days of illness and that the peak frequency of coronary dilatation or aneurysm occurs within 3 weeks of onset. The development of echocardiographic coronary artery abnormalities after 4 weeks is rare. Kohata *et al.* [4] reported that myocardial imaging with thallium-201 (^{201}Tl) seemed to be more sensitive than stress electrocardiography by treadmill in detecting myocardial ischaemia in patients with coronary obstructive lesion after KD. Kondo *et al.* [5] reported that ^{201}Tl myocardial single-photon emission computerized tomography (SPECT) after dipyridamole infusion is a safe and accurate diagnostic method for identifying coronary stenosis in KD patients. The fate of coronary aneurysms in KD was well described by Kato *et al.* [6]. At 1–5 months after the onset of KD, 18.7% of all patients in this study had angiographic evidence of coronary aneurysms. Repeat angiography 5–18 months later in those with abnormalities showed that regression of the aneurysms occurred within 2 years of onset in about 57% of patients. Among those in whom abnormalities persisted, in one-third the aneurysms disappeared but complete obstruction or marked stenosis of

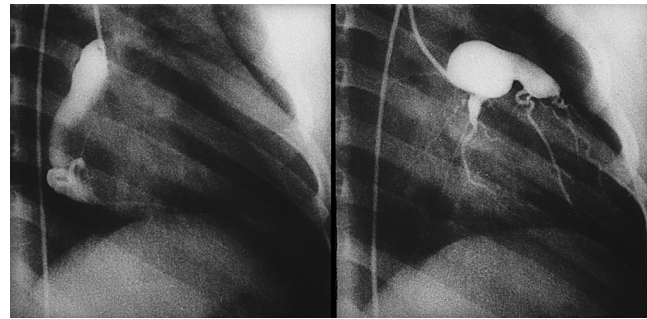


Fig 26.11.13 Right and left giant coronary aneurysms.

the coronary arteries developed, and in the remainder fine irregularities of the coronary arterial walls without stenosis occurred. If thrombi form in aneurysms, they may increase in size over time and may result in occlusions. It is clear that coronary artery aneurysms, especially giant aneurysms (Fig. 26.11.13), may result in stenosis of the vessels, and that stenosis often leads to significant coronary obstruction and myocardial ischaemia. Kamiya [7] published diagnostic criteria for cardiovascular lesions in KD in English. This work was the first to standardize coronary artery lesions in KD worldwide.

Based on Kamiya's work, Nakano *et al.* [8] proposed the following quantitative grading system for coronary aneurysms:

- grade 0: normal;
- grade 1: less than 4 mm in diameter (mild);
- grade 2: between 4.0 and 8.0 mm in diameter (moderate);
- grade 3: greater than 8.0 mm in diameter (severe; giant).

Nakano *et al.* believed that this system could be useful in determining the prognosis of patients with KD.

Kato *et al.* [9] analysed clinical data from 195 KD patients with myocardial infarction. They found that two-thirds of myocardial infarctions in KD patients occurred within the first year of illness. In more than 60% of patients, myocardial infarction occurred during sleep or at rest. One-third of the myocardial infarctions in KD patients were asymptomatic. In survivors (about 80% patients survived the first heart attack), one-vessel obstruction was frequently identified, particularly in the right coronary artery.

Suzuki *et al.* [10] had divided the specific coronary artery lesions in KD, known as segmental stenosis, into three groups: braid-like lesions, bridging vessels and pericoronary arterial communications.

Sugimura *et al.* [11] were the first to use intravascular ultrasound (IVUS) imaging to evaluate the wall morphology of regressed coronary artery aneurysms in KD patients and concluded that IVUS is useful and could contribute to the assessment of long-term coronary artery sequelae and the possible development of atherosclerotic changes in KD.

REFERENCES

- 1 Kato H, Koike S, Yamamoto M *et al.* Coronary aneurysms in infants and young children with acute febrile mucocutaneous lymph node syndrome. *J Pediatr* 1975; 86: 892–8.
- 2 Fukushige J, Nihill MR, McNamara DG. Spectrum of cardiovascular lesions in mucocutaneous lymph node syndrome: analysis of eight cases. *Am J Cardiol* 1980; 45: 98–107.
- 3 Hirose O, Misawa H, Kijima Y *et al.* Two-dimensional echocardiography of coronary artery in Kawasaki disease (MCLS): detection, changes in acute phase, and follow-up observation of the aneurysm [in Japanese; English abstract]. *J Cardiogr* 1981; 11: 89–104.
- 4 Kohata T, Ono Y, Misawa H *et al.* Myocardial imaging with thallium-201 in the patients with coronary involvement after Kawasaki disease [in Japanese; English abstract]. *J Cardiogr* 1981; 11: 105–14.
- 5 Kondo C, Hirose M, Nakanishi T *et al.* Detection of coronary artery stenosis in children with Kawasaki disease: usefulness of pharmacologic stress 201-Tl myocardial tomography. *Circulation* 1989; 80: 615–24.
- 6 Kato H, Ichinose E, Yoshioka F *et al.* Fate of coronary aneurysms in Kawasaki disease: serial coronary angiography and long-term follow-up study. *Am J Cardiol* 1982; 49: 1758–66.
- 7 Kamiya T. *Report of Subcommittee on Standardization of Diagnostic Criteria and Reporting of Coronary Artery Lesions in Kawasaki Disease. Annual Report of Research Committee on Kawasaki Disease.* Tokyo: Japanese Ministry of Health and Welfare, 1983: 1–13.
- 8 Nakano H, Ueda K, Saito A *et al.* Repeated quantitative angiograms in coronary arterial aneurysms in Kawasaki disease. *Am J Cardiol* 1983; 56: 846–51.
- 9 Kato H, Ichinose E, Kawasaki T. Myocardial infarction in Kawasaki disease: clinical analyses in 195 cases. *J Pediatr* 1986; 108: 923–7.
- 10 Suzuki A, Kamiya T, Ono Y *et al.* Clinical significance of morphologic classification of coronary arterial segmental stenosis due to Kawasaki disease. *Am J Cardiol* 1993; 71: 1169–73.
- 11 Sugimura T, Kato H, Inoue O *et al.* Intravascular ultrasound of coronary arteries in children: assessment of the wall morphology and the lumen after Kawasaki disease. *Circulation* 1994; 89: 258–65.

Treatment and management

At present, the most effective treatment in the acute stage of KD is IVGG plus aspirin, which produces a reduction in fever and coronary artery aneurysm formation. The IVGG regimen includes the following options:

- 1 200 mg/kg per day for 5 days;
- 2 400 mg/kg per day for 4–5 days;
- 3 1 g/kg per day, one infusion;
- 4 2 g/kg per day (8–12 h), one infusion.

If fever occurs again in all regimens, the dosage should be repeated.

Option 1 above [1] is administered in Japan because it has been recognized by the Japanese government's health insurance system and does not incur a fee. There is a charge for higher dosages. Under this regimen coronary artery changes occur in 10–12% of patients.

Option 2 [2–4] is the original regimen established by Furusho *et al.* [2] and until 1991 was the principal treatment regimen used in the USA. Coronary artery changes occur in approximately 5% of patients. Thus, it can be seen that the difference in the results obtained with regimens 1 and 2 can be attributed to differences in dosage.

Option 3 was proposed by Engle *et al.* [5,6]. To date, no confirmatory studies have been carried out but good results have been reported [6].

Option 4 [7] was established in 1991 by the American Multicenter Collaborative Controlled Trial, and results are reported to be better than with regimen 2. At present, this regimen is the main international standard regimen.

In Japan [8], aspirin is also administered in a low dose of 30–50 mg/kg per day in all four regimens. In the USA, aspirin dosage is administered at high doses of 80–100 mg/kg per day in all four regimens. In both Japan and the USA, once fever subsides, the aspirin dosage is reduced to 3–5 mg/kg per day and continued for 2 months.

The choice of regimen depends on economic circumstances and on the severity of the individual case.

Early diagnosis and treatment are important. If KD can be diagnosed within 1 week of onset and if IVGG treatment can be started early, coronary artery changes will be prevented. Unfortunately, however, in a few patients giant aneurysms have developed despite the fact that IVGG treatment was started within 7 days of disease onset. If diagnosis is delayed until 10 or more days after onset, the risk of coronary artery changes rapidly increases.

In all cases, in the acute stage it is important to monitor coronary artery changes using two-dimensional echocardiography. If coronary artery changes such as dilatation or aneurysms have not developed within 1 month of disease onset, it is safe to assume that such changes will not occur. The two-dimensional echocardiography data should be technically accurate and should be interpreted by experienced specialists.

In patients with coronary artery changes, prognosis depends on the size of the aneurysms. Small aneurysms (less than 4 mm in diameter) usually undergo natural regression within 1 year and prognosis in general is good. Low-dose aspirin treatment (3–5 mg/kg per day) should be continued until regression. Medium-sized aneurysms (4–8 mm in diameter) undergo regression within 2 years in more than one-half of cases. In some remaining cases, stenosis and obstruction develop despite continued anticoagulant treatment.

Giant aneurysms (more than 8 mm in diameter) almost never regress. Despite anticoagulant treatment (aspirin, dipyridamole, ticlopidine, warfarin, etc.), there is a strong tendency for obstruction or stenosis to develop within 2 years, especially in the right coronary artery. Obstruction develops sooner in the right coronary artery than in the left coronary artery, usually within 1 year. Because it is difficult to interpret obstruction and stenosis using two-dimensional echocardiography, angiography should be performed and should be repeated in the course of the disease in order to follow the progress of obstruction or stenosis.

In patients with giant aneurysms, provided high-dose anticoagulant treatment is continued, obstruction, if it develops, will do so only gradually. The younger the child, the more likely it is that ischaemia will result in collateral

circulation. Thus, even if there is complete obstruction, myocardial infarction is asymptomatic. In patients in whom asymptomatic myocardial infarction is suspected, ^{201}Tl scintigraphy or myocardial imaging should be performed. In older children, exercise electrocardiography (treadmill, etc.) can be performed. However, it is important to be aware of the low sensitivity of such procedures.

In patients with symptomatic myocardial infarction, percutaneous transluminal coronary recanalization (PTCR) should be performed within 6 h, as in adults.

Some patients with ventricular dysfunction, heart failure, severe arrhythmias or postinfarction angina are managed by surgical treatment. Indications are as follows: (a) three-vessel obstruction; (b) severe occlusion in the left main trunk; and (c) severe occlusion in both the left anterior descending artery and the right coronary artery.

According to Kitamura *et al.* [9], 167 patients with KD in Japan have undergone bypass surgery. Bypass grafting using the intrathoracic artery is recommended for left coronary artery bypass because the long-term (3-year) patency is much higher (77.1%) than with a saphenous vein graft (52.8%). The gastroepiploic artery is suitable for right coronary artery bypass graft because it is usually large enough and has sufficient blood flow, even in younger children.

Heart transplantation has been performed in a number of patients in the USA and the UK [10]. However, the indications and long-term outcome are not yet certain.

REFERENCES

- 1 Harada K. Intravenous γ -globulin treatment in Kawasaki disease. *Acta Paediatr Jpn* 1991; 33: 805–10.
- 2 Furusho K, Kamiya T, Nakano H *et al.* High dose intravenous gammaglobulin for Kawasaki disease. *Lancet* 1984; 2: 1055–8.
- 3 Newburger JW, Takahashi M, Burns JC *et al.* The treatment of Kawasaki syndrome with intravenous gammaglobulin. *N Engl J Med* 1986; 315: 341–7.
- 4 Morokawa Y, Ohashi Y, Harada K *et al.* A multicenter, randomized, controlled trial of intravenous gamma globulin therapy in children with acute Kawasaki disease. *Acta Paediatr Jpn* 1994; 36: 347–54.
- 5 Engle MA, Fatica NS, Bussel JB *et al.* Clinical trial of single intravenous gamma globulin in acute Kawasaki disease. *Am J Dis Child* 1989; 143: 1300–4.
- 6 Barron KS, Daniel JM, Silverman ED *et al.* Treatment of Kawasaki syndrome: a comparison of two dosage regimens of intravenously administered immune globulin. *J Paediatr* 1990; 117: 638–44.
- 7 Newburger JW, Takahashi M, Beiser AS *et al.* A single infusion of intravenous gamma globulin compared to four daily doses in the treatment of acute Kawasaki syndrome. *N Engl J Med* 1991; 324: 1633–9.
- 8 Kato H, Koike S, Yokoyama T. Kawasaki disease: effect of treatment on coronary artery involvement. *Pediatrics* 1979; 63: 175–9.
- 9 Kitamura S, Kameda Y, Seki T *et al.* Long-term outcome of myocardial revascularization in patients with Kawasaki coronary artery disease. A multicenter cooperative study. *J Thorac Cardiovasc Surg* 1994; 107: 663–73.
- 10 Checchia P, Pahl E, Rosenfeld E *et al.* The worldwide experience with cardiac transplantation for Kawasaki disease. In: Kato H, ed. *Kawasaki Disease*. Amsterdam: Elsevier Science, 1995: 522–6.