

Chapter Ten

Prosthetic Dentistry

This chapter relates to unit DN20 'Provide chairside support during prosthetic dental treatment'.

It covers the three elements:

- DN20.1 'Prepare patients, environments, equipment and materials for prosthetic dental treatment'
- DN20.2 'Facilitate the preparation and fitting of fixed prostheses'
- DN20.3 'Support the oral healthcare team in the design, construction and fitting of removable prostheses'

The equipment, materials and methods, laboratory role, dental nurse support and oral health information is given for the following fixed prostheses:

- Temporary and permanent crowns
- Temporary and permanent bridges
- Veneers
- Inlays

The same information is given for the following removable prostheses:

- Acrylic full and partial dentures
- Chrome cobalt full and partial dentures
- Immediate replacement dentures

■ ■ *Scope of prosthetic dentistry*

Prosthetic dentistry is concerned with fixed prosthetics and removable prosthetics, as follows:

Fixed prosthetics covers:

- Crowns and temporary crowns
- Bridges and temporary bridges
- Veneers
- Inlays

Removable prosthetics covers:

- Acrylic dentures
- Chrome dentures
- Immediate replacement dentures

■ ■ *Fixed prosthetics*

All of those to be described are provided for varying reasons but involve the use of similar materials and similar instruments.

■ *Crowns*

Crowns are fixed prostheses cemented permanently to individual teeth when:

- Underlying tooth is heavily restored (filled) and showing signs of failure, such as cracked cusps and repeated filling fracture
- Root filled teeth, which tend to become brittle with time
- Aesthetic reasons, when tooth is malaligned, discoloured, wrong shape
- Shape change to make a more retentive abutment tooth for a removable prosthesis (denture)

Several types of crown are available. Anteriorly they tend to be tooth coloured, but posteriorly they are often fully metallic. Anterior crowns include:

- Porcelain jacket crown
- Bonded porcelain to metallic substructure crown
- All-ceramic crown

Of these three types, porcelain jacket crowns are the weakest and least likely to be used, unless the patient has a low occlusal force.

Posterior crowns include:

- Non-precious metal alloy crown
- Precious metal alloy crown
- Bonded porcelain to metallic substructure crown

These three types are similarly strong, but porcelain can be cracked off the metallic substructure of the third type, especially with patients who have strong occlusal forces.

Instruments

The instruments required for a crown preparation are a normal tray set up for conservation procedures (Fig. 10.1).

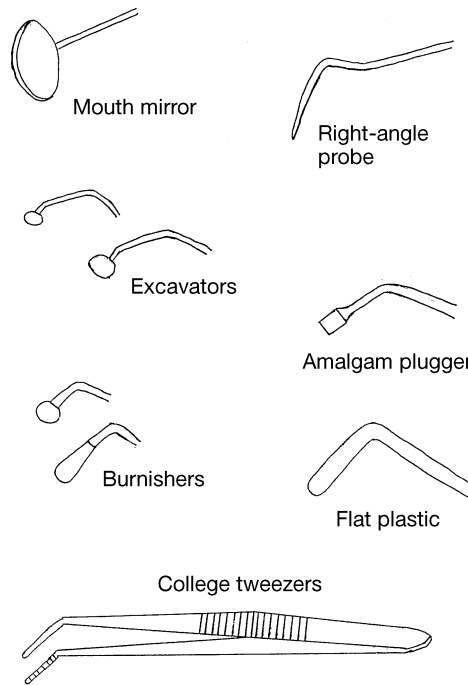


Fig. 10.1 Conservation tray for a crown.

The instruments have the following functions:

- Mouth mirror – for vision, to reflect light onto the tooth, and to retract and protect soft tissues
- Right-angle probe – to feel cavity or preparation margins, to detect softened dentine, to detect overhangs of fillings
- Excavators – small and large, to spoon out softened dentine
- Amalgam plugger – to press amalgam (and other plastic filling materials) fully into prepared cavities, to ensure no air spaces remain and to remove excess mercury from the amalgam mix
- Burnisher – ball-ended or pear-ended, to ensure margins of fillings and gold crowns are fully adapted to the tooth preparation, to prevent leakage under the restoration
- Flat plastic – to adapt plastic filling materials to cavities and preparations, to remove excess filling material before setting, to ensure a smooth marginal contact from restoration to tooth
- College tweezers – to hold and carry a multitude of things, such as cotton wool pledgets, sponges, endodontic materials, and so on

This is the basic set up for a conservation tray, but dentists will differ in their individual requirements.

Impression materials

The technique of crown construction is an indirect one, whereby the dentist prepares the tooth and then sends a copy of it to a technician (using impression materials) for the crown to be custom made. The crown is then supplied to the dentist for fitting to the patient's tooth. An impression of the opposing arch of the teeth is also sent so that the technician can ensure that the crown will not alter the patient's bite, once fitted.

The variety of impression materials available is vast, but all have to have the following properties:

- To be easily mixed
- To be cost effective
- To have an adequate working time before setting
- To have a relatively short setting time, for patient comfort
- To record tooth details accurately
- To be stable when set so that models cast from the impression are accurate and not distorted
- To be elastic so that tearing on removal does not occur, and so that the impression maintains the details recorded accurately
- To be able to be disinfected without affecting the accuracy of the details recorded, as a cross-infection precaution

The more commonly used elastic types of impression materials fall into one of the following categories:

- Irreversible hydrocolloids – alginate
- Addition silicones, from heavy-bodied putty to light-bodied paste
- Polyethers

Alginate

Alginate is the most commonly used impression material in dental practice, as it is easy to mix and relatively cheap. It is suitable for producing impressions for models for the following:

- Opposing arch models for crown, bridge, inlay and veneer construction
- Models for the construction of full and partial acrylic dentures
- Models for the construction of removable orthodontic appliances
- Study models
- Models for the construction of special trays, bleaching trays and orthodontic retainers

However, it is not accurate enough to be used to take the working model for crown, bridge, veneer or inlay construction.

Alginate is presented as a dry powder of calcium salt, alginate salt and filler, with a measured scoop, which is mixed with water at room temperature using

a similar measuring cup. Once the container has been shaken to ensure even distribution of the constituents, and then measured out, it is mixed in a plastic bowl with a large spatula, by folding the powder into the water initially, then vigorously spreading it against the bowl side (spatulating). The mix needs to be spatulated thoroughly to be free of air bubbles, to create a stiff and creamy consistency.

The mix is then loaded into an impression tray before insertion into the patient's mouth.

Impression trays are available as the following:

- Plastic disposable or plastic/metal reusable (which need to be autoclavable)
- Upper or lower
- Variety of sizes from child to large adult
- Stock trays which are mass produced, or special trays which are made individually from patient's first model
- Boxed for dentate patient, or ridge shaped for edentulous patient (those with no teeth)
- Perforated or requiring an adhesive, to prevent impression material pulling out of tray while being removed from mouth

For a single crown, inlay or veneer preparation, a system of 'triple tray' can be used which records the prepared tooth, the opposing teeth, and the patient's correct occlusion in one stage. These are single use, disposable trays made of a plastic frame and cloth infill, which save considerably on the more expensive types of impression material, as they do not require full arch impressions to be taken (Fig. 10.2).

The working time of alginate is affected by the temperature of the mixing water used, and the setting time is affected by the room temperature. In both cases, the higher the temperature, the less time is required.

There are also 'chromogenic' alginate materials available which change colour during the mixing and setting stages, for ease of use and accuracy of set.

Once set, the impression can be removed from the patient's mouth and rinsed under cold running water to remove saliva, blood and other debris, before being soaked for up to 10 minutes in a 1% sodium hypochlorite (bleach) solution to disinfect it. It is then rinsed and wrapped in damp gauze and placed in an airtight bag to prevent drying out, as this would distort the impression.

Ideally, the impression will be received within 24 hours by the technician, who will then cast up a model from it using dental stone.

Addition silicones

Addition silicones are highly accurate impression materials used specifically for fixed prosthetic work and some removable prosthetic work. They have a variety of presentations:

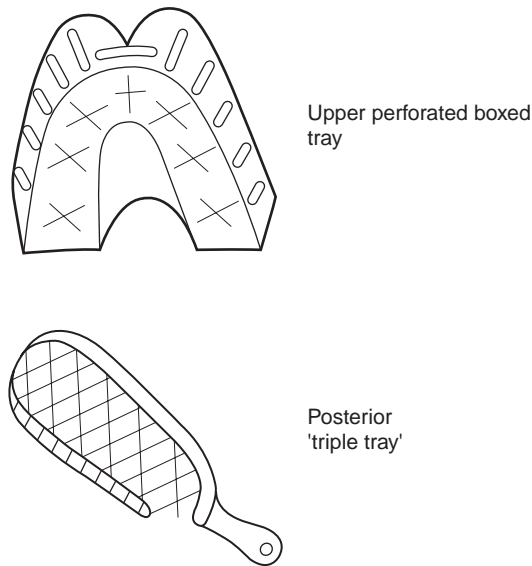


Fig. 10.2 Impression trays.

- Tubs of heavy-bodied putty with liquid or paste activator (chemical which actually starts the reaction to produce the impression material)
- Tubes of light-bodied paste with liquid or paste activator
- More recent preloaded gun syringes which mix the constituents automatically

Again, measures are provided for accurate mixing, but it should be noted that it is possible for the mixing and setting times to be affected by some types of rubber gloves used. If mixing is to occur by hand, it is advisable to wear vinyl gloves as other types may affect the setting of the silicone impression.

As each component is usually highly coloured, adequate mixing can be seen to have occurred when a non-streaky mix is produced. Silicones are not affected by temperature.

The silicones can be used either in a one-stage technique (using addition-cured silicones) or two-stage technique (using condensation-cured silicones). With the former, both the heavy-bodied putty and the light-bodied paste are mixed at the same time. The putty is loaded into the impression tray while the paste is either syringed onto the prepared tooth or placed onto it using a flat plastic instrument. Both materials then set and are removed together.

With the two-stage technique the putty is mixed, loaded into the tray, inserted into the mouth and allowed to set first. It is then carefully removed and spaced in the area of the preparation while the mixed paste is syringed or wiped onto the tooth. The set putty and tray are reinserted and the whole is removed when the paste has set.

While the one-stage technique is quicker, the two-stage ensures that

adequate paste remains around the prepared tooth during tray insertion and gives a very accurate impression, whereas it can be displaced by the putty during tray insertion in the one-stage method.

Adhesive is usually supplied by the manufacturer, but perforated trays can also be used.

Setting time is usually 4 minutes or more, so moisture control and patient comfort are of paramount importance.

Following removal from the mouth, the impression is again rinsed in cold water then immersed in 1% sodium hypochlorite solution, but only for 1 minute. It is then rinsed again and, unlike alginate, the impression is blown dry (using a triple syringe) before being sealed in an airtight bag and despatched to the laboratory, ideally within 24 hours.

Polyethers

Polyethers are also highly accurate impression materials, used specifically for fixed prosthetic work and certain removable prosthetic work. They are presented as two pastes which are usually different colours to ensure uniform mixing occurs. They are mixed in equal proportions by spatulation on a waxed paper pad, and then collected into special syringes for administration to the prepared tooth (Fig. 10.3). The remaining material is loaded into the impression tray. Again, adhesive is supplied by the manufacturer.

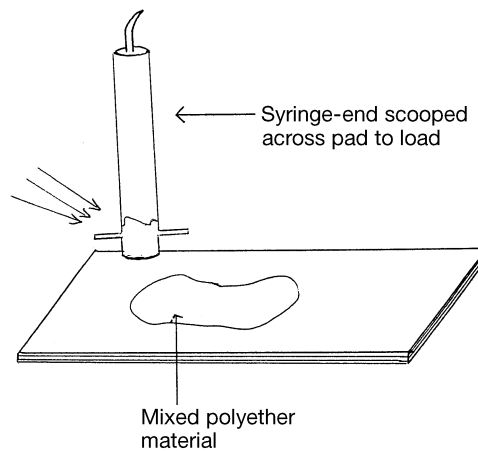


Fig. 10.3 Polyether technique.

Polyethers have a similar setting time to silicones. They set more stiffly than other elastomers, and therefore need to be removed with a sharp displacing action from the mouth, otherwise they can be difficult to remove.

Disinfection is carried out in a similar manner to silicones, but polyethers are more dimensionally unstable if moist, so the impression must be

thoroughly dried before sealing in an airtight bag and despatching to the laboratory, again preferably within 24 hours.

Surgery procedure for crown preparation

Regardless of which tooth is being prepared to receive a crown, the procedure is basically the same. As with all clinical procedures, the role of the dental nurse can be summarised thus:

- (1) Ensure the surgery is clean and ready to receive the patient
- (2) Have all the correct clinical records, including radiographs and study models, available for the relevant patient
- (3) Welcome the patient into the surgery
- (4) Have appropriate local anaesthetic equipment set up for use, and pass to the dentist as required
- (5) Have all sterile instruments and equipment set up ready for use, and pass to the dentist as required
- (6) Provide good aspiration, moisture control and tissue retraction as required
- (7) Mix the required materials correctly and pass to the dentist as required
- (8) Provide suitable support to the dentist during the finishing of the procedure
- (9) Monitor the patient throughout the procedure to ensure they are comfortable and not distressed
- (10) Help the patient to rinse out and clean up as necessary
- (11) Give relevant and accurate post-operative instructions to the patient as required
- (12) Escort the patient safely to the reception area
- (13) Clean all dirty instruments and sterilise appropriately, or dispose correctly of single use items
- (14) Clean surgery correctly and prepare it for the next patient and procedure
- (15) Ensure the clinical notes are correctly written up and that any charting is completed

Adapting this procedure for a crown preparation, the actual surgery procedure can be summarised thus:

- (1) Unless the tooth is non-vital, local anaesthetic will be necessary
- (2) An alginate impression of the opposing arch is taken, using the appropriate impression tray
- (3) An occlusal registration is often taken, especially in complicated cases, using either softened wax which the patient bites into, or using face bows for articulation of the models at the laboratory
- (4) The tooth is prepared by reducing its overall dimensions by 1 mm for metallic or ceramic crowns, or 1.5 mm for bonded crowns, using diamond burs which produce near-parallel sides to provide optimum retention, but without producing undercuts (Fig. 10.4).

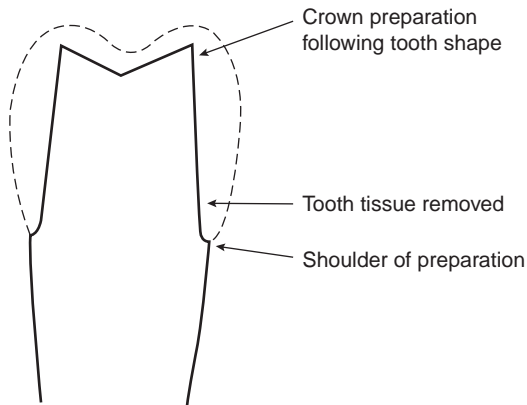


Fig. 10.4 Crown preparation.

- (5) To ensure accurate recording of the crown preparation margins, gingival retraction cord can be pushed into the gingival crevice and removed immediately before the impression is inserted
- (6) This is cord soaked in either adrenaline or alum, both of which cause the gingivae to retract and pull away from the tooth, thus allowing impression material to flow in and accurately record the margins
- (7) An elastomer impression is then taken of the working arch, as described
- (8) When satisfactory impressions have been produced, a temporary crown is made at the chairside and cemented temporarily to the prepared tooth
- (9) A shade of the tooth is taken, to match accurately the adjacent teeth including any darkening towards the root, or hypomineralised areas
- (10) All relevant details are accurately recorded on the laboratory slip, which is sent to the laboratory with the impressions and occlusal registration for construction of the permanent crown
- (11) A correct return date should be given, to coincide with the patient's next appointment for fitting of the crown

■ *Temporary crowns*

Temporary crowns are provided for aesthetic reasons, to prevent over-eruption of the prepared tooth, and to avoid sensitivity problems in the prepared tooth while the permanent crown is being constructed.

Temporary crowns can be hand made at the chairside:

- An alginate impression of the tooth is taken before crown preparation begins
- A cold cure acrylic material is then mixed and placed in the impression after crown preparation, and reinserted into the mouth

- This takes just minutes to set, and produces a temporary crown of exactly the shape of the original tooth
- Shades are rather restricted, so colour matching is as accurate as can be expected

Temporary crowns can also be provided by mass production in various sizes, for each tooth shape. These can be cut and trimmed at the chairside to fit any prepared tooth, using either acrylic trimming burs, or Beebee crown shears to ensure accurate marginal fit (Fig. 10.5). They are then temporarily cemented to the tooth, using a zinc oxide and eugenol temporary cement, while awaiting the permanent crown construction.

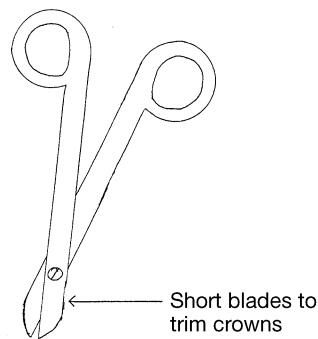


Fig. 10.5 Beebee crown shears.

Surgery procedure for crown fitting

Laboratories vary in the time required for the crown to be custom made. Accurate and detailed information provided on the laboratory slip will ensure that unnecessary delays are avoided, and a professional and trusting relationship between the practice and the laboratory technician often allows for speedier completion on occasion.

Again, the nurse's role is as detailed in the previous section, and the fitting procedure can be summarised thus:

- (1) Local anaesthetic may or may not be required
- (2) A full conservation tray is set out
- (3) Temporary crown is removed, using either a flat plastic or an excavator at the margin to dislodge it, or by cutting it off carefully with burs
- (4) The latter may be necessary with custom made temporaries, as their acrylic content shrinks on setting and often produces extremely tight-fitting temporary crowns
- (5) With suitable airway protection (either rubber dam or gauze sheets laid behind the prepared tooth) to prevent loss of the crown accidentally, the crown is tried onto the clean tooth preparation
- (6) The marginal fit, occlusion and shade are all checked for accuracy, and minor adjustments can be made

- (7) Articulating paper held in Miller's forceps is the usual method used for checking of the occlusion
- (8) If the marginal fit is inaccurate, saliva and bacteria can leak under the crown and caries will occur or the fitting cement will dissolve and the crown will come off
- (9) If the occlusion is incorrect the patient will experience pain and discomfort from the tooth, and the tooth may become dislodged
- (10) If the shade is incorrect, the crown will need to be remade
- (11) Once both the dentist and patient are happy with the crown, it can be permanently cemented using one of a variety of luting cements

Luting cements

Luting cements are cements which adhere to tooth tissue and the inner surface of the crown either chemically or mechanically, thereby holding the crown firmly onto the tooth. A variety of different types are available:

- Zinc phosphate cement which relies on the microscopic roughness of the prepared tooth and the inner surface of the crown for cementation
- Polycarboxylate cement which chemically bonds to enamel, dentine and metal
- Glass ionomer cement which also chemically bonds to enamel, dentine and metal
- Polyester resin cement which is also chemically adhesive and is highly resistant to dissolving in oral fluids
- Self-curing resins which form bonds between the tooth and the crown
- Light-curing resins which act the same as self-curing resins but are set using the curing light
- Dual-curing resins which are a combination of the previous two

Modern types of cement tend to be provided in double syringe form with no mixing necessary, but older types (such as phosphate, polycarboxylate and glass ionomer cements) require correct proportioning and thorough mixing before use.

All can be mixed on a cool glass slab with a small spatula, by incorporating increments of powder into the relevant liquid and spatulating thoroughly until a smooth, creamy mix is produced.

Working and setting times vary among products, and need to be followed closely for accuracy. If the mix is too stiff, the crown will be unable to be seated fully so that the occlusion will be incorrect. If the mix is too runny, the setting time will be prolonged and the cement will not set consistently throughout, so that loss of the crown is likely.

■ *Post-crowns*

Post crowns are crowns cemented onto a metallic post and core, which has been inserted into the empty root canal of a non-vital tooth (Fig. 10.6).

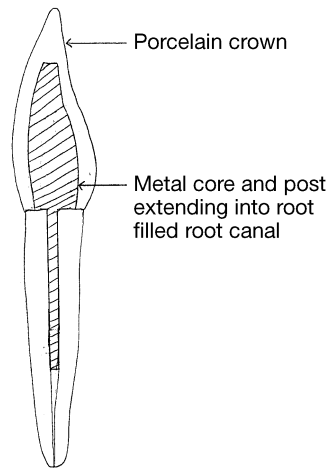


Fig. 10.6 Post crown.

Often, root filled teeth become brittle with time and sometimes snap off at the gingival margin, leaving just the root of the tooth in the dental arch. Post crowns provide a permanent method of restoring them:

- (1) The remaining root face is shaped as for the margins of a crown preparation
- (2) The root filling material is removed to a suitable depth from the root canal, using Gates–Glidden burs (Fig. 10.7)
- (3) The empty canal is widened using a post preparation system, such as Parapost[®], which produces parallel-sided post holes for maximum retention

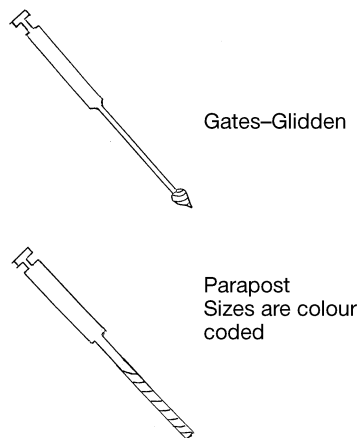


Fig. 10.7 Post crown burs.

- (4) Either a prefabricated metal post or a carbon fibre post is then cemented in, or an impression of the preparation is taken, incorporating a wax post which will accurately record the post hole
- (5) If the former, then a core can be built onto the protruding end of the post so that a conventional crown impression technique can be followed
- (6) If the latter, then the post and core will be custom made as one by the laboratory
- (7) This can then be cemented permanently at the crown fit stage, using one of the luting cements described

Oral hygiene instruction for crowns

No matter how well fitting the crown is to the tooth, microscopically the junction between the two is a potential stagnation area for plaque to gather. Thorough brushing at the margins of the crown will ensure that plaque does not accumulate and cause recurrent caries or periodontal problems.

The oral health messages to be relayed to the patient are:

- Regular and thorough toothbrushing daily
- Use of fluoride toothpaste and medium-textured toothbrush
- Regular flossing to clean crown margins interproximally
- Careful use of floss so as not to dislodge crown
- Attend for dental examinations so that margins can be checked professionally
- Sensible diet, low in non-milk extrinsic sugars
- Regular use of good quality mouthwash, to reinforce plaque control

■ *Bridges*

A bridge is a type of fixed prosthesis which is used when a patient has one or more missing teeth in a dental arch and does not wish to have them replaced by a denture. Missing teeth can also be replaced by titanium implants, which are surgically placed into the alveolar bone, but they are a specialist technique practised in few general dental practices, and are beyond the remit of this book.

Bridges have several advantages over removable prostheses:

- There is no embarrassment of a loose prosthesis falling out, as bridges are fixed to the teeth permanently
- On the whole, their aesthetics are superior to dentures
- They are more hygienic than dentures, because there is no involvement of any teeth except the retainers and therefore fewer stagnation areas
- Usually only two appointments are required for their provision
- The materials used in their construction are better able to resist occlusal forces than acrylic
- The shades available can be customised in any way by the laboratory technician to mimic the patient's other teeth, whereas those available for dentures are mass produced and unalterable

- They solve the problem of patients with a strong gag reflex who require tooth replacement, and who usually cannot cope with a denture
- They are also better tolerated because of the minimal amount of soft tissue coverage involved

The need for good oral hygiene control post-operatively is of paramount importance, as bridges produce stagnation areas unlike any others in the mouth (that is, under the pontics), and require special techniques for effective cleaning.

Several different types of bridge have been developed, but all designs rely on retaining teeth (abutments) to hold the bridge permanently in place, and they are joined to the missing teeth (pontics) in one structure thus:

- Fixed-fixed bridge where retaining teeth are involved to either side of the missing teeth, as one solid design (Fig. 10.8)
- Fixed-moveable bridge where a joint is incorporated in the design to allow some degree of flexibility to the bridge (Fig. 10.9)
- Cantilever bridge, either simple design where retaining teeth are those immediately to one side of the pontic only (Fig. 10.10), or spring design where the retaining teeth are to one side but several teeth away from the pontic (Fig. 10.11)
- Adhesive bridge where retaining teeth undergo minimal tooth preparation and retention is provided by metal wings only (Fig. 10.12)

The choice of which type of bridge is used depends on several factors:

- Whether an anterior or a posterior tooth is being replaced, as the latter usually undergo heavier occlusal forces, so full crown retainers are generally required

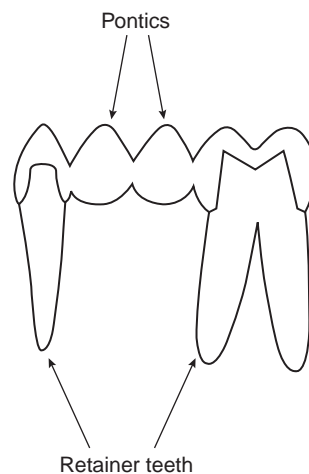


Fig. 10.8 Fixed-fixed bridge.

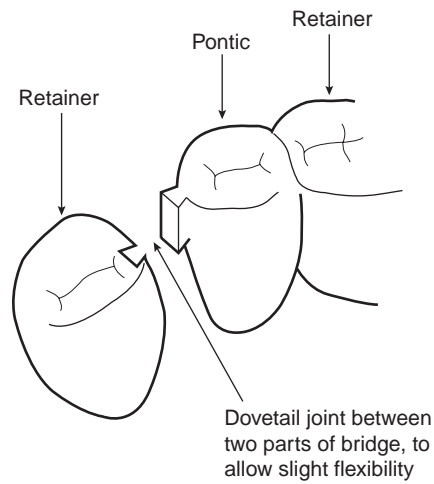


Fig. 10.9 Fixed-moveable bridge.

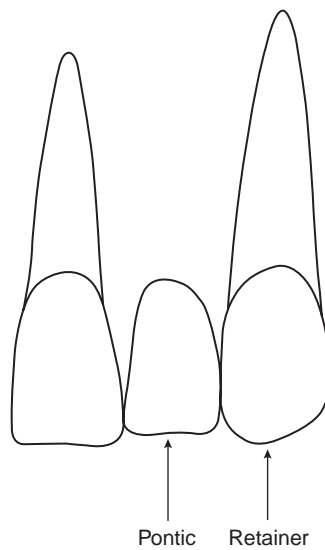


Fig. 10.10 Simple cantilever bridge.

- Like crowns, bridges can be constructed of all-metal or ceramic materials (the former would not be provided anteriorly)
- Fixed-fixed bridges tend not to be used nowadays, as their inflexibility during use can cause damage to retaining teeth
- Wherever possible, adhesive bridges are used, as they involve minimal tooth preparation

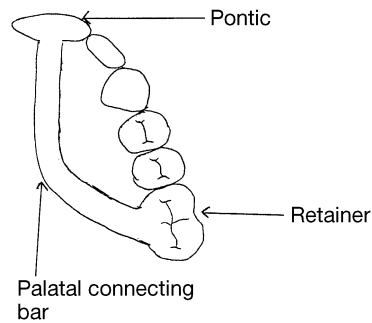


Fig. 10.11 Spring cantilever bridge.

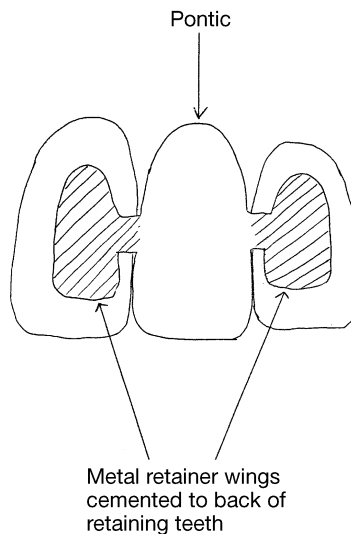


Fig. 10.12 Adhesive bridge.

- If a patient has natural spaces between the teeth, only a spring cantilever design can be used so as to maintain the spaces and give good aesthetics
- The health of the retaining teeth is of paramount importance to the success of the bridge, and if there is any cause for concern, an adhesive type of bridge is advisable so that any problems would result in its dislodgement rather than causing damage to the retainers

All types of bridge except adhesive ones rely on the retaining teeth being of full crown coverage; indeed, the tooth preparation is exactly the same as for a single crown, as are the instruments and the impression materials used.

■ Temporary bridges

Temporary coverage of the prepared abutments is necessary as for crowns, the missing tooth or teeth being replaced temporarily either by a pre-existing

denture or not at all. Alternatively, the missing tooth and the retainers can be covered by a temporary bridge.

Temporary bridges can be made in the laboratory, before tooth extraction, or at the chairside in a similar fashion to temporary crowns using an alginate impression taken before tooth extraction. Their functions are:

- To provide reasonable aesthetics while the extraction site heals
- To provide reasonable aesthetics while the permanent bridge is constructed
- To hold the extraction space open, as teeth can drift naturally and close the space, or tip into it
- To maintain the occlusion
- To prevent sensitivity of the prepared abutment teeth

Once the permanent bridge has been constructed, any temporary bridge present can be removed in the same way as for a temporary crown. The same fitting checks are made before permanent cementation, using the same luting cement options as for crowns, except for adhesive bridges. Adhesive bridges require special dual curing resin cements with primers, to provide a strong chemical bond between the retaining teeth and the metal wings of the bridge. There is little retention provided by tooth preparation with these bridges. Their use is generally restricted to areas of low occlusal force to prevent dislodgement, although new luting cements are being developed constantly to attempt to overcome this problem.

Oral hygiene instruction for bridges

Bridges provide a challenge to the patient with regard to adequate oral hygiene, as they are fixed prostheses producing stagnation areas actually beneath the pontics. As well as the oral hygiene instructions for crowns, patients with bridges need to be instructed in the use of Superfloss[®] (Fig. 10.13). This is a type of dental floss with a stiff end, which can be threaded under the pontic by the patient, and then drawn through to a sponge part which is used to clean beneath the pontic. When used regularly, it keeps this region of the bridge free of plaque and prevents caries undermining the retainers, with catastrophic consequences.

More recently, the use of sonic toothbrushes has been shown to provide excellent cleaning in these areas, without dislodging the bridge, and these are being recommended more frequently in these cases.

■ Veneers

Veneers are either a composite or porcelain facing made to cover the labial surface of anterior teeth. They are used in the following situations:

- To mask a discoloured tooth (such as with tetracycline staining)
- To mask a darkened, root filled tooth
- To close diastemas (gaps) between teeth

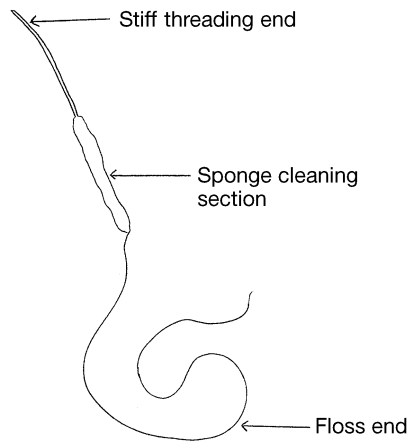


Fig. 10.13 Superfloss®.

- To change the shape of rotated teeth so that they appear aligned
- To change the shape of malaligned teeth so that they appear aligned
- To correct poorly shaped teeth, such as peg laterals
- As a cosmetic procedure, to lighten the whole labial segment

Veneers are fragile once constructed, and can break if the patient is careless with them. Ideally, they are only fitted to patients with low incisal edge forces and they are constructed so as not to cover the incisal edge of the tooth. This then gives the unlikeliest conditions for the veneer to fracture during normal use.

The instruments and impression materials are the same as for crowns and bridges, but often no opposing arch impression is required as veneers rarely encroach on the occlusion.

Surgery procedure for veneer preparation

- (1) The role of the dental nurse is as summarised for crown preparation
- (2) Unless the tooth is non-vital, local anaesthetic will be required
- (3) On the rare occasion that an opposing arch impression is required, this is taken in a stock tray using alginate
- (4) The labial surface of the tooth is prepared by removing enough enamel to allow the technician to construct the veneer, this is especially important if the veneer is to give the appearance of alignment to the tooth (Fig. 10.14)
- (5) An impression is taken of the labial segment using one of the highly accurate elastomer materials, as for crowns and bridges
- (6) The prepared tooth is covered temporarily for appearance and sensitivity reduction, using composite material etched just to the centre of the tooth, so that it can be removed easily at the veneer fit appointment

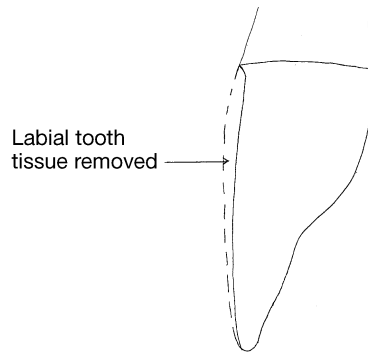


Fig. 10.14 Veneer preparation.

- (7) An accurate shade is taken, recording all tooth characteristics for the technician, as for crowns and bridges

Surgery procedure for veneer fitting

As with all fixed prostheses, veneers are custom made in the laboratory by a highly skilled technician. The shades taken in the surgery will be accurately replicated as the veneer is constructed from porcelain, before having the final firing in an oven to produce the surface glaze. The fitting surface of the veneer will be abraded in the laboratory, to produce a rough surface for cement adhesion. The finished product is then carefully returned to the surgery for fitting.

- (1) Local anaesthetic may be required
- (2) The temporary veneer is removed by flicking it off carefully with a hand instrument, such as a flat plastic or an excavator
- (3) The veneer is carefully tried onto the tooth and the fit and shade are checked
- (4) If satisfactory, the fitting surface of the veneer is coated with a silane agent which allows the dual cure resin cement to chemically bond to it for good adhesion
- (5) The tooth is isolated with either rubber dam or celluloid matrix strips, and then etched, washed and dried
- (6) The dual cure resin bond and cement are applied to the tooth and the veneer is carefully pushed onto it, in the correct position
- (7) Excess cement is removed before light curing occurs
- (8) Flecks of cement trapped interproximally can be removed using abrasive diamond strips, otherwise they will act as stagnation areas and hold plaque

Alternatively, composite veneers can be made at the chairside by the dentist. Good isolation of the adjacent teeth is of paramount importance,

otherwise etch, resin and cement will adhere to these teeth and the patient will be unable to clean correctly.

The shades available for composite veneers are inferior to those for porcelain veneers, but the former are far cheaper to provide than the latter.

■ Inlays

Inlays are a fixed prosthesis constructed indirectly at a laboratory rather than placed directly into the tooth, as a filling would be (although a direct technique using wax patterns used to be carried out years ago, but is rarely seen nowadays).

Inlays are constructed of either gold alloy, porcelain or a special type of composite which contains more filler than usual and which is therefore stronger than conventional composites.

The purpose of inlays is to produce a restoration of higher strength than the plastic materials, and of a more permanent nature, although with the continual improvement of filling materials, gold alloy inlays are being provided less frequently nowadays.

As the inlay is inserted into the tooth rather than cemented onto it, less tooth preparation is also necessary than for a conventional crown. The equipment, materials and impression techniques are the same as for other fixed prostheses.

Inlay preparation is as for a conventional filling, with the full removal of all carious tooth tissue to sound dentine, but then the cavity preparation is adjusted to ensure that the sides are not undercut but parallel (Fig. 10.15). This allows:

- The inlay to be inserted fully, without becoming stuck on an undercut
- The maximum retention possible is produced, by ensuring that the inlay fits snugly against all the cavity walls
- Only a fine cement layer will then be required, which reduces the risk of cement dissolution

Once the cavity has been prepared suitably and the necessary impressions and occlusal registrations have been taken, the tooth is restored with a temporary filling.

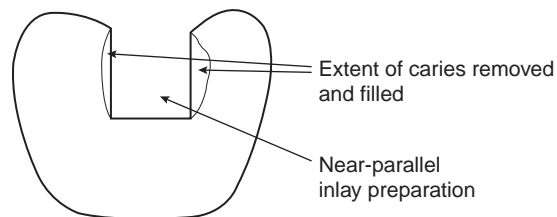


Fig. 10.15 Inlay preparation.

At the fit of the inlay, the occlusion is checked as for crowns and, when correct, the inlay is cemented using one of the luting cements available, as for crowns. Gold alloy inlays have their margins well adapted to the tooth by burnishing at the fit stage, so that the wafer thin edge of the inlay is pressed firmly against the cavity wall. This prevents ingress of saliva and reduces the possibility of the cement being dissolved out (dissolution), with subsequent loss of the inlay.

■ ■ *Removable prosthetics*

Removable prostheses are all types of dentures, appliances which are made in the laboratory in various stages to replace missing teeth. They can be removed from the mouth by the patient, for example for cleaning, and re-inserted easily, without the use of cements. Generally, they are made to replace several missing teeth rather than just one or two, as bridges do, or even to replace all the teeth in edentulous patients.

When several teeth are missing, their replacement is necessary to:

- Prevent excess masticatory forces on the remaining teeth, which may cause their eventual fracture
- Prevent overeruption of opposing teeth, which can cause occlusal problems
- Prevent tilting of adjacent teeth into the edentulous spaces, which disrupts the occlusion and creates stagnation areas
- Prevent soft tissue trauma to the alveolar ridges during mastication
- Allow adequate mastication and avoid digestive problems, especially in the elderly
- Provide good aesthetics, especially if anterior teeth are missing

■ *Full and partial acrylic dentures*

Acrylic dentures are the commonest types of denture produced, full ones for edentulous patients and partial ones for any number of missing teeth.

As dentures are removable prostheses, their retention in the mouth relies not on cements, as for fixed prostheses, but on the following:

- A suction film of saliva developing between the denture and the patient's soft tissues
- A post dam along the back border of the denture, to help the suction film to develop
- An accurate design and fit of denture, to allow the film to develop adequately
- Use of any natural undercuts in the patient's mouth, such as the alveolar ridges or any natural teeth
- Use of stainless steel clasps around standing teeth, to increase retention

Sometimes, the patient's own teeth are adjusted to provide undercuts, in the following ways:

- Use of a crown to change the overall shape of the tooth
- Use of composite build-ups to provide a retentive area for clasps to engage
- Shape change of an existing restoration for similar reasons

With edentulous patients, the alveolar ridges can be changed surgically, to improve retention and comfort:

- Gross undercuts which would prevent the denture being seated can be removed
- Flat ridges can be built up by the addition of bone substitutes to increase natural retention
- Sharp ridges can be smoothed to allow comfortable wearing of the denture (alveolectomy)

Not all patients are suitable for treatment involving the use of dentures, and the following points need to be considered for every case before treatment commences:

- Is there any previous denture experience, and was it successful?
- If not successful, is there a cause which can be remedied?
- Is the shape of the patient's mouth naturally retentive for full dentures, with good ridges and a high palate, or might pre-prosthetic surgery be necessary?
- Are there any potential retention problems for partial dentures? If so, can they be remedied by tooth shape adjustment?
- Might the patient's occlusion cause problems with the provision of a denture? Is there enough clearance without premature contact onto the denture?
- Are there any medical contraindications to dentures, such as epilepsy or an adverse reaction to the acrylic material?
- Are there other dental problems which need addressing first, such as caries or periodontal disease?
- If the teeth have been lost within the previous six months, bone resorption is likely to occur and this will adversely affect the fit of a denture
- Good cooperation and perseverance by the patient are paramount to the success of dentures; if there is any doubt about these then treatment is likely to fail
- Is the treatment affordable to the patient?

Denture construction

Usually, acrylic dentures are made in five stages, with each stage having to be returned to the laboratory between appointments. The construction of the denture is summarised thus:

- (1) **Initial impression** – taken in either a boxed stock tray for dentate patients, or an edentulous stock tray as necessary and using alginate as the impression material. The shade and mould of teeth are also chosen
- (2) **Laboratory** – models are cast in plaster and special trays are constructed so that accurate second impressions can be taken, made of acrylic or shellac
- (3) **Final impression** – taken using the constructed special trays and either alginate or one of the more accurate elastomer materials for dentate patients, or using impression composition or impression paste for edentulous patients with no large undercuts: these stiffer materials tend to squash the soft tissues and produce tight fitting dentures
- (4) **Laboratory** – final models are cast in dental stone and wax occlusal rims are made
- (5) **Bite registration** – the occlusal face height of the patient is recorded using a Willis bite gauge for edentulous patients, so that, with the wax rims in place, they are neither overclosed nor propped open, and with dentate patients their remaining teeth are used as a guide to the correct bite. A Fox's occlusal plane guide can also be used with edentulous patients to record the correct plane from left to right, and antero-posteriorly, to ensure that the denture teeth are set correctly (Fig. 10.16). The final bite is recorded by either the warmed wax rims sticking together, or by using bite registration paste to provide a reproducible position of the rims once out of the mouth

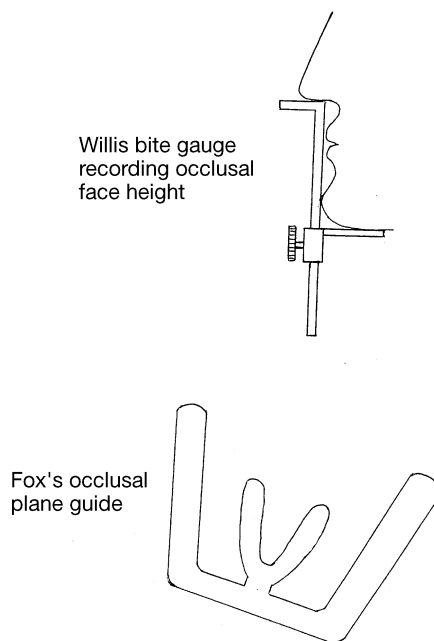


Fig. 10.16 Bite gauge and plane.

- (6) **Laboratory** – the joined wax rims and the underlying models are mounted onto an articulator which mimics the jaw movements, so that the technician can construct a wax-based try-in denture with teeth of the chosen shade set accurately into position, with no interferences on jaw movement
- (7) **Try-in** – these are inserted and checked in the patient's mouth for accuracy of occlusion, shade and fit onto the soft tissues, and any minor adjustments are easily made to the wax bases. If major adjustments are required, then a retry is usually carried out
- (8) **Laboratory** – the try-ins and the stone models are sealed into flasks and the wax is removed by boiling water, the space left between the models and the teeth is then filled in with heat-curing acrylic to form the denture bases. If clasps are being used for dentate patients, they are added at this point. The dentures are then cleaned and polished
- (9) **Denture fit** – the dentures are inserted and checked for comfort, accuracy of fit and retention, and appearance, and instructions are given on their wear

Instructions to patient at fitting stage

- Wear denture daily to allow tissues to acclimatise to it
- Leave out at night to allow soft tissues to recover
- Failure to do this can allow a fungal growth of *Candida albicans* to contaminate the denture, causing denture stomatitis (inflamed soft tissues immediately beneath the denture)
- This condition will require treatment with antifungal lozenges, and reinforcement of denture hygiene
- Clean with toothbrush and toothpaste, over a bowl of water to prevent breakages if dropped
- Can use proprietary denture cleaners if patient wishes, too
- Demonstration of how to insert and remove partial dentures, especially if clasps have been used
- Eat soft foods initially, until used to denture
- Rinse mouth with hot salt water to ease initial soreness
- Return to surgery for denture ease if problem persists or ulcers develop
- Above all, patient must persevere with denture wearing, as acclimatisation can be prolonged

Dental nurse's role and surgery set-up for each stage

The nurse's role for all dental procedures is as detailed previously. Specific points and specialised equipment and instruments are as follows:

First impressions:

- Alginate and necessary mixing bowl and spatula
- Necessary stock trays, with adhesive if not perforated
- Impression material mixed accurately and trays loaded as required

- Usual impression disinfection procedure followed, with correct bagging of impressions afterwards
- Patient's details and correct shade and mould recorded on laboratory ticket, along with the denture design and material of construction, and the date that next stage is required by

Final impressions:

- Special trays available, with adhesive if necessary
- Impression material of choice, with correct mixing implements
- Mix impression material accurately and load trays as required
- Usual impression disinfection procedure followed, with correct bagging of impressions afterwards
- Laboratory ticket completed fully, as above

Bite registration:

- Wax rims on models available
- Heat source, such as gas burner, with matches and extra sheets of pink wax
- Wax knife, plaster knife and Le Cron carver set out (Fig. 10.17)
- Willis bite gauge and facebow set out, if edentulous patient
- Bite registration paste, if required
- Wax knife and Le Cron carver are used to adjust wax rims as necessary
- Plaster knife may be required to trim heels of models, so that rims sit correctly
- Make note of occlusal face height determined using bite gauge
- Ensure laboratory ticket is correctly filled in, as above
- Ensure that rims are not dislodged from each other during bagging

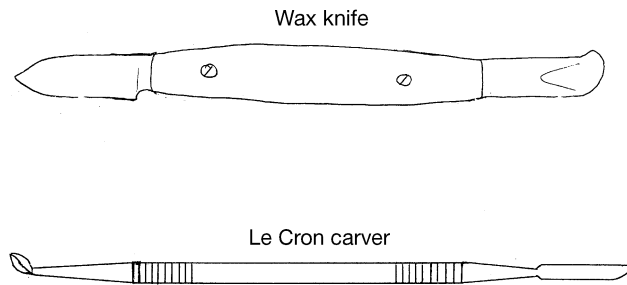


Fig. 10.17 Wax instruments.

Try-in:

- Try-in available
- Heat source, matches and sheets of pink wax available, in case wax adjustments are necessary
- Wax knife and Le Cron carver, as above
- Articulating paper so that occlusion can be checked if necessary

- Hand mirror so patient can view try-ins
- Ensure laboratory ticket is correctly filled in, as above

Fitting:

- Dentures available
- Straight handpiece with selection of acrylic trimming burs, and polishing stone
- Articulating paper or occlusal indicator wax, so that occlusal interferences can be detected and removed
- Pressure relief paste to detect high spots on the fitting surface which will cause discomfort if not removed
- Hand mirror for patient viewing of completed dentures

■ Full and partial chrome cobalt dentures

Chrome cobalt can be used as the base of the denture, rather than acrylic, but the teeth still need to be attached to this metal base by acrylic on the ridges. Metal-based dentures are more difficult to construct and cost more than acrylic ones, but the advantages are:

- A much thinner palatal covering is possible, which makes the denture more tolerable to patients with a strong gag reflex
- Overcomes any tissue reaction to acrylic monomer, as some patients are sensitive to it
- Denture base is far stronger and less likely to break
- Allows patients with deep overbites onto their palate to be able to wear denture
- Can design partial dentures as 'skeletons' giving minimal tissue coverage and making the denture more tolerable for the patients (Fig. 10.18)
- As less tissue coverage is involved, chrome dentures tend to be more hygienic than acrylic ones

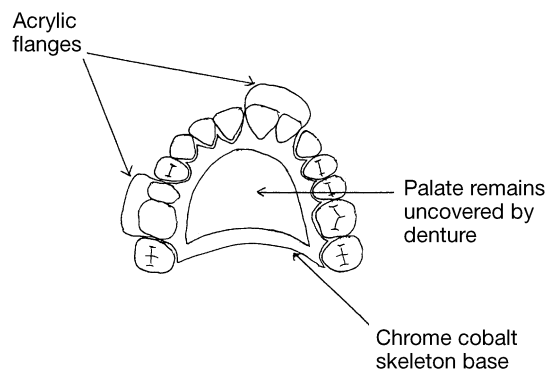


Fig. 10.18 Skeleton denture design.

If the whole palate is covered by a chrome base, then retention is provided by the saliva suction film, as for acrylic dentures. However, if a skeleton design is used then clasps must be placed to retain the denture, so an adequate number of healthy and well-positioned teeth are required.

The clasps will be part of the chrome base, and tooth adjustments can be carried out to provide undercuts, as for stainless steel clasps on acrylic dentures.

Denture construction

The surgery stages are as for acrylic dentures, the only differences being:

- Final impressions are often taken in a highly accurate elastomer material, rather than alginate
- The chrome cobalt base is then made on the final model as a wax pattern by the technician, before being cast in a special furnace
- The casting of the metal base is sometimes carried out at specialised laboratories, so extra time between appointments may be necessary
- A try-in of the metal base only is often carried out, to ensure it is accurate
- A second try-in is then performed, with the teeth added and held by wax
- No adjustment of the metal base can be made in the surgery, once constructed, except minimal easing using a pink stone in the slow handpiece

Instructions to patient on fitting denture

- All instructions as for acrylic dentures except that bleach-based cleaners must not be used, as these will corrode the metal base of the denture
- Demonstration of how to insert and remove partial metal dentures may take some time, as some designs can be quite tricky

The nurse's role and surgery set-up for each stage of the metal denture construction is as for acrylic dentures, except for the use of the pink stone for minimal eases, if necessary.

■ *Immediate replacement dentures*

The ideal way of providing dentures for a patient is to allow a minimum of six months to elapse between tooth extraction and denture provision. This allows enough time for the majority of the inevitable bone resorption, which the alveolar ridges undergo after tooth extraction, to occur. The dentures then constructed will be more accurately fitting and comfortable for the patient.

When anterior teeth are to be extracted, however, it is unreasonable to expect the patient to have visible spaces in their mouth for this length of time. Consequently, the patient is provided with acrylic immediate replacement dentures. These are made before the patient undergoes tooth extraction, and are completed and ready to be fitted on the day that the extractions take place. The advantages are:

- No time lapse between extractions and denture fitting
- Patient therefore maintains their appearance, with no visible spaces
- Occlusion and adequate mastication are maintained
- Protects extraction sockets during healing
- Aids compliance with denture wearing, especially when anterior teeth are replaced, as patient is unlikely not to wear immediate dentures, for appearance's sake

The one major disadvantage of immediate replacement dentures is that as bone resorption occurs, the dentures lose their fit and become slack and non-retentive. They also sink further into the tissues as bone is lost, and anterior teeth especially will then appear to be malaligned with the surrounding natural teeth. For this reason, immediate replacement dentures can only be constructed from acrylic, not chrome cobalt.

If just one anterior tooth is to be replaced in this way, the denture is often constructed in a 'spoon' design, so that the gingival margins of other teeth are not covered by acrylic (Fig. 10.19).

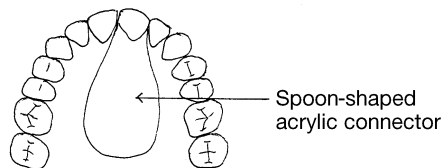


Fig. 10.19 'Spoon' denture.

Denture construction

- (1) **Impression** – taken in a boxed stock tray and using alginate. Final impressions are rarely taken, as the model produced is to be altered at the laboratory during denture construction anyway, so accuracy is already compromised. The shade and mould are taken as usual
- (2) **Laboratory** – models are cast in plaster, and if enough natural teeth are not present for the technician to assess the patient's usual bite easily, then wax rims are constructed for bite registration
- (3) **Bite registration** – as for acrylic and metal dentures, if necessary
- (4) **Laboratory** – a wax try-in is constructed of any teeth already missing. However, if the teeth being replaced are only those to be extracted, then a try-in will not be possible
- (5) **Try-in** – as for acrylic and metal dentures, if possible
- (6) **Laboratory** – the teeth being replaced immediately are carefully cut off the model by the technician, and then individually replaced on the denture in the chosen shade and mould. The denture is then inserted in the flask and the acrylic denture is constructed as usual, with or without stainless steel clasps
- (7) **Denture fit** – on ensuring that the denture has been completed as

required, the necessary teeth are extracted and the denture fitted in the usual way

Dental nurse's role and surgery set-up

The nurse's role for all dental procedures is as detailed previously. Specific points and specialised equipment and instruments are as follows:

- At the denture fit stage, it is imperative that the appliance is checked for correct completion, before extractions are carried out
- Suitable extraction instruments will be required
- Bite packs and/or suturing instruments may be required
- Extraction post-operative instructions will be necessary, as well as denture instructions

Instructions to patient on fitting denture

- Denture not to be removed for 24 hours if possible, to avoid disturbing the extraction sites
- On initial removal, and for several times each day thereafter, the patient is to perform hot salt water mouthwashes to aid healing of the extraction sites
- If sutures have been placed which are not resorbable, an appointment will be necessary for their removal
- As bone resorption occurs, the patient may need to reattend for relining of the denture

■ *Hard and soft relines*

With bone resorption occurring under immediate dentures especially, the poor fit will eventually need addressing. Acrylic dentures tend to serve their purpose adequately for at least five years (considerably longer in many cases), so remaking the denture at this stage is not feasible.

Retention and full function can be restored by replacing the resorbed bone with more acrylic, a procedure known as hard relining. Hard relining can be carried out either at the chairside or in the laboratory, but in the latter case the patient would have to be without the denture for some time.

Chairside hard reline procedure

- (1) Analysis of the denture determines where resorption has occurred
- (2) The patient's lips and other teeth have a lubricant such as petroleum jelly applied, to prevent the reline acrylic sticking to them
- (3) A cold curing acrylic is mixed at the chairside, by adding powder to the monomer liquid until a creamy consistency is achieved
- (4) This is loaded into the relevant areas of the fitting surface of the denture and inserted into the patient's mouth

- (5) Excess material is quickly removed, before being allowed to set
- (6) It is held in place by the patient biting normally together, until the acrylic just begins to set and then swiftly removed from the mouth before it hardens too much to be removed
- (7) Full curing can then occur in a bowl of hot water at the chairside
- (8) The additional acrylic can be trimmed and polished, before reinserting in the patient's mouth and checking for fit and retention

Laboratory hard reline procedure

- (1) A thin wash impression of the fitting surface of the denture is taken, using a material such as silicone wash impression which is highly accurate and elastic
- (2) The mixed material is loaded into the denture, which is then inserted into the patient's mouth and held in the normal occlusion
- (3) Once set, the denture is removed, disinfected as usual and sent to the laboratory
- (4) The denture is flaked and heat-curing acrylic is added in the usual way, to replace the space taken by the impression material
- (5) The denture is returned to the surgery for fitting at a later date

Soft relines

As bone resorption occurs following tooth extraction, the alveolar ridges become flatter with less cushioning support from the soft tissues. In elderly patients especially, this can become uncomfortable, if not painful, with time, so that dentures can no longer be worn without causing great discomfort. A soft lining can be used to artificially cushion the fitting surface of the denture, by replacing the lost gingival support and making the dentures comfortable to wear again.

An adequate thickness of the material is required to be effective, so the borders and fitting surface of the denture must be reduced to accommodate it. A wash impression is then taken within the denture before being sent to the laboratory for the soft lining to be added.

The rubbery material of the soft lining is not naturally adhesive to acrylic, and can begin peeling off with time, so the procedure often has to be repeated. The soft lining also hardens with age, and especially in the presence of bleach-based denture cleansers, which are therefore contraindicated.

Tooth additions

For various reasons, the occasional tooth may require extraction and can then be added to a pre-existing denture. This can be carried out post-extraction, or as a single-tooth immediate replacement.

- (1) Patient attends with pre-existing denture and a shade of the tooth to be replaced is taken

- (2) An alginate impression is taken over the denture in the patient's mouth
- (3) This is sent to the laboratory for a heat-curing addition of the tooth, with an acrylic connection to the base of the denture
- (4) Once returned to the surgery, the denture can be inserted immediately and checked for fit, or the tooth can be extracted and then the denture can be inserted and checked for fit
- (5) In the latter case, the post-operative instructions are as for an immediate replacement denture

As with all surgery procedures, a full working knowledge of health and safety regulations, especially COSHH in relation to dental materials and cross-infection control policies, is imperative for the dental nurse to work safely in the surgery while prosthetic treatment is being carried out.



Activities

- ▶ List all of the fixed prostheses that you have seen in your practice.
- ▶ Identify the reasons why the last four teeth that you saw being prepared for crowns were necessary.
- ▶ List the information that is required on a lab docket for a fixed prosthesis construction.
- ▶ Identify all the impression materials used in your practice, and determine what type of material they each are.
- ▶ List all the luting cements used in your practice. Find out the recommended working and setting times for two of them.
- ▶ Identify the oral hygiene instructions that would be given in your practice to a patient having their first bridge fitted.
- ▶ List the various types of removable prosthesis that you have seen.
- ▶ If any member of your family wears a denture, ask them to explain to you how it feels.
- ▶ Think back to any hard or soft relines that you have seen. Determine their necessity to the patient.
- ▶ List the oral hygiene instructions given in your practice to a patient wearing a partial acrylic denture.

Chapter Fifteen

Development of Knowledge and Practice

This chapter relates to unit DN18 'Develop one's own knowledge and practice'

Both elements of the unit are included:

- DN18.1 'Reflect on and evaluate one's own values, priorities, interests and effectiveness'
- DN18.2 'Synthesise new knowledge into the development of one's own practice'

Subjects discussed include:

- Reflection and self-evaluation
- Staff appraisals
- The concept of lifelong learning

Current career pathways available for dental nurses are indicated, but it is expected that these opportunities will be expanded upon by various bodies, with time.

■ ■ *The changing scene*

The dental profession is undergoing reform with a view to regulation of all members of the dental team, including dental nurses. All members other than dentists are now known as Professionals Complementary to Dentistry or PCDs, and compulsory registration with the General Dental Council will be the norm, once qualification has been achieved.

However, as with dentists, all PCDs will be expected to develop a system of lifelong learning and continuing professional development, so that as dentistry and dental nursing evolves, new skills and information will need to be understood and practised by all. Qualification and compulsory registration will be the basics required by dental nurses, rather than their end goal of achievement.

With these points in mind, the dental nurse needs to be capable of recognising their own limitations and effectiveness at all dental nursing skills, so that shortcomings can be addressed and acted upon. Under no circumstances must a dental nurse ever act beyond the legal limits of their qualification,

otherwise disciplinary procedures are likely to be evoked by the General Dental Council.

■ ■ *Reflective practice*

One of the best ways of recognising one's own shortcomings and acting upon them is to become a 'reflective' professional. The aim is to constantly look back (reflect) upon aspects of your clinical practice in order to try to improve it by constantly analysing, constructively criticising and evaluating your own performance. Areas of reflection should include your decision making and your interactions with patients and other dental team members.

If this process of reflection is done regularly, and preferably constantly, learning opportunities will be created from all aspects of your daily work. This then means that your skills as a dental nurse and dental team member are open to constant improvement.

Two broad types of reflection are recognised: those that occur as a situation happens, known as reflection in action, and those that occur after the event known as reflection on action. The latter is often referred to as 'hindsight'.

Reflection in action occurs by having the knowledge, skills and experience before the event happens, therefore enabling sound clinical decisions to be made at the time for a successful outcome. An example in the dental nurse context is as follows. Compare the competence of a dental nurse when nursing for a certain procedure for the first time with their competence when nursing for the same procedure for the fourth or fifth time. They will undoubtedly feel more comfortable as experience is gained, because sub-consciously their own techniques are bettered after each event. In other words, 'practise makes perfect'. If, say, that procedure is aspirating for oral surgery, the first time the following may occur:

- Not sure of all instrument identifications
- Aspiration is not fully effective
- Hesitant when handling some instruments
- Concentrating so much on the procedure that the patient is forgotten

By the fourth or fifth time, however:

- Instruments are now known because they are more familiar
- Aspiration is more effective, perhaps by learning from the first patient choking and the dentist being unable to see clearly
- Confident when handling instruments because they are more familiar
- Able to monitor and reassure patient at the same time

Reflection on action occurs by being able to think back over the procedure at a later date. This allows realisation and identification of any problems encountered with the natural continuation of thought being to recognise how to improve next time.

Most of us carry out this second type of reflection on a regular basis, for example when driving home from work and going over the days events in our minds, or by discussing our day with a family member, friend or colleague. However, we often forget the full impact of our thoughts unless we write them down at the time, and review them at a later date. Therefore, it would be prudent for the dental nurse to keep a diary, or portfolio, on a daily or, at least, weekly basis. This helps to organise and clarify thoughts, so that the reason why problems occurred can be discovered, and action plans can be developed to prevent their recurrence.

A suggested layout of a diary could be:

- Describe the event
- Record your emotions and thoughts
- Evaluate the event – give both good and bad points
- Critically analyse the event – why did it happen?
- Reach a conclusion – what could have been done differently?
- Develop an action plan – what will be done differently next time?

After going through this process, determine whether a gap in your knowledge has been identified.

It should be noted, however, that private reflection can be distorted, because by definition it is our own perception of ourselves. Consequently, rather than reflecting alone, a colleague could be asked to assist, especially one who is more experienced and may have undergone the same process previously.

In this way, a natural progression would be to develop a staff appraisal system, where a senior colleague could act as a facilitator or mentor to a more junior dental nurse. One of the best ways of facilitating is by a more experienced colleague observing the dental nurse during a set task or even during a normal working day. This process may expose aspects that were not self-evident initially.

Reflection, then, enables us to think about how we learn, especially from experience, so that the process of learning is made more effective. It produces thinking professionals who can react effectively and appropriately in any given clinical situation, and as the dental nurse course is designed as a work-based assessment qualification, this must be the set goal.

All members of the dental team will simultaneously be undergoing this process of self-evaluation, and it is the duty of the practice to ensure that written policies and protocols in relation to dentistry are updated as necessary, for the benefit of the whole dental team. The dental nurse's responsibility is to ensure that these policies and protocols are read, understood and adhered to at all times.

Self-evaluation is a process of reflection, whereby once a task or procedure has been completed the dental nurse can look back on how successful the outcome was, and whether their role was adequate or whether it could be improved upon.

Sometimes, the dental nurse may discover that their personal beliefs or

culture are inadvertently seeping into their own practise. Reflection will identify this so that the matter can be explored and addressed appropriately. As discussed previously, good communication skills and respect for patients' rights are paramount to a successful dental practice, and there should be no tolerance of any member of the dental team who judges others purely on their own values and priorities.

To be a valuable member of the dental team, the dental nurse must ensure that the following principles of good practice are achieved:

- Promote equality, diversity and anti-discriminatory practice at all times
- Respect patients' rights at all times
- Promote, develop and maintain effective working relationships with other team members
- Never stray outside the legal limits of their qualifications
- Take an active part in continuing professional development
- Ensure that all changes to effective dental nursing are known and acted upon, so that the concept of best practice is always attained

Many dental practices operate a system of regular staff appraisal and this is to be encouraged as there are several advantages for all to be gained:

- Identifies strength and weaknesses of the staff member
- Also identifies strengths and weaknesses of the running of the practice, and gives valuable information for good practice development
- Discloses any barriers to efficient working
- Improves communication amongst the dental team
- Encourages problem solving
- Reduces any negative tensions between staff members
- Improves practice morale

The purpose of appraisal (or performance review) is to reflect on past performance and achievements, with the aim of developing future goals and a system for how those goals can be achieved. When carried out correctly, it should identify any training needs of the staff member, which, when addressed, should enhance the member's performance in future.

All staff members are likely to achieve more if constructive feedback is given on their performance, so that they not only have aims to work towards but have an opportunity to help to set those aims too.

Common areas of appraisal in dental practice could include the following:

- Personal – hygiene, attitude, punctuality, dress code
- Administrative – policies and protocols, regulations, filing, knowledge of paperwork
- Clinical – infection control, mixing techniques, nursing skills, patient management
- Teamwork – ability to function as team member, acceptance of authority, ability to take responsibility

- Communication – interpersonal, telephone manner, patient management
- Development – self-evaluation, self-study, attendance at courses, learning by experience

Once the relevant areas to be appraised have been selected, discussed and agreed upon, an appraisal sheet (Fig. 15.1) can be drawn up which gives the dental nurse the opportunity to self-evaluate, before being compared with the practice evaluation.

Differences can be explored and resolved, and then an action plan can be developed to determine future goals and aims. All details should be recorded

Areas of appraisal	Self-appraisal	Practice appraisal	Notes
Personal hygiene Dress Punctuality			
NHS procedures Rules/regulations Medico-legal knowledge			
Materials techniques Infection control Patient management X-ray procedures Equipment handling			
Courses of study Self-study Experiential learning Problem-based learning Peer group learning			
Teamwork experience Innovation Originality			
Communication skills Interpersonal skills Administrative accuracy Telephone manner Complaints handling			
APPRAISAL SUMMARY			
Signed Signed Date			

Fig. 15.1 Example appraisal sheet.

on the appraisal sheet and then copied so that both the nurse and the practice can refer back to it to assess the level of success of that appraisal.

The appraisal sheet should also serve as a record of the dental nurse's self-development and progression within the practice, and expose any areas which continue to cause problems in future appraisals.

The areas of appraisal can be adjusted to suit individual practices. The frequency of appraisal will also differ between practices as well as for different staff members. Younger, less experienced staff members are likely to require more frequent appraisal while learning all the relevant practice policies and protocols, and how to put them into practice. More experienced staff will need to be supportive and non-judgemental during this period.

Whenever possible, the dental nurse should attend courses to become aware of changes in dental technology, legislation reviews, clinical updates, and advances in materials science. Interesting courses are also run routinely on subjects such as patient management, violence in the workplace, improving communication skills, and others which help to promote a better working environment for all.

More formal study and further qualifications are available in several areas of dental practice for the dental nurse, including oral health education, dental sedation, orthodontics, special care dental nursing and dental radiography. Once qualified, the dental nurse can also progress to train as a hygienist or a dental therapist too. The dental nurse should join any relevant associations or societies to stay abreast of these career opportunities.

Career pathways are available for dental nurses to advance their experience and achievements as they wish, and it is likely that more options will be developed with time. Whatever pathway is taken, the dental nurse will remain a valuable, if not indispensable, member of the dental team, and well-qualified and experienced ones will continue to be lynchpins in the development of successful dental practices.



Activities

- ◆ Draw up two pages of a reflective log, and record your experiences for the first and the fifth times that you carried out a particular procedure. Compare the logs and discuss with your colleagues.
- ◆ If your practice does not have a staff appraisal system in place, try to develop one.

