

34. A 40-year-old female has been referred to you for a recent ER and hospital admission, from which she was given a diagnosis of acute diverticulitis. Treatment at that time consisted of antibiotics, bowel rest, and IV fluids. The patient reports to you that she has also recently been diagnosed with arthritis and takes ibuprofen three times a day. The patient also tells you that the left lower quadrant pain is improved but still present. The WBC today, 2 days after completion of the course of antibiotics she was given in the ER, is 9000. You've scheduled her for abdominal pelvic CT scan. Which of the following choices would be the most appropriate for performing an elective surgery for diverticulitis in this patient?

- A. A family history
- B. A second episode
- C. A continued low-grade leukocytosis
- D. Continued left lower quadrant abdominal pain
- E. Evidence of an abscess
- F. Hematemesis

35. A 19-year-old male presents to clinic with complaints of abdominal pain for the last 3 months. The patient states it is diffuse without any distinguishable inciting events. At times it is accompanied by a low-grade fever and multiple bouts of diarrhea. There are intervals without any of these symptoms. For the last week he states the pain has become more persistent and frequency of stools has increased. The patient takes ibuprofen for the pain and denies allergies to any medications, and he has never been hospitalized or undergone prior surgery. Vital signs are within normal limits. On physical exam, the patient is found to be thin and in no apparent distress. The abdomen is scaphoid and diffusely tender to palpation, but it is soft without any peritoneal signs. Routine laboratory values obtained are all normal. You suspect this patient has inflammatory bowel disease and schedule a colonoscopy for the following week. Which of the following, if present, is more characteristic of Crohn's disease?

- A. Pseudopolyps
- B. Mucosal and submucosal involvement only
- C. Small bowel strictures
- D. Confluent disease
- E. Rectal involvement
- F. Depletion of goblet cell mucin
- G. Granular, flat mucosa

36. A 27-year-old male comes to the ED with complaints of severe right lower quadrant abdominal and testicular pain that began 5 hours ago. The pain is the worst he has ever experienced and it is associated with nausea but not vomiting. The patient is writhing in pain and cannot seem to sit still while you are speaking with him. The patient is afebrile and has a WBC of 10,300, with no left shift. Which of the following is the correct choice of studies to obtain?

- A. Amylase and lipase
- B. Upper GI series
- C. HIDA scan
- D. Liver function tests
- E. Urinalysis

37. While on a general surgery service at the Veterans Administration Hospital you are consulted to see a 75-year-old male. The patient tells you that over the last 2 months he has become more fatigued and complains of dyspnea on exertion and often feels lightheaded during ambulation. The patient also claims to have lost 30 lbs unintentionally over the last 6 months. The cardiology team did a full workup on the patient and has effectively ruled out his heart as the likely source. During the cardiac workup, he was found to be anemic with a hematocrit of 30% at which time he underwent a colonoscopy by the GI team. A 4-cm villous polyp was found near the hepatic flexure. Regarding polyps found within the GI system, which type is associated with the greatest likelihood of carcinoma in situ or invasive cancer?

- A. Hamartomatous polyps
- B. Tubular polyps
- C. Tubulovillous polyps
- D. Villous polyps
- E. Juvenile polyps
- F. Inflammatory polyps

38. You are called to see an 80-year-old female in the ED. The patient was transferred by ground from a local nursing home. Presently, she is coherent and reports to you that she began vomiting approximately 10 hours ago and has vomited five times throughout the day. It has been thick and brown in appearance. The patient also is complaining of severe abdominal pain that started last evening and has progressively gotten worse. The patient also tells you that she has not had a bowel movement or had any flatus throughout the day. Medical-surgical history does not include any previous surgery, and 1 month ago she underwent a colonoscopy to evaluate a history of chronic constipation, which was reported as normal. Vital signs are BP 106/68, HR 77, and T 36.6°C. Labs are WBC of 13,300 and HCT of 36.8%. You suspect she may have a large bowel obstruction. What is the most likely cause of a large bowel obstruction in this 80-year-old female?

- A. Adhesions
- B. Ascending colon mass
- C. Sigmoid volvulus
- D. Diverticular stricture
- E. Intussusception
- F. Incarcerated inguinal hernia

39. A 72-year-old female with von Hippel-Lindau disease has been in the hospital for the last 3 days with dehydration from severe gastroenteritis. Over the last 6 months the patient has had a substantial weight loss of 35 lbs. The patient's urinalysis shows gross hematuria and her hematocrit is 27%. What is the likely cause of this patient's symptoms?

- A. Renal cell carcinoma
- B. Nephrolithiasis
- C. UTIs
- D. Bladder trauma
- E. Colon cancer

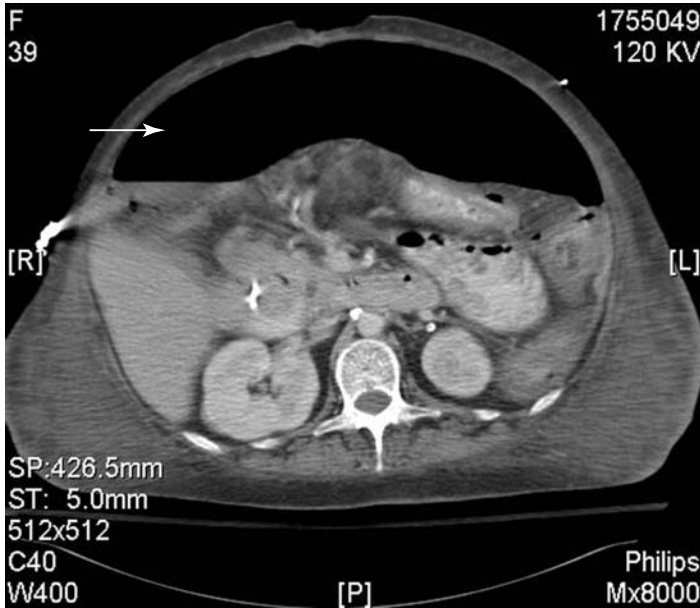


Figure 33B • Image courtesy of the University of Utah School of Medicine, Salt Lake City, Utah.

C. If this was a contained perforation into an abscess, IV antibiotics and percutaneous drainage would be an option. Free air in the abdomen necessitates an emergent surgical exploration.

E. A primary anastomosis is performed only in a controlled operation in which there has been time to undergo an appropriate bowel prep. This usually occurs after medical management of a perforated diverticulum with antibiotics and placement of a percutaneous drain if an abscess exists. A primary anastomosis should not be performed in the face of gross contamination because of the high likelihood of an anastomotic leak.

34. B. Patients diagnosed with diverticulitis at a young age are likely to have subsequent attacks and suffer complications from them. It would be considered appropriate to electively operate on a young person with a second episode of diverticulitis. Other relative indications for elective surgery include the inability to exclude colon carcinoma endoscopically, and two or more attacks of diverticulitis due to an increased risk of complications.

A. A family history would not be an indication for elective surgery.

C. A continued low-grade leukocytosis should be evaluated, since this could be the failure of nonoperative therapy and require urgent surgery, or it could be unrelated to the diverticulitis.

D. Continued pain should be evaluated further, since it may also be a result of failure of nonoperative therapy requiring urgent rather than elective surgery.

E. An abscess is an absolute indication for percutaneous drainage or surgery.

F. Hematemesis is not related to diverticulitis and may indicate an upper GI process, which should be evaluated and treated.

35. C. Crohn's disease is a form of inflammatory bowel disease that is associated with transmural inflammation in a segmental fashion along any part of the GI tract. Due to the transmural inflammation associated with Crohn's disease, the development of small bowel strictures leading to obstructive symptoms is common. Figure 35 is a small bowel contrast study with an obvious stricture (note arrow) due to Crohn's disease.

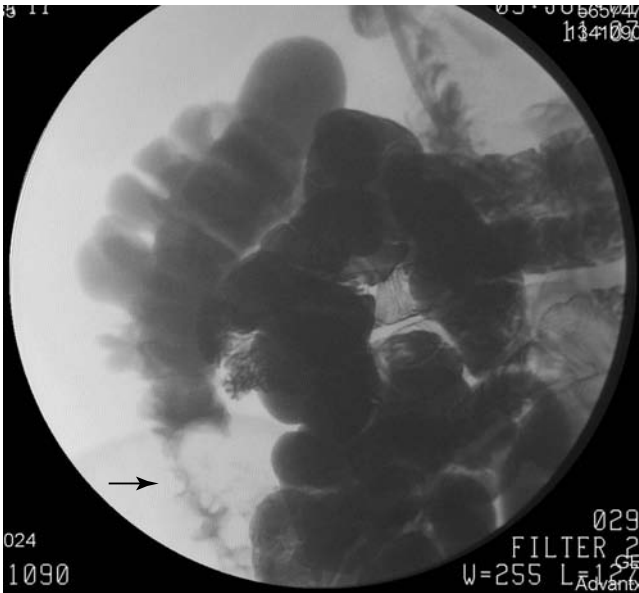


Figure 35 • Image courtesy of the University of Utah School of Medicine, Salt Lake City, Utah.

A, B, D, E, F, G. Pseudopolyps, mucosal and submucosal involvement, confluent disease, rectal involvement, depletion of goblet cell mucin, and granular flat mucosa are all seen in inflammatory bowel disease and are all characteristics of ulcerative colitis. Complications seen with Crohn's disease include bowel obstruction, abscess formation, fistula formation, anorectal lesions, and an increased risk of carcinoma, but less than that of ulcerative colitis.

36. E. Although this patient presents with a story that is concerning for appendicitis, he does not exhibit the classic peritoneal signs. A patient with peritonitis is unlikely to “writhe in pain,” as any movement exacerbates the peritoneal irritation. A patient with a kidney stone classically has difficulty getting comfortable, and frequently will be found twisting and turning, as in agony, in bed. Management of a kidney stone is typically nonoperative, and obtaining a urinalysis is routine for all patients who present with right lower quadrant pain.
- A. An amylase and lipase would be helpful only if you suspected pancreatitis, which typically presents as midepigastric pain radiating to the back.
- B. An upper GI would not be helpful in this scenario, since the pain is clearly located distally from the upper GI tract.
- C, D. LFTs and a HIDA scan are helpful in diagnosing hepatobiliary causes of abdominal pain, which usually presents as pain in the right upper quadrant.
37. D. Adenomatous polyps are divided into tubular, villous, and tubulovillous types. Villous polyps account for 10% of all polyps, with a 25% incidence of carcinoma. The risk of carcinoma increases for all subtypes with increasing polyp size.
- A. Hamartomas are found in adults, and have no malignant potential. They are associated with Peutz-Jeghers syndrome.
- B. Tubular polyps are the most common (65%) and have the lowest incidence of malignancy (10%).
- C. Tubulovillous polyps account for 20% of polyps and 20% harbor malignancy.
- E. Juvenile polyps have no malignant potential and are most commonly hamartomas.
- F. Inflammatory polyps are often seen in inflammatory bowel disease.
38. C. This elderly, chronically constipated woman is the classic presentation of a patient with a sigmoid volvulus, and the contrast study shown demonstrates the classically described “bird’s beak” sign at the retrosigmoid junction (note the arrow in Figure 38). Large bowel obstructions account for only 15% of intestinal obstructions. They are most commonly caused by colorectal cancer (60%) or diverticulitis (20%), neither of which was noted on previous colonoscopy. Volvulus (10%) and miscellaneous causes (10%) make up the remainder of causes for colonic obstruction. Complete large bowel obstruction is considered a surgical emergency, as it is a closed loop obstruction with a functional ileocecal valve with the risk for bowel ischemia and necrosis.
- A. Adhesions are by far the most common cause of a small bowel obstruction in someone with previous abdominal surgery. They are significantly less likely to be the cause of a colonic obstruction.
- B. As in the explanation for C, colorectal cancer is the most common cause of a colonic obstruction, and since the colonoscopy 1 month prior was normal, an obstructing mass would be extremely unlikely.

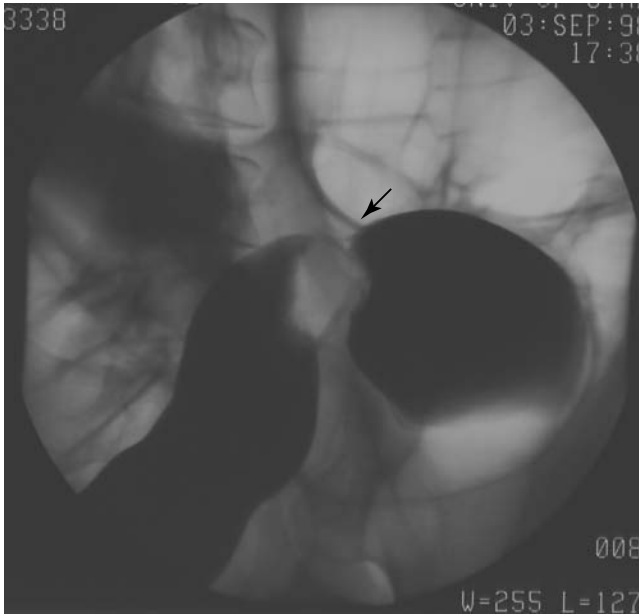


Figure 38 • Image courtesy of the University of Utah School of Medicine, Salt Lake City, Utah.

D. A diverticular stricture is a complication of diverticulitis, and likewise, would have been seen at the time of colonoscopy.

E. Intussusception is a common cause of colonic obstruction, but is less frequently seen than volvulus.

F. An incarcerated inguinal hernia is a common cause of a small bowel obstruction. It is very unlikely this would cause a large bowel obstruction.

39. A. In a patient with hematuria, weight loss, and anemia, one must be very concerned about renal cell carcinoma. The abdominal CT in Figure 39 shows a left renal cell cancer (note the arrow). Ninety percent of solid renal tumors are renal cell carcinomas. Other presenting symptoms include pain, presence of a flank mass, and hypertension. Renal cell carcinoma is found in conjunction with von Hippel-Lindau disease linked to chromosome 3.

B, C, D. Although nephrolithiasis, UTIs, and bladder trauma can cause hematuria, they would not account for the substantial weight loss and significant anemia.

E. Colon cancer is usually not associated with hematuria unless a fistula has developed from an advanced tumor.