

Gingival Hyperplasia



DEFINITION AND OVERVIEW

Gingival hyperplasia (GH) is an increase in gingival height and/or mass due to proliferation and thickening.



ETIOLOGY AND PATHOPHYSIOLOGY

- Occurs in dogs and cats
- Familial or breed tendency probable (especially boxers)
- Hyperplastic response of gingival epithelial cells to likely due to chronic antigenic stimulation of periodontal components
- Sometimes seen as a sequela to certain medications, such as diphenylhydantoin, cyclosporine, nitrendipine, nifedipine



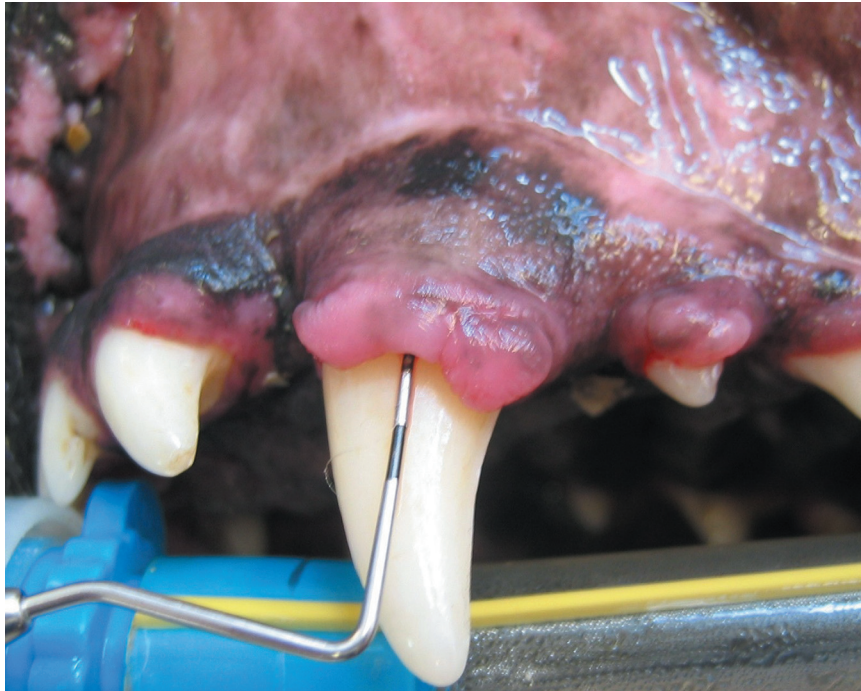
SIGNALMENT AND HISTORY

- High predilection in certain dog breeds: boxers, Great Danes, collies, Doberman pinschers, Dalmatians
- Gradual thickening and elongation of gingival margins
- May have oral odor (see Chapter 21, Halitosis)

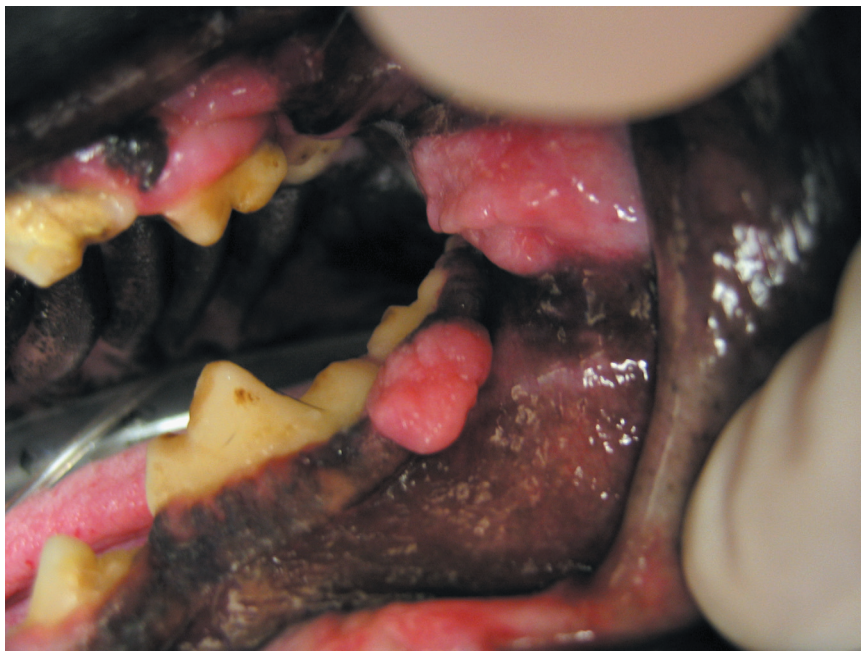


CLINICAL FEATURES

- Thickening and increase in height of attached gingiva and gingival margin, sometimes completely covering tooth surface
- Resultant formation of *pseudopockets*—increase in pocket depth due to increased gingival height, not due to loss of attachment, unless untreated and progresses to concurrent periodontal disease (see Figure 24.1)
- Possible symmetrical enlargement of gingival margin, especially at incisors
- Possible locally affected areas (e.g., in shelties), but typically more generalized pattern
- Possible development of hyperplastic areas in locally affected areas other than the marginal gingiva due to chronic irritation, such as “gum chewers” lesion (see Figure 24.2)



■ **Fig. 24-1** Gingival hyperplasia is an overgrowth of the gingival margin that causes a deeper pocket, not due to attachment loss (pseudopocket).



■ **Fig. 24-2** While not true gingival hyperplasia, local irritations such as with "gum chewers" syndrome of the buccal or lingual mucosa can present with similar signs and need for evaluation for therapy and/or biopsy.

- Possible formation as protuberant mass (grape cluster) at gingival margin; biopsy necessary to rule out neoplasia



DIFFERENTIAL DIAGNOSIS

- Oral Neoplasia: epulis, etc. (see Chapter 34, Epulis)
 - Usually not generalized; sometimes osseous changes present
- Oral papillomatosis (see Chapter 42, Papillomatosis [Oral])
 - Papilloma usually on mucosa surfaces
- Operculum (see Chapter 12, Eruption Disruption and Abnormalities)
 - Seen in young animals during eruption phase of teeth, incomplete loss of gingival tissue covering erupting tooth



DIAGNOSTICS

- Presumptive diagnosis is based on clinical appearance, especially if generalized and found in a breed with a high predilection.
- Focal areas or areas that do not respond to standard therapy should be biopsied. Histological evaluation is the only way to confirm.
- Perform appropriate preoperative diagnostics when indicated prior to procedure.



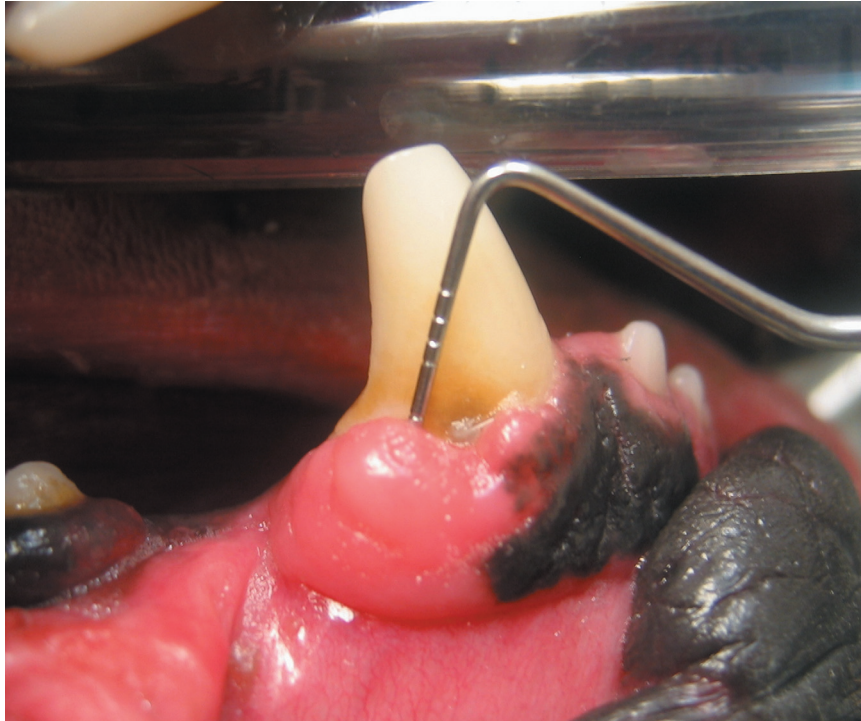
THERAPEUTICS

Drugs

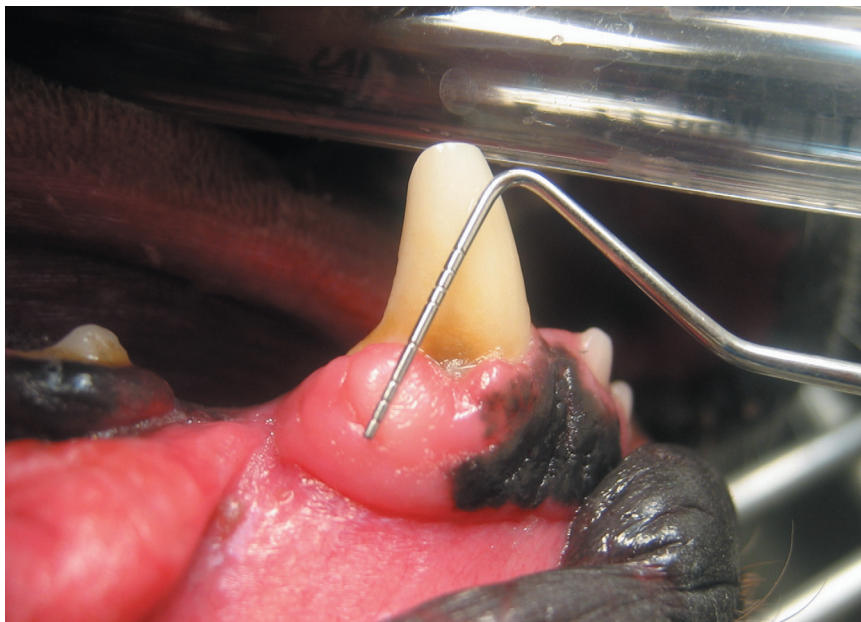
- Oral antimicrobials (chlorhexidine; zinc ascorbate gel)
- Postoperative pain management

Procedures

- Appropriate patient monitoring and support during anesthetic procedures
- Gingivoplasty (GVP), or recontouring, to remove excess gingival tissue and return pocket depths to normal
 - Administer local anesthetic injections and/or topical gels.
 - Insert a periodontal probe to determine the depth of the pseudopocket, and then place the probe on the outside of the pocket and insert the probe into the gingiva at that point, marking the *bleeding point*, or extent of the defect (see Figures 24.3a, 24.3b).
 - Excise excess tissue and reshape the gingival margin. This time-consuming process requires patience. Hemostatic solutions may be used to aid in hemorrhage control as needed. Several different excision tools may be used.
 - Cold steel such as sharp, stout scissors or scalpel blade: Connect the dots (made earlier by the probe) with the blade to approximate the normal



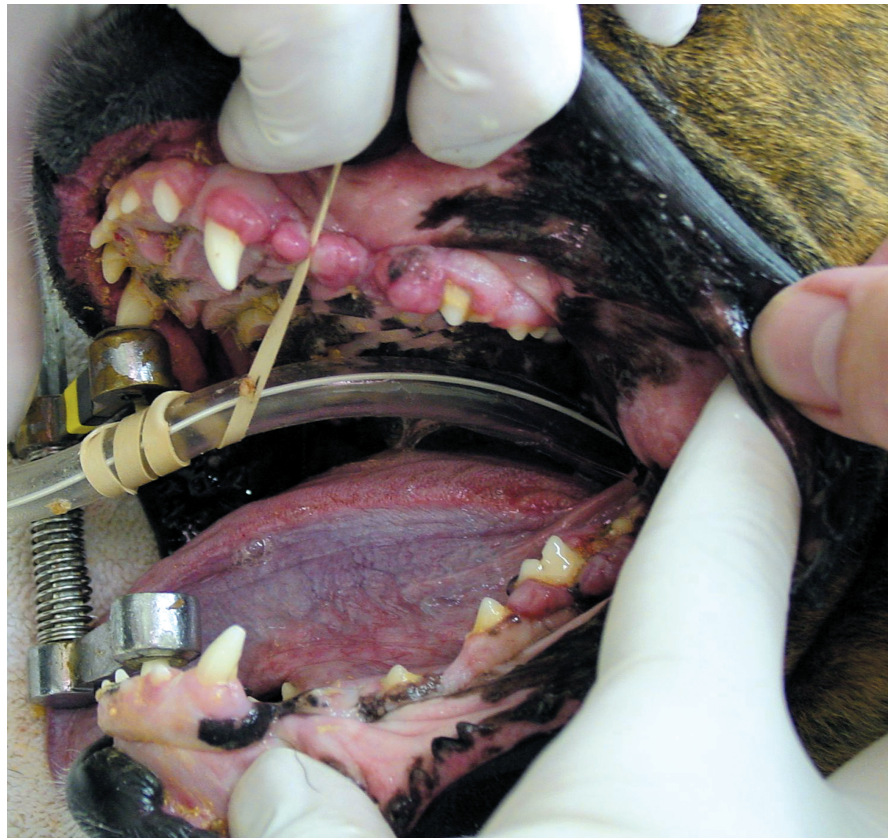■ **Fig. 24-3a** Measure the depth of the pseudopocket with the periodontal probe.



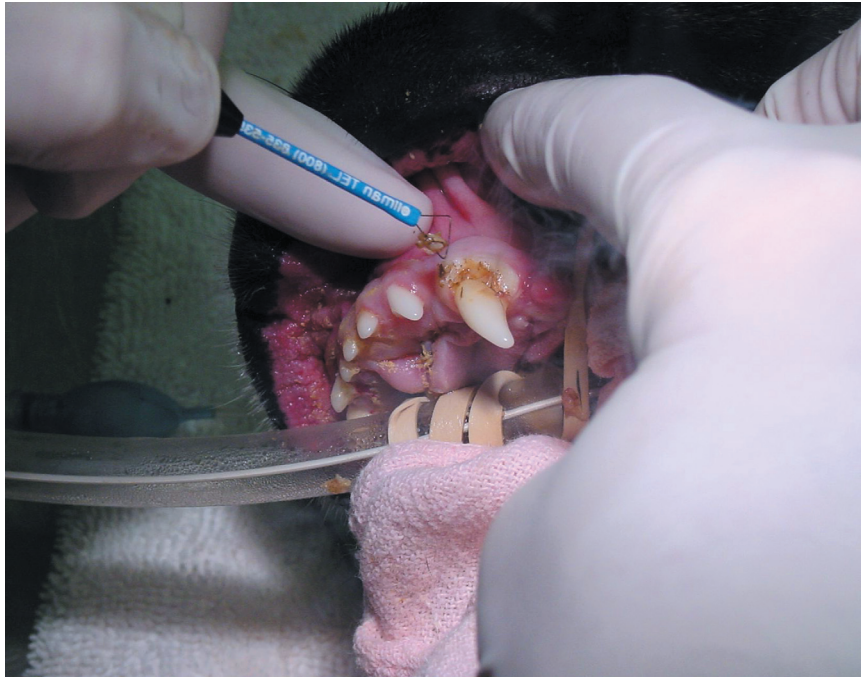■ **Fig. 24-3b** Place the probe at the same level on the outside of the pocket and insert the probe tip into the gingiva at that point, marking the extent of the defect (bleeding point).

gingival margin or use scissors following the pocket depth to remove bulk tissue.

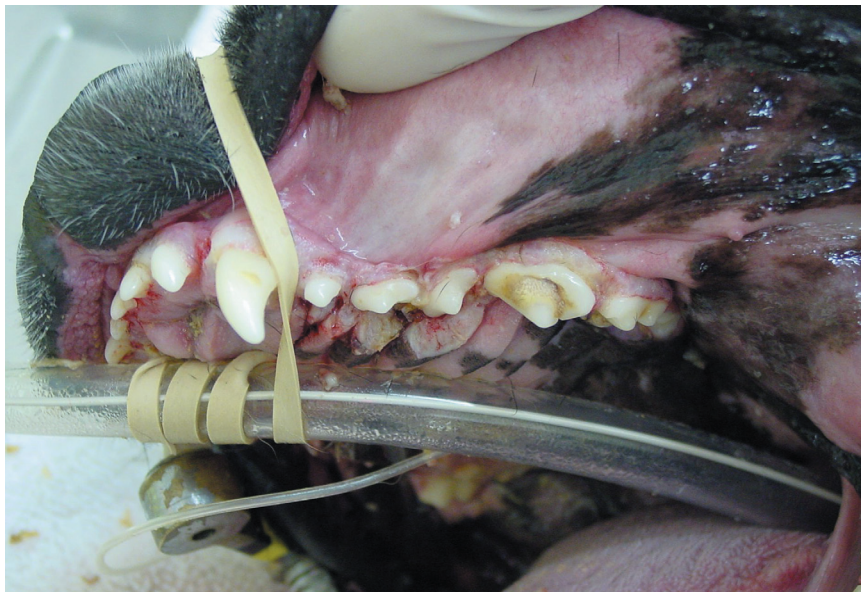- 12-fluted bur on high-speed handpiece: Contour the margin to a feather angle, which assists in hemostasis.
- Radiosurgery: Use fully or partially rectified current, taking care not to damage underlying bone or tissue (see Figures 24.4a, 24.4b, 24.4c).
- Reduce excessive thickness in the incisor and canine region using a modified Widman technique.
 - Create an envelope flap to lift gingiva off tooth surfaces.
 - Excise a tissue wedge to remove gingiva at the inside of the pocket to provide a narrower width of attached gingiva.
 - Suture interdentally to secure gingiva.
 - Use digital pressure to reposition.
- Use a dropper containing tincture of myrrh and benzoin to coat the cut margins and allow it to dry. Apply four or five layers of the tincture.
- Follow-up treatment and regular dental cleaning as needed



■ Fig. 24-4a Patient with generalized gingival hyperplasia.



■ Fig. 24-4b Electrocautery unit used for gingivoplasty.



■ Fig. 24-4c Postoperative appearance after gingivoplasty.



COMMENTS

- Gingival hyperplasia is a chronic, recurring problem that often needs repeated therapy.
- Regular dental cleanings and home care (daily brushing) will minimize the effects of plaque and bacterial accumulation.

Expected Course and Prognosis

- Good prognosis with regular care
- Recurrence common

Abbreviations:

- GH: gingival hyperplasia/hypertrophy
- GV: gingivectomy (actually means “surgical removal of gingiva”)
- GVP: gingivoplasty

Suggested Reading

Lobprise, H. B., and R. B. Wiggs. *A Veterinarian's Companion to Common Dental Procedures*. Lakewood, CO: AAHA Press, 2000.

Wiggs, B. W., and H. B. Lobprise. *Veterinary Dentistry: Principles and Practice*. Philadelphia: Lippincott-Raven, 1997.

Author: Heidi B. Lobprise, DVM, Dipl AVDC

Consulting Editor: Heidi B. Lobprise, DVM, Dipl AVDC