

PART 1

Tricks of the trade

To many implanters, the adult patient with congenital heart disease conjures up a frightening surgical scenario. Although the implanting physician may be familiar during the training years with the array of congenital defects, such familiarity becomes clouded and obscure as years progress. Irrespective of how familiar the cardiac defect is to the implanting physician, once consideration is given as to how a lead will progress through the venous channels to the heart and then be positioned in the atrium or ventricle, a degree of uncertainty and fear emerges. In addition, it must be remembered, that a “repaired” congenital heart defect may not be synonymous with a “normal” heart. The post-operative anatomy may introduce many technical challenges to the implanting physician, attempting a pacemaker or ICD implant.

Consequently, as any pediatric cardiologist recognizes, a pacemaker or ICD implantation in a child with congenital heart disease requires special consideration and the procedure cannot be regarded as routine. Such special consideration must obviously be extrapolated to the adult scenario, where the implanting physician is usually less familiar with the anatomy than the pediatric counterpart. It is the objective of this part to outline the various principles required, when preparing for an implant in an adult patient with congenital heart disease. Most implanters will be familiar with a number of these general principles in regard to routine implants. However, they become more important in hearts with congenital abnormalities or obstructive post-operative scarring and are worth reviewing in detail. The authors will discuss the management of these potential problems and advise on the array of hardware options available. It is hoped that these principles will also be helpful for all implants.

CHAPTER 1

Know the anatomy

Prior to pacemaker or ICD implantation, a full understanding of the cardiovascular anatomy of the adult with congenital heart disease is critical.

- Can a lead be placed in a venous atrium or ventricle which leads to the pulmonary circulation?
- What are the fluoroscopic appearances and do they differ from the normal?
- Are the vascular pathways to the heart intact and otherwise normal?

Throughout this text, simple line diagrams will be used to explain the congenital abnormalities of the heart. These diagrams will in turn be compared to fluoroscopic or chest radiographic images with implanted leads. This will enable the reader to quickly grasp the anatomical variations to be found at surgery. The schematic diagram of a normal heart is shown in Figure 1.1.

In many instances, a pre-operative transthoracic or transesophageal echocardiogram, venogram, computerized tomographic scan or magnetic resonance imaging study will be necessary to define structures. A review of a relevant cardiac catheterization or surgical report may reveal an absent or obstructed superior vena cava or an innominate vein. The coronary sinus may not drain directly into the right atrium and with an Ebstein's anomaly of the tricuspid valve, the surgeon, in order to prevent heart block, may position the prosthetic tricuspid valve, so that the coronary sinus lies on the ventricular side of the valve. A few minutes spent, carefully checking the anatomy may save hours of anguish at the time of device implant.

Another potential troublesome abnormality in a patient is an interrupted inferior vena cava. In this situation, the right atrium receives only hepatic venous blood from below. The infrahepatic portion of the inferior vena cava is absent or rudimentary. Blood flow from the inferior vena cava to right atrium must reroute to a right or left superior vena cava via a right or

4 Chapter 1

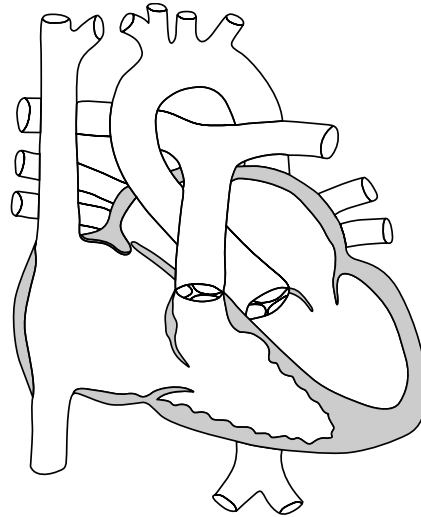


Figure 1.1 Schematic of a normal heart.

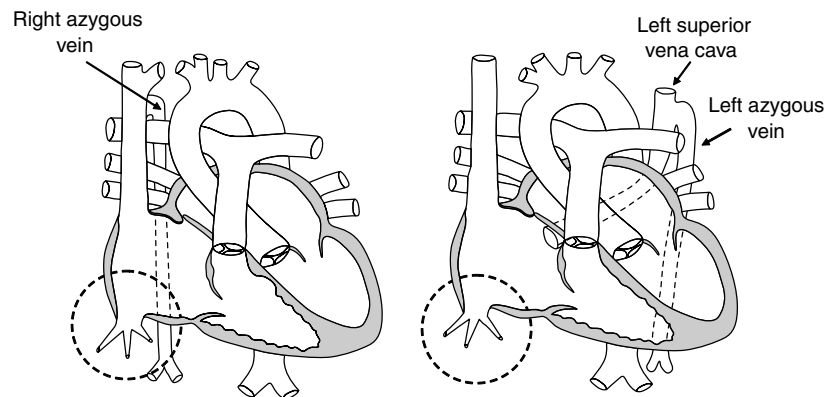


Figure 1.2 Schematic appearance of variations of systemic venous return associated with interruption of the inferior vena cava. *Left:* A right azygous vein drains blood from the lower trunk into the superior vena cava. *Right:* A left azygous (hemiazygous) vein drains blood from the lower trunk into a left superior vena cava and from there into the right atrium via the coronary sinus.

left-sided azygous vein (Figure 1.2). Knowledge of this anatomical variant is important for anyone contemplating preoperative temporary pacing from a femoral vein site, lead extraction or any cardiac catheterization procedure. It will also be important to recognise if the superior pacing lead follows a strange course away from a right or left superior vena cava.

To the adult pacemaker and ICD implanter, many of the complex and even simple congenital cardiac anatomical abnormalities become very confusing; when transvenous leads need to be positioned in the atrium or ventricle. Many implanters have never considered such scenarios or have not encountered them for many years and consequently cannot envisage the anatomical pathways. A patient with congenital atrioventricular block or long QT interval without other anatomical abnormalities is considered a normal implant. However, congenitally corrected L-transposition of the great vessels, dextrocardia or maybe Ebstein's anomaly, although technically similar to the normal implant, may present implant challenges which can be easily overcome by a review of the anatomy. In other situations, such as surgically corrected D-transposition of the great vessels or persistent left superior vena cava, the anatomical challenges can be formidable to the uninitiated.