

# Adult polycystic kidney disease at a glance

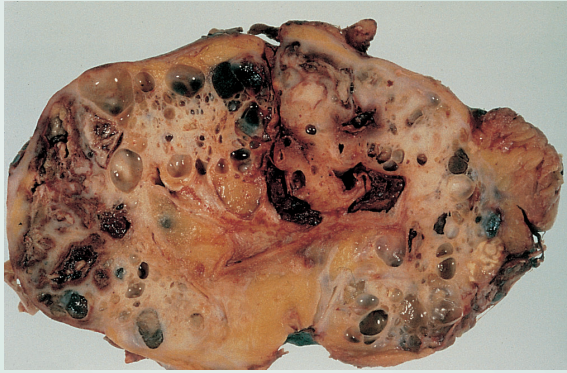

Fig. A A polycystic kidney. There are multiple cysts of different sizes, some filled with blood.

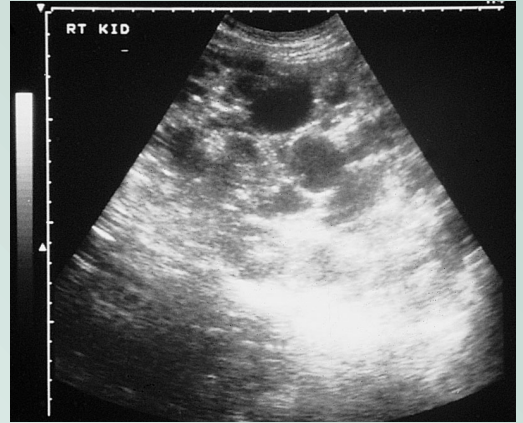


Fig. B Ultrasound of a polycystic kidney. Cysts of different sizes are scattered throughout the kidney substance and can be seen as round black shapes.

